

Basic Urology

History Taking and Physical Examination

Editor

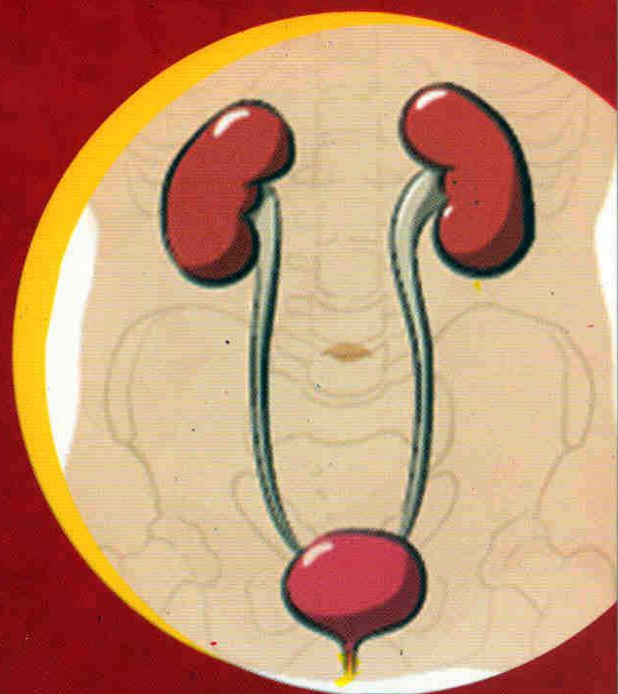
Atallah Ahmed Shaaban

Professor of Urology

Faculty of Medicine

Urology and Nephrology Center

Mansoura- Egypt



Basic Urology

History Taking

and Physical Examination

Atallah Ahmed Shaaban
Professor of Urology
Faculty of Medicine
Urology and Nephrology Center
Mansoura- Egypt

بسم الله الرحمن الرحيم

Preface and Dedication

The first edition of "*Basic Urology: History Taking and Physical Examination*" reflects a collection of some notes of information during the development of the editor as a urologist. I have tried to concisely summarize the data as simple as possible. The ultimate teachers through the cruise of medical knowledge are always the patients. For all friends who read this book, I would be grateful to have advices, suggestions and possible help for a future edition. I am particularly grateful for all staff at Faculty of Medicine and Urology Department in Mansoura University for their support.

I wish to thank Mrs. Hala Fatehy for her diligent preparation of this handbook and Mr. Fetoh Ateyia for the illustrations.

This work is lovely dedicated to all with intention to be urologists. All are kindly requested to devote themselves to the service of our patients.

Atallah Ahmed Shaaban

Urology and Nephrology Center

Mansoura, Egypt 2011

E-mail: shaaban1953@yahoo.com

List of Contents

	Page
History taking	1
Personal history	1
Complaints	1
History of present illness	2
Past history	2
Family history	7
Systematic review	8
Urologic symptoms	9
Pain	9
Voiding function and dysfunction	12
Changes in the gross appearance of urine	21
Swelling	24
Urethral discharge	25
Symptoms of chronic renal failure	25
Abnormal appearance and/or function of the male external genitalia	26
Indirect urologic symptoms	28
Acute renal failure: Oliguria and anuria	31
Urine Retention	36
Hematuria	40
General examination	44
The face	44
The neck	46
Vital signs	48
Edema	51
Lymph nodes	53
Chest and heart	56
Abdominal examination	58
Inspection	60

Auscultation	66
Palpation	67
Percussion	72
Clinical features of a urologic mass	74
Examination of the back and spine	78
Examination of the testis and scrotum	80
The scrotum	80
Testis	81
Hydrocele	90
Epididymis	91
Spermatic cord	93
Examination of penis and perineum	98
Anorectal Examination	106
1. Positioning the patient	106
2. Inspection of the anal verge:	108
3. Finger introduction:	108
4. The anal canal:	109
5. The prostatic zone:	110
6. The supra-prostatic zone:	115
7. Bimanual examination:	116
8. Bidigital examination:	118
9. Withdrawn finger inspection:	119
10. Cleaning:	119
11. Thank the patient.	119
Vaginal Examination	120

List of tables

	Page
Table (1)	International Prostate Symptom Score
Table (2)	Physical characters of urine
Table (3)	Common causes of colorful urine:
Table (4)	Differential diagnosis of acute retention and obstructive anuria
Table (5)	Differentiation between acute and chronic urine retention.
Table (6)	Important chest problems in urologic practice
Table (7)	Inguinal hernias
Table (8)	Differentiating splenomegally and an enlarged left kidney
Table (9)	Differential diagnosis of acute scrotal swelling
Table (10)	Comparison of primary and secondary varicocele
Table (11)	Findings in testis and scrotum in urologic disorders
Table (12)	Ulcers of the Penis
Table (13)	Types of priapism
Table (14)	Features of urethral injuries
Table (15)	Features of prostate by DRE in health and disease

List of figures

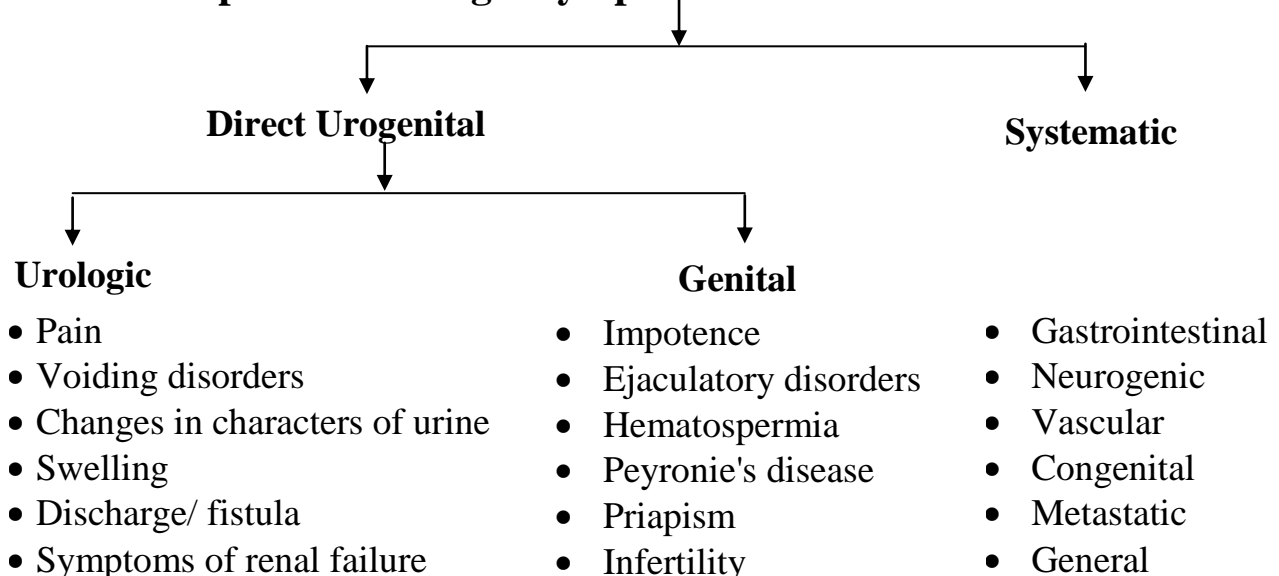
	Page
Fig. (1): Classification of mechanisms of injury in urologic practice	7
Fig. (2): Location and radiation of renal pain	9
Fig. (3): Post-micturition dribbling due to the presence of small amount of residual urine in the bulbar urethra.	14
Fig. (4): Classification of causes of nocturia	18
Fig. (5): Causes of intrinsic acute renal failure	33
Fig. (6): Division of the abdomen into 5 areas	59
Fig. (7): Division of the abdomen into 9 areas	59
Fig. (8): Bimanual palpation of a right renal mass.	70
Fig. (9): Division of the back into 5 areas	78
Fig. (10): Examination of the testis	81
Fig. (11): Potential sites of incompletely descended testis	83
Fig. (12): The chair test	83
Fig. (13): Potential sites of ectopic testis	84
Fig. (14): Examination of the opposite testis in testicular torsion showing a transverse lie and a long meso-orchium	85
Fig. (15): Types of hydrocele	90
Fig. (16): Steps of anorectal examination in the male.	107
Fig. (17): Anorectal examination in patients with prostate cancer.	112
Fig. (18): Differential diagnosis of prostatic nodule	113
Fig. (19): Digital rectal examination of the prostatic zone.	114
Fig. (20): Bimanual examination in patients with bladder cancer	117
Fig. (21): Bimanual palpation of a bladder mass in the male.	118
Fig. (22): Bidigital anorectal examination to assess Cowper's gland enlargement.	119

History Taking

I- Personal History:

- Name
- Age is a guide to the nature of urologic diseases.
- Sex is relevant to certain disorders.
- Residence (past & present).
- Occupation (past & present).
- Education
- Marital status.
 - Married?
 - Do they have children?
 - Are they healthy?
- Special habits to identify risk factors for particular diseases, respect privacy.
 - a. Smoking: The most important risk factor in bladder cancer.
 - Past & present.
 - Active: quantify: 1 pack-year is 20 cigarettes per day for one year.
 - Passive.
 - b. Alcohol
 - c. Opium.
 - d. Drug abuse is risk for HIV and hepatitis.
- Overseas travel
- Living conditions.

II- Complaints: Urologic Symptoms



III- History of Present Illness:

- The reason for presenting to the urologist is the chief complaint.
- Put the important positives first, and include the relevant negatives e.g. no haematuria.
- Symptoms are arranged in a chronological sequence. Renal colic followed by hematuria is suggestive of stones while hematuria followed by colic may result from a tumor.
- Details of the current symptoms (OLD CARTS):
 - Onset: date it began?, sudden or gradual, over how long?
 - Location and radiation.
 - Duration.
 - Characters: nature of the symptom.
 - Aggravating factors.
 - Relieving factors.
 - Timing: improving or deteriorating with time.
 - Severity.
- Details of previous similar episodes.
- Details of investigations and treatment for the current problem.
- Extent of functional disability.
- Menstrual and reproductive history for women.

IV- Past History: (Medical, Surgical, Trauma).**1- Past Medical History(ABCs):**

Asking the patient: have you ever had any medical problem, or been to hospital for anything?

Allergies and Reactions:

- Any adverse reactions to medications and contrast media?
- Anaphylaxis is a life-threatening reaction and an absolute contraindication to re-exposure.
- All medical allergies should be marked boldly on the front of patient's chart.

Bilharziasis

- History of exposure.
- Pre-localization: swimmer's itch with fever.
- Localization: simple bilharzial cystitis (mild frequency and suprapubic pain, terminal drop hematuria).
- Diagnosis.
- Treatment: type and response.
- Complications

Calculi:

- Renal colic.
- Passage of stones.
- Treatment.
- Causes of stone formation.
 - Hereditary disorders: RTA, cystinuria.
 - Dietary excess of oxalates, purines, calcium.
 - UTIs.
 - Dehydration.
 - Gout.
 - Hyper-calcemic disorders e.g.
 - Hyper-parathyroidism, immobilization.

Drug-induced urologic symptoms:***Hematuria:***

Anticoagulants
Cyclophosphamide, Ifosfamide.

Obstructive LUTS and acute urine retention:

Antimuscarinic drugs:

- Oxybutynin HCL
- Flavoxate HCL
- Propantheline Bromide
- Tolterodine tartrate

Anxiolytics: Diazepam

Calcium-channel blockers: Nifedipine (adalat)

Antiparkinsonian drugs: Levodopa and carbidopa.

α - Adrenergic agonists: Pseudoephedrine, phenylephrine.

Antihistamines: Loratadine, Diphenhydramine.

Oliguria and Acute Renal Failure:

Antimicrobials: Aminoglycosides.

Non-Steroidal Anti-Inflammatory Drugs (NSAIDs).

Radiocontrast agents

Angiotensin-Converting Enzyme Inhibitors.

Cyclosporine.

Chemotherapeutics: Cisplatin.

Impotence:

Antihypertensives

Psychotropic drugs

Ejaculatory disorders:

α – Adrenergic blockers

Psychotropic drugs

Priapism:

Antipsychotics

Antidepressants

Antihypertensives

Infertility: Impaired spermatogenesis

Chemotherapeutic drugs

Antiandrogens

Drug Abuse (Marijuana, Alcohol, Nicotine)

Endocrine diseases:

Diabetes mellitus frequently results in neurologic dysfunction that may lead to impaired urinary and sexual functions. Note:

- Type.
- Duration.
- Complications.

Primary hyperparathyroidism: abdominal groans, psychic moans, cystic bones, kidney stones and fatigue overtones.

Adrenal disorders: Cushing syndrome, hyper-aldosteronism, congenital adrenal hyperplasia, adrenal insufficiency, pheochromocytoma.

Male sexual development:

Normal development:

- 1- Chromosomal sex: 46XY
- 2- Gonadal sex: Two testes
- 3- Phenotypic differentiation: Secondary sex characters.
- 4- Gender assignment: Rearing as a male.
- 5- Gender identity: Psychological sex is a reaction to social factors.

Abnormal development:

- 1- Undescended testis.
- 2- Micropenis.
- 3- Gynecomastia.
- 4- Delayed puberty.
- 5- Precocious puberty.

Reproductive disorders in adults:

- 1- Hypogonadism
- 2- Impotence.
- 3- Infertility.
- 4- Gynecomastia.

Fever:

- Chills.
- Rigors are uncontrollable shaking or shivering followed by excessive sweating that follows a rapid increase in body temperature (characteristic of acute pyelonephritis).
- Onset, duration, recurrences.
- Relation to urologic symptoms.
- Relation to pyuria: drainage of an abscess into the urinary tract leads to pyuria and fever diminishes.
- Associated symptoms (neurological, gastrointestinal,.....).
- Fever of urologic origin: (see later)

Genital infections:

- Urethral discharge, gonococcal infections.
- Mumps may be complicated by orchitis.

Hypertension: may cause renal impairment and it may be a complication of a renal disorder. Endocrine hypertension is important. Hypertension and its medications may result in sexual dysfunction.

Infections of specific etiology: T.B. may cause:

- Unexplained chronic UTIs.
- Ureteral strictures.
- Renal impairment.
- Contracted bladder.

2- Past surgical History:

- Was the patient ever operated on?
- When?: list and date all previous operations.
- The name of the operation or why it was performed?
- Were there any complications?
- Problems with anesthesia?

A. Open surgery.

B. Endoscopy, urethral instrumentation, catheterization, dilatation may cause UTIs, epididymo-orchitis or urethral stricture.

3- Trauma:

- Trauma to the urinary tract usually gives a time for diagnostic procedures and decision making. Poor management may result in a greater damage than the untreated primary injury.
- The mechanisms of trauma include the followings (Fig. 1):
 - Blunt trauma e.g. road traffic accidents:
 - Crushing/entrapment e.g. in straddle injury, the bulbar urethra is crushed between the hitting force and pubic bone.

- Deceleration e.g. in motor vehicle accidents when deceleration occurs, the victim's body is thrown against the interior of the vehicle which had lost its movement. Acceleration, on the other hand occurs when a pedestrian is struck by a fast-moving vehicle.
- Penetrating injuries are either stab or missile wounds.
- Iatrogenic injuries are common in urologic practice.
- Indirect trauma is also important e.g. injury of the liver causing hemorrhagic shock may result in acute renal failure.

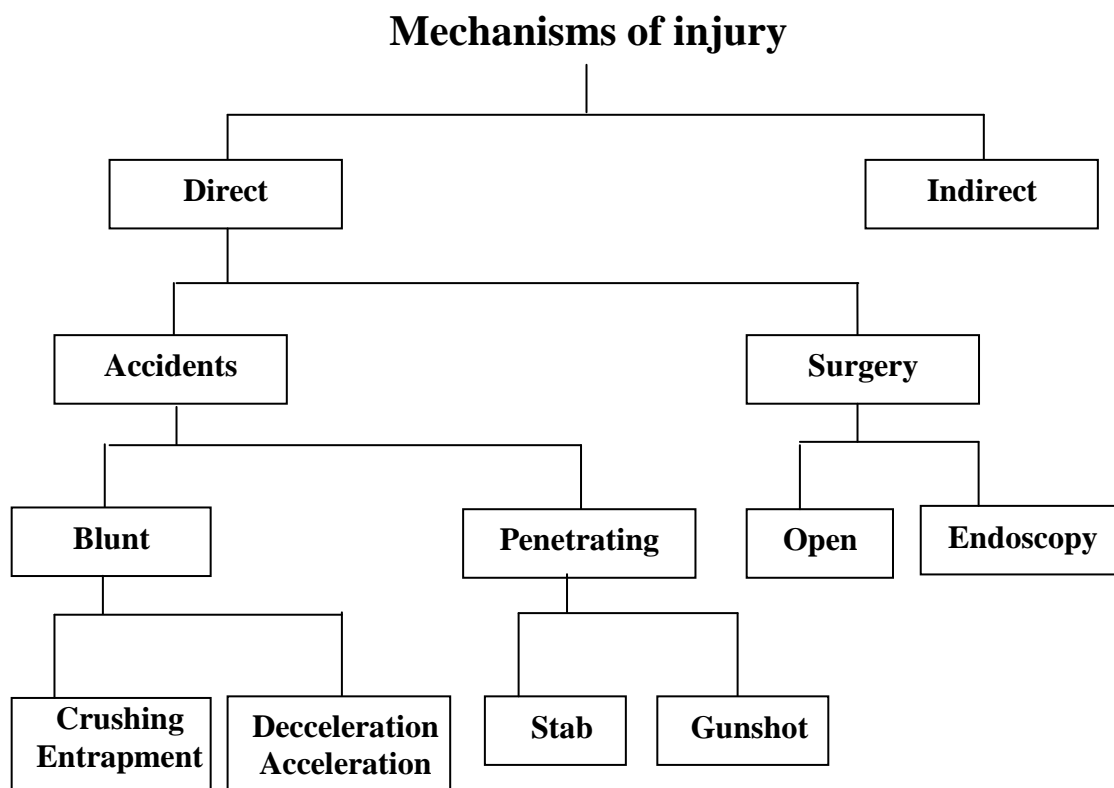


Fig. (1): Classification of mechanisms of injury in urologic practice

V- Family History:

- Are there any diseases that run in your family?
- Genetic diseases of urologic importance:
 - Polycystic kidney disease.
 - Tuberous sclerosis.
 - Von Hippel-Lindau disease.

- Renal tubular acidosis (RTA).
- Cystinuria.
- Alport's syndrome is a hereditary form of nephritis causing deafness and renal impairment.
- Diabetes and hypertension are common familial diseases but not due to a single gene disorder.
- Environmental risk: If a woman's husband died of lung cancer, she will be a passive smoker.
- Ask about parents and close relatives (living with diseases, causes of death).
- 10% of prostate cancer patients have a familial form with earlier onset.

VI- Systematic Review

History should include the relevant systems enquiry.

- a) General: changes in weight, appetite, temperature.
- b) Respiratory: cough, sputum, hemoptysis, shortness of breath, wheezes, chest pain.
- c) Cardiovascular: dyspnea, chest pain, palpitations, ankle swelling, orthopnea.
- d) Gastrointestinal: abdominal pain, nausea, vomiting, constipation, diarrhea, PR blood loss.
- e) Neurological: headache, dizziness, weakness, tremor, fits, faints, sphincter disturbances.
- f) Others: locomotor, cutaneous.

Urologic Symptoms

I. Pain:

Pain within the genitourinary tract usually arises from obstruction or inflammation. Referred pain is common. Inflammation of parenchyma produces severe pain and fever e.g. acute pyelonephritis, prostatitis and epididymo-orchitis. Tumors usually do not cause pain unless they produce obstruction or extend to adjacent nerves.

1- Renal pain:

- It results from obstruction of urine flow with distension of the capsule or the collecting system.
- Pain due to inflammation is dull aching.
- It is felt in the posterior renal (costo-vertebral) angle, below the last rib and lateral to the sacrospinalis.
- Pain radiates from the loin to the groin and ipsilateral testis or labium (Fig. 2).
- It is associated with gastrointestinal symptoms: nausea, vomiting and distension.
- Differential diagnosis: **Radicular pain:**
 - It results from irritation of costal nerves most commonly T₁₀-T₁₂.
 - Not colicky.
 - It is felt in the renal angle and radiates towards the umbilicus.
 - The intensity is altered by changing the position.

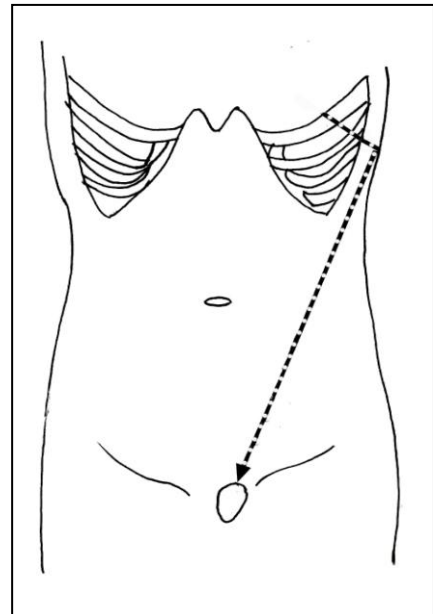


Fig. (2): Location and radiation of renal pain

2- Renal or ureteric colic:

- A stone is the most common cause leading to hyperperistalsis.
- The most severe pain a human-kind can experience.
- Intermittent, occurring in waves.
- The site of maximum intensity varies with the site of obstruction.
- Ureteric colic is usually accompanied by renal pain due to distension of the pelvis.
- Upper ureter is innervated similar to kidney so pain radiates to testis.
- Pain in mid-ureter simulates **appendicitis** or **diverticulitis**.
- The lower ureter sends sensory nerves common with pelvic organs. Pain is felt as suprapubic discomfort with vesical irritability (urgency, frequency) and radiates along urethra to tip of penis.
- Often associated with nausea, vomiting, sweating and collapse.
- Aggravated by jogging movements such as car journeys.
- Patients with ureteric colic are usually moving around in agony and holding the flank (**the rolling sign**) while patients with intra-peritoneal pathology prefer to lie motionless.

3- Bladder pain:

- Acute urine retention: The sudden inability to urinate inspite of the desire to do so. Pain is severe, bursting, felt in the suprapubic area. The bladder is full and over-distended due to complete obstruction.
- Chronic retention is painless and dribbling is noted as overflow incontinence.
- Cystitis: suprapubic burning pain is severe when the bladder is full and is relieved partially by voiding. It is associated with frequency and dysuria. Sharp stabbing suprapubic pain at the end of micturition is termed **strangury**.

- Constant suprapubic pain that is not related to acute retention is seldom of urologic origin.

4- Prostate pain:

- It is due to acute inflammation.
- Localized in the perineum and referred to lower back and rectum.
- Acute prostatitis is associated with fever, frequency, dysuria or acute retention and tenesmus.

5- Penile pain:

- Referred or secondary to cystitis or a stone.
- Pain in the flaccid penis is usually due to bladder or urethral inflammation.
- Paraphimosis: the uncircumcised foreskin is trapped behind the glans penis.
- Priapism: painful, persistent, purposeless penile erection.

6- Testicular pain:

- Primary pain is due to acute epididymo-orchitis, torsion of the testis or trauma.
- In patients with testicular discomfort and a normal scrotal examination, renal or retroperitoneal disease should be considered.
- Referred in renal or ureteric colic.
- Hydrocele, varicocele and testicular tumor may be associated with scrotal discomfort.

7- Urethral pain:

- Burning or scalding during micturition is usually due to inflammation or a stone.
- Dysuria is pain or burning during micturition usually caused by inflammation.

II- Voiding function and dysfunction**Normal voiding**

Micturition is urine disposal from the bladder to outside through the urethra. The process is voluntary in adults and depends upon learned behavior, while in infants it is an involuntary reflex. Micturition occurs as coordination between the vesico-urethral unit and the nervous system and consists of two phases:

A) Filling or storage:

During bladder filling the sympathetic tone predominates (**T₁₀ to L₂** through the hypogastric nerve). Alpha-receptors increase the muscle tone in the bladder outlet, while beta- receptors in the bladder body relax the detrusor. Pudendal nerve (somatic **S₂₋₄**) causes contraction of the striated external urethral sphincter.

B) Voiding or emptying:

- When the bladder is full stretch receptors are activated and signals are transmitted to the sacral cord. The pelvic nerve (parasympathetic, **S₂₋₄**) endings release acetylcholine and the detrusor contracts.
- Inhibitory impulses from the CNS to the sympathetic and pudendal nerves relax the bladder outlet.

The process of normal micturition is defined as follows:

A. Initiation:

A human can start the act of micturition even when the bladder is not full. Animals void only when the bladder is full. A human can postpone voiding of a full bladder until he can find a socially suitable place, go to it, adopt it and then start to pass urine.

B. Maintenance:

The normal urinary stream is continuous and free of pain, with adequate force, form and caliber

C. Termination:

A human can void all urine with **no post-voiding residual**.

The normal adult bladder can hold up to 500 ml of urine. We become aware of the need to void at 150 ml. At 400 ml we are seeking an appropriate toilet.

Voiding Disorders

(A) Difficulty in relation to voiding:

1- Difficulty to start:

Hesitancy: The need to wait before urine stream is voluntarily initiated.

Urgency: A short interval between the desire to void and the urgent need to do so.

Urge incontinence: A sudden severe urge to void with involuntary loss of urine.

2- Difficulty to maintain:

Intermittency: Involuntary stop and start of urine stream.

Weak stream: Decreased force and caliber of stream.

Bifurcation or spraying of stream.

Straining is the use of abdominal muscles to increase intra-abdominal pressure to urinate. Straining will help to void urine in case of urethral stricture. However, in prostatic obstruction,

the increased intra-abdominal pressure will lead to more obstruction by occlusion of the posterior urethra.

3- Difficulty to terminate:

- ***Sense of Incomplete emptying:*** A feeling that the bladder is not completely emptied at the end of urination.
- ***Strangury:*** Incomplete emptying with sharp stabbing suprapubic pain.
- ***Post void dribbling:***
 - Release of drops of urine after completion of urination. It is due to presence of small amount of urine in the bulbar urethra **Fig. (3)**. Manual compression and evacuation of the bulbar urethra in perineum is effective. Shaking the penis at end of micturition is ineffective.
 - It is an early symptom of BPH. A small amount of residual urine is normally milked back into the bladder at the end of micturition whereas in BPH, it escapes into the bulbar urethra and leaks out at the end of micturition.

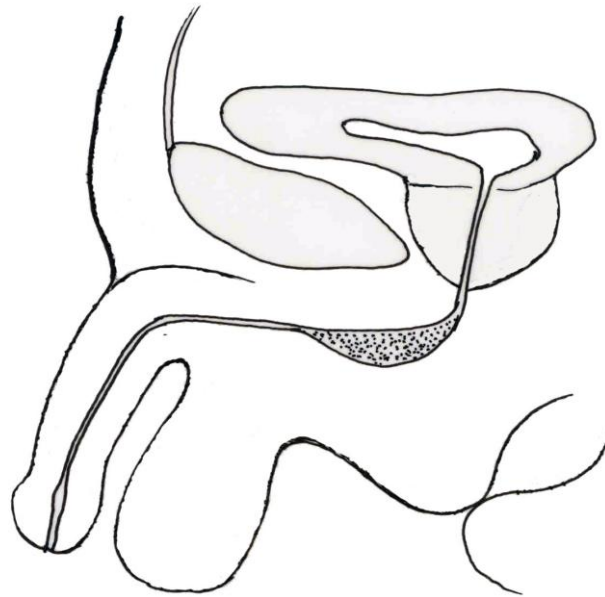
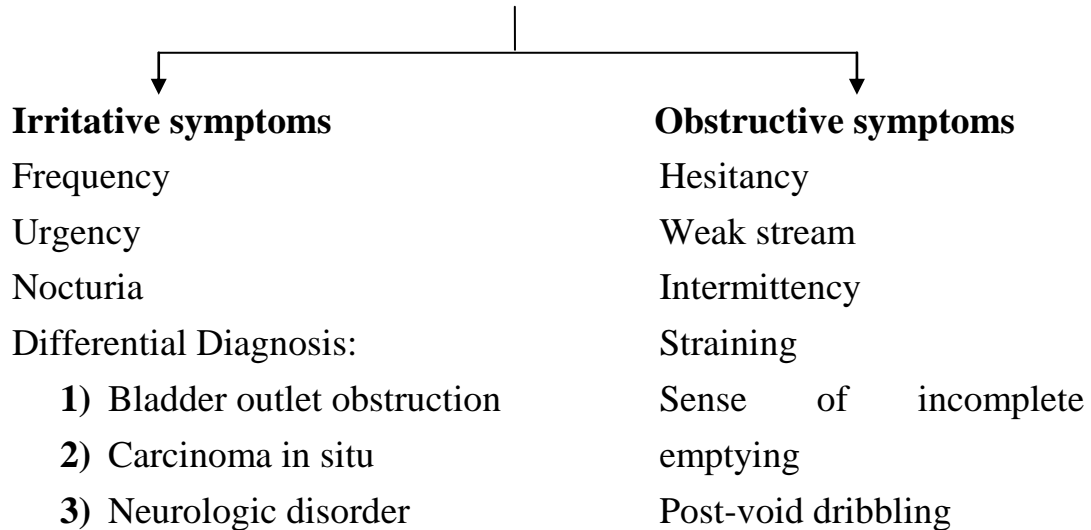


Fig. (3): Post-micturition dribbling due to the presence of small amount of residual urine in the bulbar urethra.

(B) Lower Urinary Tract Symptoms (LUTS):

(C) The American Urological Association symptom score (Table 1) is widely used to assess men with LUTS. It includes seven questions. The total score ranges from 0 to 7, 8 to 19, and 20 to 35 indicate mild, moderate and severe LUTS, respectively. The International Prostate Symptom Score (I-PSS) is helpful in the clinical management of men with LUTS and in assessment of treatment response.

- Limitations of the AUA symptom score:

- Non-specific.
- Patients with neurologic disorders and dementia may have difficulty in completion.
- Conditions other than BPH may have similar symptoms.
- Similar scores were recorded in age-matched men and women over 55 year.

(D) LUTS in prostatic disorders:

- In uncomplicated BPH, the LUTS are **periodic** and precipitated by excess *water, wine*, cold *weather*, sexual excitement by *women* without relief and *withholdment* of micturition.
- In prostate cancer most of cases are incidental, and when LUTS occur they tend to be **progressive**.

Table (1): International Prostate Symptom Score

	Not At All	Less Than 1 Time In 5	Less Than Half The Time	About Half The Time	More Than Half The Time	Almost Always	Your Score
1. Incomplete emptying Over the past month, how often have you had a sensation of not emptying your bladder completely after you finished urinating?	0	1	2	3	4	5	
2. Frequency Over the past month, how often have you had to urinate again less than two hours after you finished urinating?	0	1	2	3	4	5	
3. Intermittency Over the past month, how often have you found you stopped and started again several times when you urinated?	0	1	2	3	4	5	
4. Urgency Over the past month, how often have you found it difficult to postpone urination?	0	1	2	3	4	5	
5. Weak stream Over the past month, how often have you had a weak urinary stream?	0	1	2	3	4	5	
6. Straining Over the past month, how often have you had to push or strain to begin urination?	0	1	2	3	4	5	
	None	1 Time	2 time	3 times	4 times	5 times +	
7. Nocturia Over the past month, how many times did you most typically get up to urinate from the time you went to bed at night until the time you got up in the morning?	0	1	2	3	4	5	
Total I-PSS Score Quality of life due to urinary symptoms	Delighted	Pleases	Mostly Satisfied	Mixed-About Equally Satisfied And Dissatisfied	Mostly Dissatisfied	Unhappy	Terrible
If you were to spend the rest of your life with your urinary condition just the way it is now, how would you feel about that?	0	1	2	3	4	5	6

- (E) The urologist must be careful not to attribute irritative symptoms to BPH unless there is documented evidence of obstruction.
- (F) Hematuria associated with irritative symptoms should direct the attention of the urologist for further work-up for the possible diagnosis of **carcinoma in situ**.
- (G) Another important example is irritative symptoms resulting from **neurologic disease**, such as cerebro-vascular accidents, diabetes mellitus, and Parkinson's disease. The urologist should be careful to exclude neurologic disorders before performing surgery to relieve bladder outlet obstruction. Surgery will fail to relieve irritative symptoms and may result in permanent incontinence.

Frequency:

- Normal adult voids 5-6 times per day and arises no more than twice at night, with a volume of about 300 ml each.
- Frequency refers to increased number of times one feels the need to urinate.
- It is caused by functional or organic decrease in bladder capacity:
 - Inflammation: Edema and impaired elasticity.
 - Obstruction: Residual urine decreases the effective capacity.
 - Stones.
 - Foreign body.
 - Tumors.
 - Neuropathic bladders.
 - Contracted bladder: bilharziasis, T.B., radiation, interstitial cystitis.
 - Anxiety.
 - Pharmacological agents.
 - Psychogenic frequency: No nocturia.

Nocturia

"Voiding during nocturnal sleep hours, preceded and followed by sleep".

Diagnosis is based on general medical evaluation combined with voiding diary analysis (Fluid intake and output chart).

- Nocturia is the most bothersome LUTS.
- The prevalence of nocturia in women (43%) is similar to that in men (37%). It is a little more common in younger women and older men in whom causes other than BPH should be excluded.

- Etiology of nocturia (Fig 4):

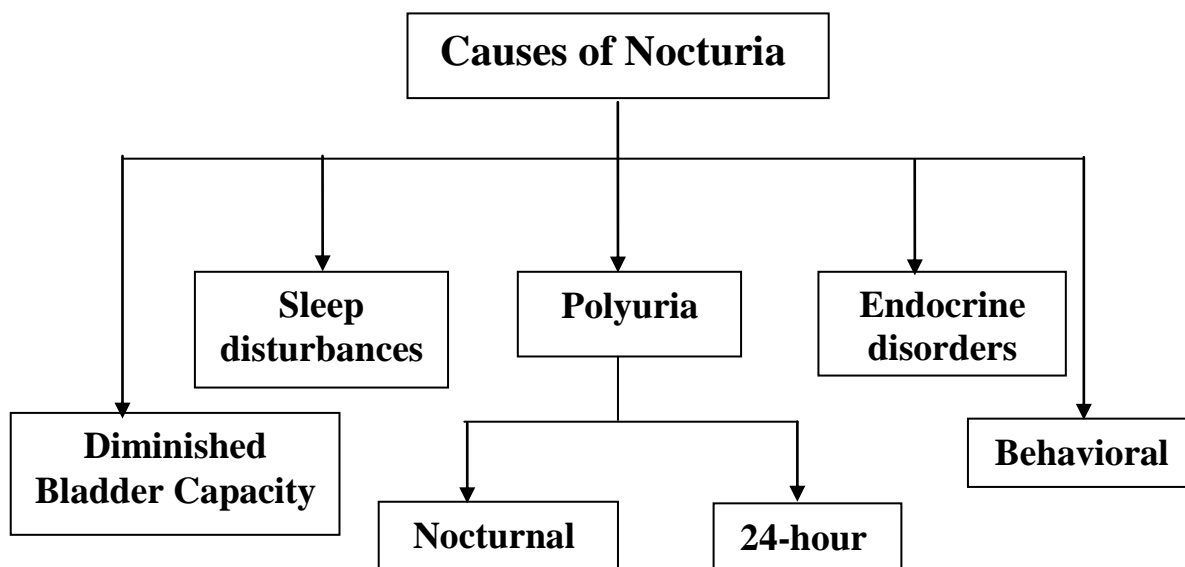


Fig. (4): Classification of causes of nocturia

A) Diminished bladder capacity: Causes of frequency.

B) Nocturnal polyuria:

- Peripheral edema (congestive heart failure, venous stasis, nephrotic syndrome, liver failure, hypo-albuminemia).
- Renal concentrating ability decreases with advanced age.
- The renal blood flow increases at night as a result of recumbency.

C) Sleep Disturbances: Obstructive sleep apnea.

D) Endocrine disorders: Diabetes mellitus, Diabetes insipidus.

E) Behavioral:

- Excessive nighttime fluid intake especially coffee and alcoholics.

Dysuria is painful micturition due to cystitis, urethritis, bladder stones or malignancy.

Nocturnal Enuresis:

Bedwetting at night is physiologic during the first 3 years of life but becomes troublesome to parents after that. It persists in 15% of children at age 5 and about 1% at age 15.

a) Functional:

It is secondary to delayed maturation of the vesico-urethral components.

b) Organic:

- Distal urethral stenosis in girls.
- Posterior urethral valves in boys.
- Infection.
- Neuropathic bladder.

Incontinence: Neither men nor women are totally continent. Slight stress incontinence in women and post micturition dribbling in men are so common as to be normal.

A) True incontinence:

It is defined as continuous involuntary loss of urine at all times and in all positions.

- Vesico-vaginal fistula: the most common cause.
- Exstrophy-epispadias.
- Neuropathic bladder.
- Sphincter injury by prostatectomy.
- Ectopic ureter that enters the female genital tract: patients have normal voiding with continuous small urinary leak. Ectopic ureters NEVER produce incontinence in males.

B) Stress Urinary Incontinence (SUI):

- Sudden loss of urine is association with physical strain e.g. coughing, sneezing and laughing.
- The intra-abdominal pressure exceeds the urethral resistance.
- SUI is seen in women after childbearing or menopause due to loss of muscle support.
- In men, SUI may be seen after prostatectomy.

C) Urge Incontinence:

- It is sudden strong desire to void with involuntary leakage of urine.
- Acute cystitis in women, neuropathic bladder, bladder outlet obstruction.

D) False (Overflow or paradoxical) Incontinence:

- Loss of urine due to chronic retention as in cases of enlarged prostate, stricture urethra or secondary to a flaccid bladder.
- The bladder is decompensated and acts as a fixed reservoir. When the intravesical pressure equals the urethral resistance, constant dribbling of urine occurs (mechanical overflow).

III- Changes in the gross appearance of urine

Table (2): Physical Characters of Urine

	Normal	Abnormal
Color	Amber yellow or Straw color	Red urine Milky urine
Aspect	Clear	Turbidity
Nature	Liquid	Gas Solid: Stones Necroturia Clots
Smell	Aromatic	Fishy Ammoniacal Fruity (acetonuria)
Volume	1 ml/min in adults (1500 ml/day)	No urine: Acute retention Anuria Oliguria Polyuria

The physical characters of urine in normal individuals and abnormal conditions are enlisted in **Table (2)**.

1- Color: causes of colorful urine are in table (3)

A. Red urine

B. Milky urine:

- The passage of lymphatic fluid (Chyle) is noted by the patient as milky white urine.
- Chyluria is caused by filariasis, trauma, T.B. and retroperitoneal tumors leading to lymphatic-urinary fistula.

Table (3): Common causes of colorful urine:

Colorless	Overhydration
Cloudy/Milky	Phosphaturia Pyuria Chyluria
Red	Hematuria Hemoglobinuria/myoglobinuria Anthrocyenin in beets and blackberries Chronic lead and mercury poisoning Phenolphthalein (in bowel evacuants) Phenothiazines Rifampin
Orange	Dehydration, drugs (Pyridium, Sulfasalazine)
Yellow	Normal, Drugs (Phenacetin, Riboflavin)
Green-Blue	Biliverdin Indicanuria (tryptophan indole metabolites) Amitriptyline Indigo carmine Methylene blue Phenols [cimetidine (Tagamet), promethazine (Phenergan)] Resorcinol Triamptere (Dyrenium)
Brown	Urobilinogen Porphyria Aloe, fava beans and rhubarb Chloroquine and primaquine Furazolidone (Furoxone) Metronidazole (Flagyl) Nitrofurantoin (Furadantin)
Brown-Black	Alcaptonuria (homogentisic acid) Hemorrhage Melanin Tyrosinosis (hydroxyphenylpyruvic acid) Cascara, senna (laxatives) Methocarbamol (Robaxin) Methyldopa (Aldomet) Sorbitol

2- Turbidity: Cloudy urine

a) **Phosphaturia:** The most common cause of cloudy urine.

Phosphate crystals precipitate in alkaline urine causing turbidity. It clears if acetic acid is added.

b) **Uricosuria:**

Uric acid crystals are dissolved in urine at body temperature. Uric acid precipitates if urine is left to cool down at room temperature causing turbidity. Urine becomes clear if heated.

c) **Pyuria :**

- Bacterial
- Abacterial or sterile pyuria (stones, obstruction, tumors, T.B.).
- Turbidity which neither disappears by acidification nor by heating is caused by pus.

3- Pneumaturia

The passage of gas bubbles in urine can be caused by:

- a- Fistula between bowel and bladder secondary to diverticulitis, regional ileitis, trauma and colon cancer. Coexistent **fecaluria** is present.
- b- UTI by sugar-fermenting organisms in poorly controlled diabetic patients.
- c- Iatrogenic: recent urinary tract instrumentation.
- d- Congenital: Urethro-rectal fistula.

4- Necroturia

The passage of pieces of tumor tissue in cases of carcinoma of the bilharzial bladder and described by the patient as "pieces of fat".

5- Passage of stones.

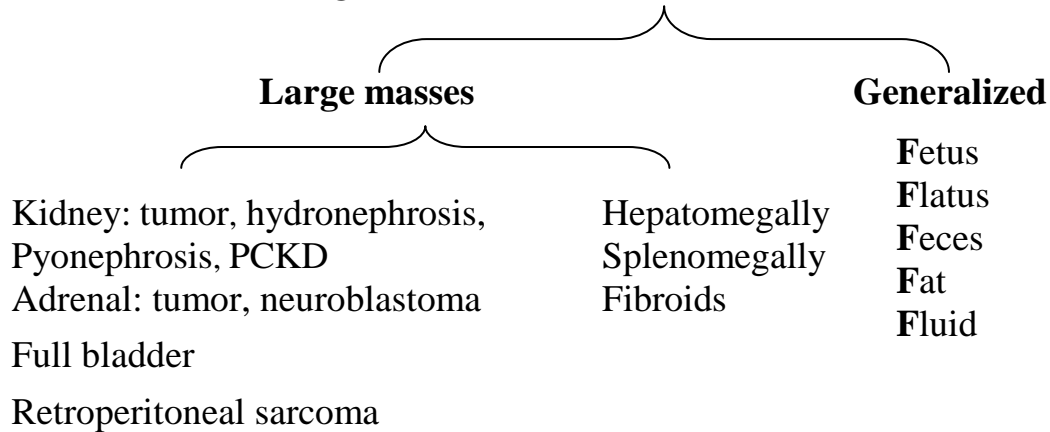
Smell

- a. Fishy smell is characteristic of E.coli infection.
- b. Ammonical smell is due to alkaline decomposition of urine.

IV- Swelling

The patient may present with a swelling as a symptom

1. Abdominal swellings



2. Lumps in the groin:

- Hernia (inguinal, femoral)
- Enlarged inguinal lymph nodes.
- Saphena varix.
- Hydrocele of the cord.
- Undescended testis.
- Lipoma of the cord.
- Femoral aneurysm.
- Psoas abscess.

3. Lumps in the scrotum

- Inguinal hernia.
- Hydrocele.
- Epididymal cyst.
- Orchitis.
- TB epididymo-orchitis.
- Testicular tumor.
- Gumma of the testis.
- Varicocele.
- Sebaceous cyst.
- Carcinoma of scrotal skin.

4. Cervical lymph node metastases from testis and kidney cancers.

V- Urethral Discharge

- **Discharge** is the passage of abnormal fluid through a natural passage e.g. urethral purulent discharge in men due to *Neisseria gonorrhea* or *Chlamydia trachomatis*. It is the most common symptom of venereal infection. A scant and watery discharge is generally associated with nonspecific urethritis. Comment on the following points:
 - Amount.
 - Color.
 - Presence of blood.
 - Relation of discharge to urination and ejaculation.
 - Pain.
 - Associated symptoms: conjunctivitis, arthralgia.
 - Relation to sexual contacts.
 - Exposure to STDs.
- **Fistula** on the other hand, leads to passage of normal fluid through an abnormal passage.
- **Urethral bleeding** is seen in trauma and tumors and should be differentiated from hematuria.
- **Urethrorrhagia:** At puberty, there is an increase in the size of the prostate which may be associated with hyper-vascularity and bleeding.

VI- Symptoms of chronic renal failure:

- Lack of concentration is the earliest symptom.
- Headache
- Blurring of vision.
- Epistaxis.
- Dry mouth.
- Tachypnea.
- Palpitations.
- Gastrointestinal manifestations.
- Genital problems.
- Itching is late.

Abnormal Appearance and/or Function of the Male External Genitalia

1- Impotence is the inability to achieve and maintain an erection sufficient for vaginal penetration.

- Psychogenic impotence has an abrupt onset secondary to marital stress. Patients will note early morning erections, and respond to different forms of sexual stimulation e.g., erotic videos and masturbation.
- Organic impotence develops gradually and is related to risk factors e.g. advancing age. The problem is present in all situations.
- Other sexual disorders should be excluded e.g. **Loss of libido**. It may indicate androgen deficiency from pituitary or testicular disorders which leads to decreased or absent ejaculation. Depression and medical diseases may be associated with loss of libido but the semen volume is normal.

2- Disorders of ejaculation and orgasm:

A) Premature ejaculation is persistent occurrence of ejaculation with minimal sexual stimulation before or shortly after penetration.

- It is common for men to ejaculate within 2 minutes after initiation of coitus. Men with true premature ejaculation reach orgasm within less than 1 minute.
- It is always psychogenic. Patients usually have normal sexual function with abnormal sexual expectations.

B) Retarded ejaculation is undue delay to reach orgasm.

C) Retrograde ejaculation is backflow of semen into the bladder due to incompetent bladder neck e.g. after bladder neck and prostatic surgery and in diabetic men.

D) Anejaculation: Failure to ejaculate may result from:

- Androgen deficiency.
- Sympathetic denervation e.g. retroperitoneal lymph node dissection in testicular cancer.
- Alpha-adrenergic blockers.
- Bladder neck and prostatic surgery.
- Diabetes mellitus.

E) Anorgasmia is the inability to achieve orgasm during intercourse.

Psychogenic

Psychotropic drugs.

Decreased penile sensation e.g. in diabetic neuropathy.

3- Hematospermia:

- The presence of blood in seminal fluid is usually due to nonspecific inflammation of the prostate or seminal vesicles or after a prolonged sexual abstinence and resolves spontaneously within several weeks.
- Exclude tuberculosis and prostate cancer if hematospermia persists.

4- Peyronie's disease: Curvature of the penis secondary to formation of fibrous plaques within the tunica albuginea.

5- Priapism: Persistent or prolonged (>4h), painful, purposeless (in the absence of sexual stimulation) penile erection.

6- Infertility is the inability to conceive after one year of unprotected sexual intercourse.

Indirect Urologic Symptoms

1. Gastrointestinal symptoms of urologic diseases:

- Acute pyelonephritis is associated with generalized abdominal pain and distension.
- Ureteric colic is associated with nausea, vomiting and distension.
- Silent urologic diseases (e.g. hydronephrosis, staghorn stone, chronic pyelonephritis and cancer) may present with gastrointestinal symptoms that mislead the clinician.

Causes:

- A.** Common sensory and autonomic innervations of the two systems.
- B.** Peritoneal irritation by inflammation.
- C.** Anatomical relationships.

2. Neurologic Disorders

A) Neurologic lesions cause urinary and sexual dysfunction:

- Multiple sclerosis: urinary symptoms are the first manifestations in 5%.
- Spinal cord injury.
- Cerebro-vascular disease.
- Parkinsonism.
- Diabetes mellitus.
- Meningo-myelocele.
- Spinal surgery.
- Inter-vertebral disc herniation.
- Pelvic surgery (hysterectomy, abdomino-perineal resection).

B) Bladder dysfunction may result from poor voiding habits in children, aging, inflammation and anxiety disorders.

3. Vascular Disorders

- Hypertension may be a manifestation of renal vascular disorders or adrenal masses.
- Symptoms in pheochromocytoma include (**PHEO**):

P Palpitations

H Headache

E Episodic sweating

O Orthostatic hypotension

- Hypertension resulting from pheochromocytoma is classified into:

Sustained hypertension	30%
Paroxysmal hypertension	30%
Combined sustained & paroxysmal hypertension	30%
Normotensive patients, incidental PHEO	10%

4. Congenital Disorders

- Adult polycystic kidney, von Hippel-Lindau and tuberous sclerosis are autosomal dominant diseases.
- Undescended testis and hypospadias have hereditary tendency.
- Congenital diseases are usually associated with other anomalies e.g. tuberous sclerosis patients may present with adenoma sebaceum, epilepsy and mental retardation.

5. Symptoms of Metastases

- Bone: Pain, swelling, nerve compression, spontaneous fracture.
- Lungs: Persistent cough, hemoptysis, blood-staining, pleural effusion.
- Liver: metastases develop late symptoms.
- Brain: headache, vomiting, visual disturbances, convulsions.
- Adrenals.

6. General Symptoms

- Fever: Acute inflammation of kidney, prostate and testis.
- Weight loss and cachexia: Malignancy
- Manifestations of uremia.
- Sick cell anemia: urologic complications:
 - Recurrent priapism.
 - Erectile dysfunction.
 - Papillary necrosis.

Acute Renal Failure

Oliguria, Anuria

- Anuria is complete absence of urine production by the kidneys for 12 hours or more.
- Oliguria is decreased urine volume to less than 400 ml in a day.
- Anuria and oliguria are symptoms of acute renal failure (ARF) which is divided into:

I- Prerenal ARF:

Pathophysiology: Hypotension → Shock → ↓Renal perfusion→↓ GFR → Oliguria or anuria.

Causes:

1. Hypovolemia: dehydration, prolonged vomiting, diarrhea, burns, excessive sweating.
2. Hemorrhagic shock: trauma, surgery and postpartum.
3. Sepsis: urinary, biliary,
4. Cardiogenic shock: myocardial infarction and pulmonary embolism.

Investigations:

1. Urine analysis: oliguria, high specific gravity.
2. High serum creatinine.
3. Hyperkalemia and acidosis may complicate the condition.
4. Ultrasonography: Normal appearance of both kidneys.

Treatment:

Correct the shock

Treat the cause

II-Renal:

Intrinsic acute renal failure may be due to: acute glomerulonephritis, ATN, acute interstitial nephritis, infiltrative myeloma or lymphoma. ATN may be toxic, ischemic or combined.

Pathophysiology: Acute tubular necrosis (ATN) → oliguria → recovery within 2-3 weeks of proper management. Prolonged prerenal ARF resulting in prolonged renal ischemia may lead to ischemic ATN.

Causes: (Fig.5)

- 1- Nephrotoxic drugs given to patients with impaired renal function:
 - Aminoglycosides.
 - Prolonged use of NSAIDs.
 - Angiotensin – converting enzyme inhibitors (ACEIs)
 - Cisplatinum
 - Cyclosporine overdosage in kidney transplant patients.
- 2- Poisons.
- 3- Contrast media in patients with diabetes mellitus and multiple myeloma.
- 4- Anesthesia.
- 5- Eclampsia.
- 6- Incompatible blood transfusion.
- 7- Disseminated intravascular coagulopathy (DIC).
- 8- Myoglobinuria: Crush syndrome.
- 9- Kidney transplantation: prolonged ischemia, acute rejection, cyclosporine toxicity.

Investigation:

Urine analysis: low specific gravity, tubular cells.

Ultrasound: ↑ kidney size, no change in parenchymal architecture.

Fine needle aspiration biopsy (FNAB) in kidney transplant:

- Acute rejection: lymphoblastic cells.
- Cyclosporine toxicity: damaged tubular and endothelial cells.

Treatment:

- Fluid intake should be equal to daily urine volume + sweat + perspiration. Excessive intake may lead to congestive heart failure and pulmonary edema.
- ATN following kidney transplant should be differentiated from acute rejection and cyclosporine toxicity.
- Dialysis if the condition is prolonged.

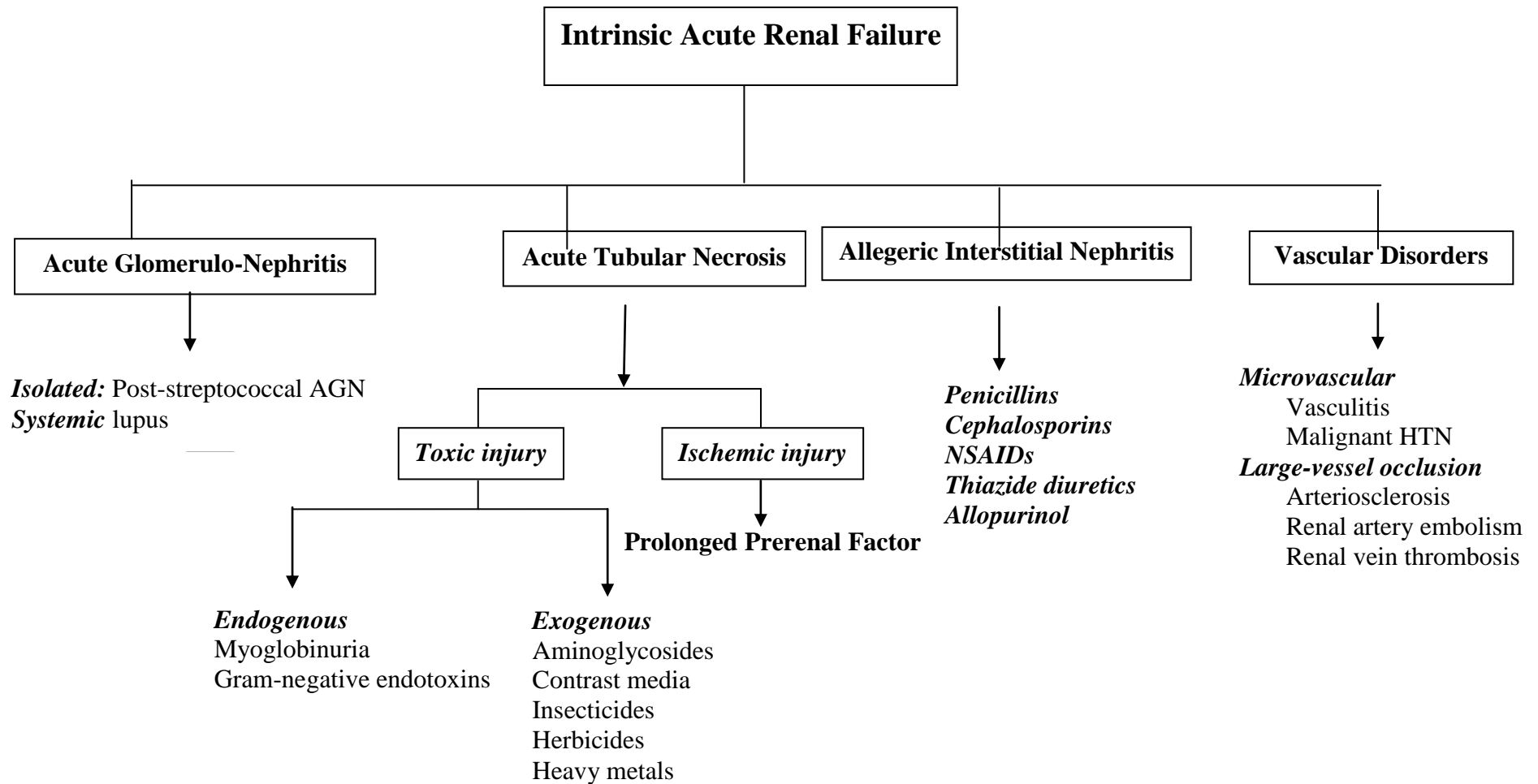


Fig. (5): Causes of intrinsic acute renal failure

III- Postrenal (obstructive) anuria:

The classic example is a stone impacted in the ureter of a solitary kidney (spasm of ureteral muscle, edema of the mucosa). There is renal pain and anuria. The urinary bladder is empty. There is circulatory volume and osmotic overload. Serum creatinine is rising and electrolyte imbalance will occur.

Causes:

- 1- Stones are the most common cause. The other kidney may be surgically absent or nonfunctioning.
- 2- Malignant tumors causing bilateral ureteral obstruction: prostate, bladder, cervix, rectosigmoid
- 3- Surgery: bilateral ligation of the ureters during hysterectomy.
- 4- Retroperitoneal fibrosis.
- 5- Bilharzial ureteric strictures.
- 6- Crystaluria: uric acid crystals in patients receiving chemotherapy for lymphoma and leukemia.

History:

Renal pain or colic
Anuria
No desire to micturate
Etiologic e.g. hysterectomy

Examination:

- The urinary bladder is empty on catheterization.
- Prostate, bladder, cervical or rectal tumors can be palpated.

Investigations:

- Serum creatinine ↑
- Electrolytes: Na, K, pH
[Hyperkalemia > 7 mEq/l may lead to arrhythmia and cardiac arrest].
- Ultrasonography: hydronephrosis, stones.
- KUB: radio-opaque stones.
- Spiral CT: stones, dilatation of pelvicalyceal system proximal to obstruction.

Treatment:

- Cystoscopy and ureteral catheterization to bypass the obstruction and drain the kidney.
- Percutaneous nephrostomy (PCN) if ureteric catheter fails.
- Treatment of the cause e.g. ureteroscopic stone removal.
- Postobstructive diuresis: relief of obstruction is followed by diuresis due to volume and osmotic overload. Adequate fluid balance should be observed.
- Treatment of hyperkalemia:
 - a) Calcium resonium enema, intravenous injection of calcium to protect the heart from the toxic effect of $\uparrow k^+$.
 - b) Insulin + glucose 25% to shift k^+ from extracellular to intracellular compartment.
 - c) Correction of acidosis.
- Dialysis-indications:
 - Life threatening hyperkalemia.
 - Uncontrolled acidosis
 - Congestive heart failure.
 - Uremic encephalopathy.

Acute Urinary Retention

It is a sudden painful inability to urinate inspite of a full bladder. Relief of pain follows drainage by catheterization.

Normal micturition cycle:

- A. Filling: Impulses from the CNS to sympathetic and pudendal nerves relax the bladder and close the outlet.
- B. Voiding: Inhibition of sympathetic and pudendal impulses. Stimulation of parasympathetic (S2-4) leads to detrusor contraction → voiding in the absence of obstruction.

Causes:

A. Mechanical or obstructive:

- 1- Bladder:
 - Stone, bladder neck obstruction, cancer.
- 2- Prostate:
 - BPH is the most common cause in men over 50 years.
 - Acute prostatitis and abscess.
 - Prostate cancer.
- 3- Urethra:
 - Stone, stricture, urethritis, rupture, phimosis, posterior urethral valves.
- 4- Clot retention in severe hematuria e.g. cancer, trauma.
- 5- Women: pelvic masses, urethral stenosis and diverticulum, pelvic prolapse, hysterical.

C. Functional and neurogenic:

- 1- Postoperative AUR is common:
 - Pain, limited mobility, drugs, bladder nerve injury e.g. hysterectomy & abdominal resection.
 - Prevention is important by catheterization after surgery to bladder, prostate, urethra.
- 2- Drugs:
 - Anesthetics
 - Anticholinergics
 - Sympathomimetics

3- Neurogenic:

- Spinal cord injury.
- Diabetic neuropathy.
- Cauda equina lesions.
- Intervertebral disc prolapse.
- Neurotropic viruses: Herpes simplex or zoster.
- Multiple sclerosis.
- Transverse myelitis.
- Tabes dorsalis.

History:

- Cause- related:

A complication of BPH

Drugs:

Urethral trauma

Stone disease

- Suprapubic bursting pain, no urine, strong desire to urinate.
- Acute urine retention should be differentiated from obstructive anuria (Table 4).

Abdominal Examination: Midline globular tender suprapubic mass.

Genital examination: Phimosis, severe urethral meatal stenosis.

DRE: BPH, Prostate cancer.

Table 4: Differential diagnosis of acute retention and obstructive anuria

	Acute retention	Obstructive anuria
Desire to urinate	+	--
Suprapubic pain	+	--
Renal pain	--	+
General exam.	Good	May be uremic
Abdominal exam.	Full bladder	Empty bladder Tender loin
Emergency measures	<ul style="list-style-type: none"> - Urethral catheter or - Suprapubic catheter if urethral trauma or injury are expected 	<ul style="list-style-type: none"> - Ureteric catheter Or DJ stent Failure - PCN

Treatment:**A) Conservative measures in non-obstructive causes:**

- Patient is asked to go out of bed.
- Hot bath.
- Parasympathomimetics.
- Failure → catheterization.

B) Urethral catheterization: Nelaton or Foley's:

- It is absolutely contraindicated in urethral injury.
- Sterilization.
- Adequate lubrication.
- Proper catheter size

Children 6-12 F

Adults 16 F

Clot retention: triway 22F with continuous irrigation

- Gentle manipulation

C) Clot retention:

- Triway 22F urethral catheter with irrigation.
- Evacuation of clots.
- Cystoscopy diagnostic and therapeutic.

D) Suprapubic cystocath:

- Urethral trauma
- Urethral stricture
- Failure of urethral catheterization

E) Treatment of the cause e.g.

- TURP for BPH
- VIU or urethroplasty for urethral stricture.
- Endoscopic crushing of vesical stone.

Chronic Retention of Urine

Causes: Long standing incomplete obstruction

A) Mechanical : BPH, prostate cancer

B) Functional: Neuropathic flaccid bladder.

- Large amounts of residual urine exist.
- When the vesical pressure exceeds the urethral resistance, the patient can pass some urine or dribble continuously. This is called **false or overflow incontinence**.
- The Differentiation between acute and chronic urine retention is shown in table 5.

Complications: Bilateral hydroureteronephrosis & uremia.

Treatment:

- Urethral catheterization is done if upper urinary tract deterioration exists.
- Investigation for the cause.
- Treat the cause.

Table 5: Differentiation between acute and chronic urine retention.

	Acute retention	Chronic retention
Urination	No urine	Overflow incontinence
Pain	Severe, suprapubic, bursting	Painless
Obstruction	Complete	Partial
Suprapubic tenderness	+	--
Renal failure	--	May be present

Hematuria

Definition: Blood in urine.

Hematuria can be classified in different ways:

A) Intensity:

- 1- Microscopic: The presence of >5 RBCs / hpf.
- 2- Macroscopic or Gross: Urine is red. This is a "red sign" for the patient to ask for medical advice.

B) Origin:

- 1- Systemic disease.
- 2- Urinary tract pathology.

C) Relation to micturition:

- 1- Total hematuria is present all over the voided urine. Underlying pathology may be in kidney, ureter, bladder or prostate or systemic. Bleeding from kidney is associated with cylindrical worm-like clots. Hematuria from bladder and prostate is associated with big irregular or discoid clots.
- 2- Terminal hematuria at the end of micturition is of vesical origin e.g. active bilharzial cystitis. It is usually due to bladder neck or prostatic inflammation.
- 3- Initial hematuria at the beginning of micturition indicates urethral pathology.

D) Associated symptoms:

- Painless hematuria: No other urinary symptoms: All cases should be investigated for urologic malignancy. Bladder cancer is the most common and should be excluded.
- Hematuria associated with other symptoms:
 - Simple cystitis: frequency, burning, urgency and terminal hematuria.
 - Malignant cystitis: severe frequency, pain, urge incontinence, total hematuria with clots or necroturia.

- Ureteral obstruction due to blood clots is the most common cause of pain associated with gross haematuria.
- Stones: Renal pain.
- BPH, prostate cancer: associated LUTS (prostatism).
- Surgical trauma to kidney and bladder e.g. PCNL & TURBT.

E) Etiologic:**I) General or systemic:**

- Bleeding disorder: thrombocytopenic purpura, leukemia, hemophilia.
- Liver cirrhosis.
- Anticoagulants.
- Hypertension.

II) Renal causes:**A) Nephrologic: dysmorphic RBCs**

Acute glomerulonephritis is the most common cause in children and young adults. It is associated with proteinuria.

b) Urologic: normomorph RBCs.

- Congenital: Polycystic kidney.
- Inflammation: Pyelonephritis, TB.
- Trauma: Accidents, Iatrogenic.
- Stones
- Kidney cancer
- Vascular: Hemangiomas, AV fistula.

III) Ureteral:

- Stones.
- Iatrogenic trauma e.g. ureteroscopy.
- Tumors: TCC of pelvis and ureter.

IV) Bladder:

- Bladder cancer is the most common cause of gross hematuria in a patient above 50.
- Bladder cancer is the most common tumor in men in Egypt.
- Cystitis: Bacterial, bilharzial, T.B.
- Stones
- Trauma e.g. post TURBT.

V) Prostate

- BPH
- Prostate cancer
- Prostatitis
- Surgical: after prostatectomy

VI) Posterior urethra:

- Inflammation
- Trauma
- Tumor

Differential Diagnosis:**1. Red Urine:** No RBCs by microscopy

- Hemoglobinuria → purple color.
- Food: beetroots → red translucent urine.
- Drugs: rifampicin → red translucent urine.

2. Urethral bleeding:

- The lesion is distal to the external urethral sphincter e.g. rupture anterior urethra due to falling astride.
- Blood is seen on the underwear without micturition.

Diagnosis:**A) History**

- Age: < 40 years: inflammation, stones.
> 40 years: tumors.
- Sex: BPH, prostate cancer in elderly men.
- Trauma: Violence, accidents → blunt, penetrating
Surgery: Open, endoscopic
- Bilharziasis and stone disease,
- Systemic disease; liver cirrhosis.
- Obstructive symptoms: BPH, prostate cancer.

B) Physical examination:

- General: Hypertension
Petecheal hemorrhages.
- Abdominal: Renal mass.

- Genital: T.B. thickening and beading of vas.
- DRE: Bladder mass, BPH, prostate cancer.
- P.V.: Bladder mass.

C) Investigations:**Laboratory:**

- Blood: CBC, liver function tests, creatinine, blood glucose.
- Attention to platelets, prothrombin, clotting and coagulation time.
- Urine analysis and culture: microscopic hematuria with pyuria (UTI), crystals (stones), ...

Radiologic:

- Ultrasound: renal masses, stones, polycystic kidneys, bladder mass....
- KUB: Radio-opaque stones.
- Non-contrast CT: stone disease.
- CT with contrast: kidney, ureteric, bladder and prostate cancer evaluation.

Endoscopy:

- Ureteroscopy: Stones, tumors of ureter.
- Cystoscopy: diagnostic and therapeutic in bladder cancer.

Treatment**A) Emergency**

- Blood transfusion if necessary.
- Clot retention is an emergency condition.
- Clots are evacuated and triway 22 F urethral catheter is inserted with continuous irrigation.
- Cystoscopy and coagulation of the bleeding source e.g. bladder tumor, post- TURBT or TURP.
- Arterial embolization is performed in significant hematuria after PCNL or kidney trauma.
- Open surgery may be necessary if other measures fail.

B) Treat the cause

General Examination

- Note the general appearance while talking.
- Hands and radial pulse.
- Face and mouth.
- Neck.
- Chest and heart.
- Lower limbs (edema, circulation, loco-motor functions and neurological).
- Abdominal examination.
- Scrotum.
- Pelvic examination.
- Height and weight (BMI).
- Urinalysis.

Examination of the face:

1-Uremia:

- Sallow complexion (a dirty brown appearance or uremic tinge) due to impaired excretion of urochromes and anemia.
- Hyperventilation: metabolic acidosis.
- Hiccup.
- Uremic fetor: ammoniacal fish breath due to breakdown of urea in saliva.
- Eyes:
 - Anemia.
 - Jaundice.

- Band keratopathy: calcium deposition beneath the corneal epithelium in line with the inter-palpebral fissure due to excessive calcium replacement or hyperparathyroidism.
- Muscle twitches due to tetany and epilepsy.
- Subcutaneous nodules (calcium phosphate).

2-Cushing's syndrome:

- Moon face.
- Plethora.
- Acne.
- Hirsutism.
- Buffalo hump.

3-Tuberous sclerosis: familial

- Adenoma sebaceum.
- Mental retardation.
- Epilepsy.
- Renal hamartoma (angiomyolipoma).

Complexion:

1- Pallor:

- The normal conjunctiva is red pink in the palpebral part and creamy in the sclera. This difference is absent in significant anemia.
- The palmar skin creases and nail beds are inspected.

2-Jaundice:

- Yellowish pigmentation of the skin, sclera and mucous membranes due to increased bilirubin
- Best appreciated in natural daylight.

3-Cyanosis

- Bluish discoloration of the skin and mucous membranes due to increased deoxygenated hemoglobin in blood.
- Central cyanosis: blue tongue& periphery:
 - Chronic obstructive pulmonary disease.
 - Massive pulmonary embolism.
 - Cyanotic congenital heart disease.
 - Polycythemia.
 - Met- and sulph-hemoglobinemia.
- Peripheral cyanosis: blue fingers and toes:
 - All causes of central cyanosis.
 - Exposure to cold.
 - Reduced cardiac output (shock, left ventricular failure).
 - Peripheral vascular obstruction.

Examination of the neck:

Inspection:

- Sit the patient with the head looking straight ahead.
- Look for overall symmetry and lumps.

A lump in or close to the midline suggests a thyroid lesion which moves with swallowing.
- Skin ulcers or sinuses suggest T.B.
- Venous engorgement.

Palpation:

- Systematic palpation: anterior triangle (\pm swallowing), submental and submandibular areas, posterior triangle and the supraclavicular fossae.

- Thyroid lumps. Is it unilateral or bilateral? Does it move with tongue protrusion?
- Carotid arteries. Are they normal, dilated or aneurysmal?

Supraclavicular Nodes: (See page 52)

Vital Signs

Critical information about the state of health

Observation

- Anxious, in pain, upset
- Dress
- Hygiene

Temperature:

- Recording will depend on the site of measurement. Normal oral temperature is 37°C (36.5-37.2°C). Rectal temperature is 0.5 °C higher, while axillary temperature is 0.5 °C lower.
- **Fever** is an increase in body temperature resulting from a cellular response to inflammation, immunological disorders or malignancy.

Causes:

- Inflammation:** Acute infections of parenchymatous organs.
Kidney: Acute pyelonephritis, renal abscesses, pyonephrosis, infected hydronephrosis and emphysematous pyelonephritis.
Prostate: Acute prostatitis and prostate abscess.
Testis: Epididymo-orchitis.
 - Malignancy:** Kidney cancer will cause fever particularly when it is metastatic or necrotic.
 - Central Nervous System:** Head injury, cerebral hemorrhage.
 - Metabolic:** Acute gout.
 - Drugs:** Morphine, sulfonamides and hypersensitivity conditions.
 - Surgical and Post-traumatic:** Patients with collection of pus have a high-grade swinging fever with rigors. Infected collections of blood or urine will cause fever.
- **Hypothermia:** Shock states, starvation, prolonged unconsciousness, elderly immobile patients during winter and severe hypothyroidism.

Respiratory Rate

12-20 breaths/ min

Pulse

- Quantity beats/min
- Regularity
- Volume

Hormonal hypertension of urologic importance:**A) High renin HTN:**

- 1) Renovascular abnormalities.
- 2) Juxtaglomerular cell tumors.
- 3) Bilateral endocrine dysfunction of the kidney.
- 4) Renal tumors.

B) Low renin HTN:

- 1) Conn's syndrome (primary aldosteronism).
- 2) Cushing syndrome.
- 3) Congenital adrenal hyperplasia.

C) High catecholamines:

- 1) Pheochromocytoma.
- 2) Neuroblastoma.

Body Habitus:**A. Body mass index (BMI):**

$$BMI = \frac{Weight (Kg)}{Height^2 (m)}$$

Normal	19-25
Overweight	25-30
Obesity	30-40
Morbid Obesity	>40 kg/m ²

- Information on waist circumference refines associated disease risks. A circumference greater than 102 cm in men or 88 cm in women indicates increased metabolic risk.

B. Obesity

- Obesity increases risk for almost all types of cancer, reproductive disorders, hypertension, diabetes mellitus, cardiovascular disease, stroke, and gallbladder disease.
- It obscures intra-abdominal physical signs, increases difficulties in many operations and post-operative complications.
- Causes:
 - Simple: overeating
 - Endocrine:

Cushing's syndrome

Hypothyroidism

Hyper-insulinism

Hypogonadism

- Drug- induced: corticosteroids
- Genetic

C. Weight Loss

- There is muscle weakness and prominent bones (cheek, humoral head, major joints, rib cage, pelvis)
- Causes
 - Malnutrition
 - Malignancy
 - Renal failure
 - Gastrointestinal disease
 - Sepsis
 - Trauma
 - Post-surgery
 - Psychological

Malignant cachexia

- Marked loss of weight suggested by clothes.
- Features:
 - Emaciated facies
 - Loose, wrinkled dry skin
 - Mouth infection thrush
 - Loss of energy and appetite
 - Ascites

Dehydration

- Clinical features appear when there is loss of about 4 liters in an average adult (6% of 70 kg body weight). There is loss of sodium chloride and water.
- Assessment is essential in excessive vomiting, diarrhea, sweating, polyuria and fever.
- Features:
 - Thirst.
 - Sunken eyes.

-
- Weight loss.
 - Muscle weakness.
 - Skin turgor is unreliable: Gentle skin pinching of neck or chest wall leads to slow subsidence (the sign of the ridge)
 - The skin is dry and wrinkled.
 - Dry mucous membranes.
The tongue may be dry due to mouth breathing.
 - Postural hypotension.
 - Tachycardia.
 - Assessment of JVP is the most sensitive way.
 - JVP is decreased, collapsed veins.
 - Dry axillae.
 - Axillary palpation shows sweating in well- hydrated patients.
 - Concentrated urine, oliguria.

Edema

- Swelling of tissues due to an increase in the interstitial fluid that can be detected by pitting of the skin on pressure. Myxedema due to hypothyroidism and chronic lymphedema do not pit.

A. Unilateral leg edema:

This is caused by venous or lymphatic obstruction.

- Cellulitis: redness, hotness, tenderness
- Compression of large veins:
 - Tumors e.g pelvic tumors.
 - Enlarged lymph nodes.
 - Scar tissue post surgery and irradiation.
- Phlebo-thrombosis
- Immobility e.g. hemiplegia
- Trauma
- Filariasis
- Hereditary edema of one or both lower limbs (Milroy's disease)

B. Bilateral leg edema:

- Systemic causes (hypo-proteinemia, fluid overload).
- Congestive heart failure: congested neck veins, enlarged tender liver and orthopnea.

- Liver cirrhosis: marked ascites, moderate edema of lower limbs and signs of liver failure.
- **Renal diseases:**
 - Nephrotic syndrome:*
 - Massive peripheral edema
 - Hydrothorax and ascites
 - Proteinuria > 3.5 g/day, Hypoalbuminemia <3 g/dL
 - Hyperlipidemia, Lipiduria
 - Acute glomerulonephritis:*
 - History of streptococcal infection.
 - Mild generalized edema with puffy eye-lids.
 - Hematuria.
 - Flank pain and oliguria.
 - Moderate to marked hypertension.
 - Elevated antistreptolysin O titer, hypocomplementemia.
- Gastrointestinal:
 - Excessive bowel resection
 - Crohn's disease
 - Protein- losing enteropathy.
- Drugs
 - NSAIDs, Corticosteroids.
- Bilateral venous or lymphatic obstruction:
 - IVC obstruction in RCC.
 - Filariasis

Lymph Nodes

- Normal glands in adults are seldom greater than 0.5 cm in diameter.
- Enlarged lymph nodes are usually of clinical importance in malignancy and lympho-proliferative disorders.
- General principles of examination: Inspect, palpate and compare with the other side in a systematic pattern:
 1. Site (Cervical, axillary, abdominal, inguinal, popliteal).
 2. Size: Precise measurement in cancer patients is an index of therapeutic response.
 3. Tenderness indicates inflammation.
 4. Mobility in relation to the surroundings, deep structures and skin.
 5. Consistency: metastatic nodes are stony hard; they are firm or rubbery in lymphomas.
 6. Matting: nodes feel as if they are connected, in metastasis, lymphomas, chronic inflammation and sarcoidosis.
 7. Pressure on the surrounding structures: Huge retroperitoneal lymphadenopathy may result in bilateral lower limb edema.
 8. Compare with the glands on the contralateral side.
- **Localized lymphadenopathy**
 1. Infective:
 - Acute or chronic
 - Bacterial or viral
 2. Metastatic: the glands are hard and may be fixed.
 3. Lymphoma: look for enlargement of the liver and spleen and for hematological disorders e.g. purpura or petechiae. Lymphadenopathy is confined to one group in early cases. The glands are rubbery and discrete.
- **Generalized lymphadenopathy:**
 1. Hematological malignancies: lymphoma, leukemia
 2. Infections:
 - Viral: HIV, infectious mononucleosis, CMV.
 - Bacterial: TB, syphilis, brucellosis.
 3. Autoimmune disease:
 - Systemic lupus erythematosus

Amyloidosis

4. Infiltrative disease: sarcoidosis, amyloidosis.
5. Drugs e.g. phenytoin.

Metastatic Lymph Node Enlargement:

- **Cervical:** from tumors of mouth, nasopharynx, thyroid and larynx.
- **Supraclavicular nodes:**
 - Lymphadenopathy suggests malignancy.
 - Cancer of the breast and bronchus may metastasize to the ipsilateral supraclavicular nodes.
 - The left supraclavicular nodes may be involved by metastases from abdominal organs e.g. gastric carcinoma or from the testis (Trousier's nodes or Virchow's node).
- **Axillary nodes:** from breast cancer.
- **Mediastinal** compression due to lymphoma or metastatic lymph nodes.
- **Abdominal:**
 - Retroperitoneal lymphadenopathy is especially seen in testicular tumors.
 - Physical examination should include palpation of the abdomen for evidence of bulky retroperitoneal nodal disease in the upper abdomen near the midline.
- **Inguinal:**
 - Palpate over the horizontal group below and parallel to the inguinal ligament and the vertical chain along the saphenous vein.
 - In malignant tumors of penis, scrotum and distal urethra in women, careful bilateral clinical evaluation of the inguinal lymph nodes is important.
 - Penile carcinoma is accompanied by considerable secondary infection.
 - The superficial lymphatics drain into the inguinal lymph nodes (horizontal and vertical groups). The deep lymphatics drain into the iliac lymph nodes.
 - 4-6 weeks course of broad spectrum antibiotics, re-evaluation.

- Testicular tumors do not spread to the inguinal lymph nodes unless they have invaded the scrotum or the patient had orchidopexy.
- ***Popliteal*** behind the knee joint.

Chest and Heart

Inspection:

- Scars, prominent veins, lesions, deformity.
- Shape of the chest.
- Rate and depth of breathing:
 - Systemic acidosis: deep, sighing Kussmaul's respiration.
 - Anxiety: deep, fast.
- Chest wall movements are observed.

Palpation:

- Trachea lies in the midline deep to the sternal notch. It shifts if the mediastinum is pushed laterally.
- Heart apex beats normally at the 5th intercostal space in the midclavicular line.

Percussion:

- Normal lungs are resonant.
- Hyper-resonance: pneumothorax, emphysematous bullae.
- Dullness: collapse, consolidation, peripheral abscess, neoplasm.
- Stony dullness over the heart is diminished in chronic obstructive pulmonary disease.
- The liver dullness is noted below the level of the 6th rib in the midclavicular line. It is lost with hyperinflated lungs.

Auscultation:

- Normal breath sounds are vesicular or rustling heard during inspiration and early expiration.
- Reduced sounds:
 - Localized: pneumothorax, pleural effusion, pneumonia, tumor, lung collapse.
 - Generalized: COPD, asthma.

- Wheezes: musical expiration sounds caused by narrow airways e.g. COPD and asthma.
- Crepitations: Air entering collapsed airways produces inspiratory crackles e.g. infection, fluid.
- Rub: inflamed pleural surfaces rub against each other.
- Important chest problems in urologic practice are shown in table (6).

Table (6): Important chest problems in urologic practice

	Pneumothorax	Pleural effusion	Collapse
Etiology	Air in pleura	Fluid in pleura	Bronchial obstruction → collapse of lung segment
Mediastinal shift	Away	Away	Towards the lesion
Percussion	Hyper-resonance	Stony dullness	Dullness
Breath sounds	Absent	Absent	Diminished

Abdominal Examination

- General principles to have adequate relaxation and maximize patient comfort.
 - Good light, warm room.
 - Full exposure from nipples to knees.
 - Supine position, head supported by a pillow and knees are slightly flexed with feet on table.
 - Arms across chest or on sides.
 - Watch the patient face for signs of pain.
 - Explain what you are about to do and ask permission.
 - Look, listen then feel and percuss.
 - The painful area should be examined last.
 - Stand on the right side of the patient.
- Abdomen is divided into 4 quadrants based on two perpendicular planes drawn through the umbilicus: right upper, right lower, left upper and left lower (**Fig 6**). The umbilical area is considered as the central fifth region.
- The abdomen is divided into classic 9 regions by 2 horizontal and 2 sagittal planes (**Fig. 7**). The upper horizontal one is between the lower borders of the ribs, at the level of the first lumbar vertebra, midway between the suprasternal notch and symphysis pubis (transpyloric). The lower passes through the upper borders of iliac crests. The sagittal planes go vertically from the mid-clavicular to the mid-inguinale points.

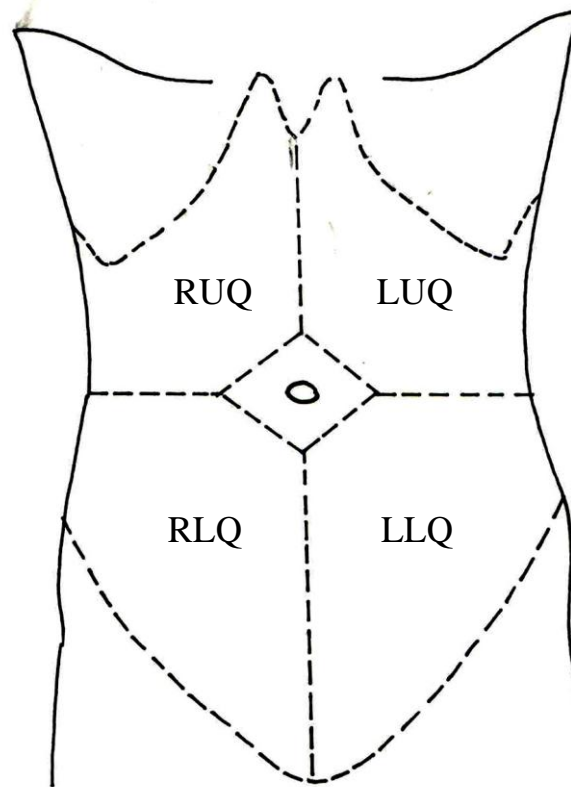


Fig. (6): Division of the abdomen into 5 areas: RUQ (Right Upper Quadrant), LUQ (Left Upper), RLQ (Right lower), LLQ (Left lower) and U (umbilical or central)

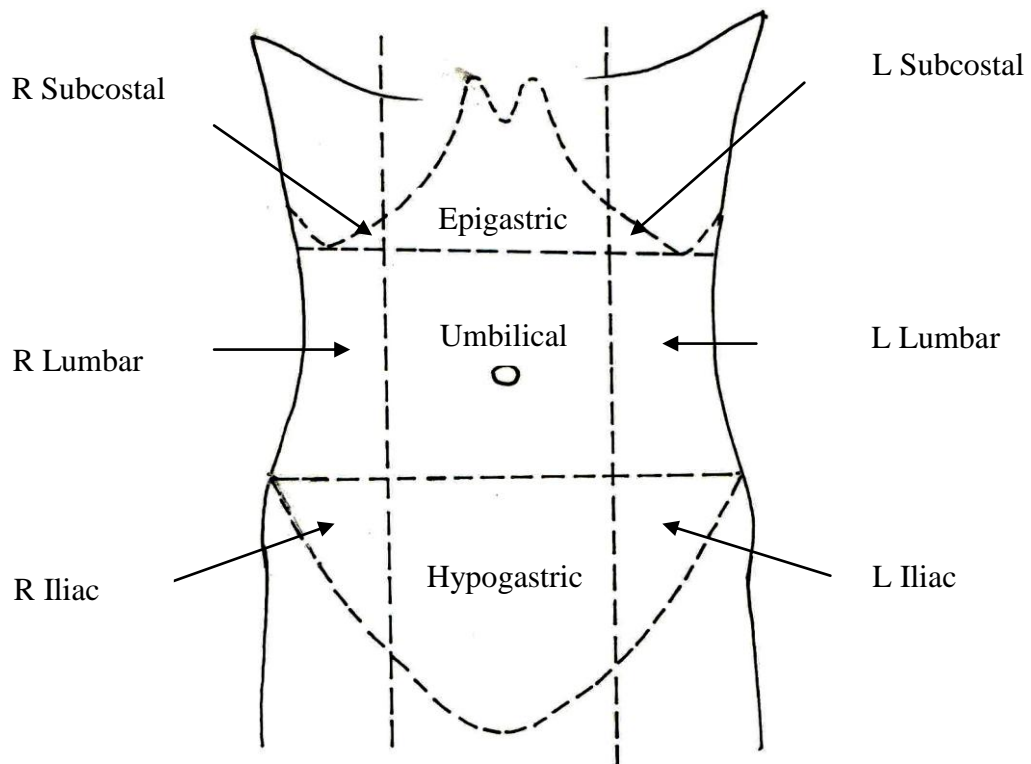


Fig. (7): Division of the abdomen into 9 areas

A- Inspection

Visual examination with observation notes made of the following:

a. Abdominal shape or contour:

- Scaphoid (malnutrition), flat, rounded or swollen.
- Asymmetry with organo-megaly and masses.
- Generalized bulging: fat, flatus, fluid, fetus and feces.
- Localized bulging:
 - Upper half: Pancreatic cyst or tumor
 - Lower half: pregnancy, distended bladder, ovarian tumor or uterine fibroids.
- Visible organs or masses: A renal swelling may give fullness or bulge in the flank.
- Abdominal wall lumps persist while intra-abdominal swellings disappear by tensing the abdominal muscles by straight leg raising from the bed.

b. Skin Abnormalities:

- Surgical scars: Location, appearance and characteristics:
 - Where are they? How old do they appear? Is there evidence of herniation on coughing?
 - New scars: are raised and red gradually fading to pink.
 - By 6 months, they are flat and skin colored or gray.
 - Clean wounds, healed by first intention, are regular and thin.
 - Infected wounds heal by secondary intention and are irregular and wide.
 - Keloids develop as irregular scars with abundant hypertrophic fibrous tissue.
 - Surgical scars may show sinuses, fistulae and incisional hernias.

-
- Striae: stretch marks may be red, white or purple, seen in Cushing's syndrome, pregnancy, obesity and ascites.
 - Color: areas of rashes or discoloration.
 - Stretched or lax.
 - Fistulae.
 - Stoma. What type? Does it look healthy or abnormal? What is the content of appliance?
- c. Subcostal angle** is acute in normal individuals with variations. It is obtuse when there are conditions associated with chronic increase in the intra-abdominal pressure.
- d. Rectus abdominus muscles:**
- Head raising, leg raising, Valsalva's manœuvre.
 - Divarication of recti: Separation of the 2 muscles due to stretching of the linea alba by chronic increase in the intra-abdominal pressure e.g. repeated pregnancies and ascites.
- e. The umbilicus:**
- **It is the site of 4 fetal structures:**
 - 2 umbilical arteries → lateral umbilical ligaments
 - Umbilical vein → ligamentum teres.
 - Urachus is a tube extending between the bladder dome and umbilicus → median umbilical ligament.
 - **Urachal anomalies:**
 - 1- Urachal sinus.
 - 2- Umbilical fistula with ammoniacal discharge and dermatitis.
 - 3- Diverticulum in the bladder dome.
 - 4- Cyst.

- **Location:**

The umbilicus is equidistant between top of symphysis pubis and xiphisternum. It is displaced downwards by ascites and upwards by pelvic swellings.

- **Inflammation.**

- **Unfolding and protrusion:** Intestinal obstruction, ascites.

- **Secondary malignant infiltration.**

- **Umbilical hernia** comes through the center of the umbilical scar. Congenital or acquired. Congenital hernias are common in infants and generally close by 3 years.

f. Dilated veins:

- Engorged veins are seen in emaciation, portal hypertension and IVC obstruction.
- The normal venous flow is downward below the umbilicus and upward above it.
- In portal obstruction the direction is unchanged.
- Caput medusa → dilated veins radiating from the umbilicus in liver failure.
- In IVC obstruction, the flow below the umbilicus is reversed. This sign is noted in kidney cancer with a thrombus extending into the IVC.

g. Hair distribution:

- Secondary sexual hair appears at puberty in the face, axilla and pubic region.
- Facial hair is stimulated by androgens in women (virilism).
- Male hypogonadism and cirrhosis cause sparse hair.

- The normal female hair distribution in the pubic area is a triangle with the apex pointed to the perineum. In males the distribution is diamond with an upper tip pointing to the umbilicus.

h. Movements:

1) Peristalsis:

The peristaltic waves are increased in dynamic intestinal obstruction.

2) Pulsations:

Pulsations may be visible with each heart beat in cases of aortic aneurysm.

3) Movements with respiration: Abdominal wall moves in a symmetrical fashion with respiration. With peritonitis, there may be localized or generalized loss of this movement.

i. Hernia.

Hernia is defined as protrusion of a viscus in part or in whole through an abnormal opening in the abdomen.

- Hernia is obvious as a swelling which is easily reduced into the peritoneal cavity by pressure and returns by standing and coughing.
1. Inguinal hernia (Table 7): The commonest type of abdominal hernia.
 2. Femoral.
 3. Umbilical/para-umbilical.
 4. Incisional: defect in the abdominal wall after surgical operations.
 5. Epigastric: midline protrusion through a defect in the linea alba between the xiphoid process and umbilicus.
 6. Spigalean: herniation through the linea semilunaris (lateral to the rectus sheath).

- **Evaluation of hernias:**

- Determine the features: site, size, shape, tenderness, tension, temperature, and contents.
- Characteristics of the overlying skin.
- The presence of a cough impulse.
- Attempt reduction of the hernia.
- Percussion: Omentum is dull, bowel is resonant.
- Auscultation for bowel sounds.
- Examine the same site on the opposite side.

Table 7: Inguinal hernias

Indirect	Direct
Arises lateral to the inferior epigastric artery and protrudes through the inguinal canal	Medial to the artery through the posterior wall of the inguinal canal
Can descend into scrotum	Very rare
Reduces upwards, laterally and backwards	Reduces upwards and backwards
Remains reduced with pressure at internal ring	Not controlled
Reappears at the internal ring and flows medially	Reappears as before reduction
Narrow-necked	Wide-necked

j. Signs of trauma:

- Gunshot and stab injuries.
- Bruising.
- Hematomas.

k. Wound complications:**1- Postoperative bleeding:**

- **Arterial** hemorrhage from vascular anastomosis is rare. It is rapid, bright-red and pulsatile.
- **Venous** hemorrhage is more common and is due to opening of venous channels. It is non-pulsatile, low-pressure and dark.
- Bleeding may be contained within body cavities or evident through drains and catheters.

Causes:

- **Primary** hemorrhage occurs immediately after surgery or as a continuation of intra-operative bleeding.
- **Reactionary** hemorrhage occurs within the first 24 hours due to improved circulation.
- **Secondary** hemorrhage occurs up to 10 days after surgery due to wound infection.

2- Wound hematoma: A localized collection of blood in the wound leading to swelling and discoloration.

3- Wound infection:

- There will be fever, malaise, anorexia, pain and discharge.
- The wound is red, tender and swollen.
- It may be discharging pus or fluctuant due to the contained pus.

4- Wound Dehiscence:

Superficial: involving the skin and subcutaneous tissue. The subcutaneous fat and fascia are visible.

Deep: Involving the full thickness making the viscera visible.

Internal dehiscence e.g. anastomatic leakage causing enteric fistulae.

B. Auscultation

- Auscultation is not helpful in otherwise normal examination.
- Clinical context is more important.

1- Bowel Sounds:

Normal peristalsis produces bowel sounds as liquid and gas are passed through the intestine. Normal bowel sounds are intermittent, low-pitched and chuckling. There is a lot of variability in normal persons. Clicks and gurgles are noted every 5-10 seconds on average.

- Absent bowel sounds: peritonitis and paralytic ileus.
- Hyperactive sounds: diarrhea.
- Dynamic intestinal obstruction produces a classical tinkling like water being poured from one cup to another. In late cases, bowel sounds may be absent due to vascular compromise.
- The coexistence of intestinal colic and borborygmi (stomach growling due to prolonged hyper-peristalsis) may establish the diagnosis of obstruction of small intestine.

2- Arterial bruit:

- It is useful in evaluation of cases with possible reno-vascular hypertension.
- Renal artery stenosis: a high pitched sound analogous to murmur is checked a few cm above the umbilicus along the lateral edge of rectus muscle or in the costo-vertebral angle.
- Aortic aneurysm.
- Mesenteric artery stenosis.

3- Venous hum: liver cirrhosis

4- Friction rubs: grating sound with respiratory movement due to inflammation of peritoneal surface of an organ.

5- Succession splash indicates air and fluid in a cavity with shaking: normal in the stomach.

C. Palpation:

Light palpation:

- Tenderness:
 - Pain expression elicited by palpation :
 - Location: quadrant
 - Depth of palpation: Superficial or deep.
 - Patient response: mild or severe.
- Guarding:

Guarding is voluntary contraction of the abdominal muscles to avoid pain which tends to be generalized over the abdomen.

Causes: tenderness, fear, anxiety, examiner's cold hands.

Guarding disappears when the patient purposely relaxes the muscles.
- Rigidity or spasm (involuntary guarding): involuntary contraction of the abdominal muscles in response to peritoneal inflammation. It involves only the inflamed area.

Deep palpation:

a. Tender areas:

- Mc Burney's point: 1/3 of the way from the right anterior superior iliac spine to the umbilicus. Focal tenderness is seen in appendicitis.
- Murphy's sign: inspiratory arrest on right upper quadrant palpation suggestive of gall bladder disease.
- Rovsing's sign: patient experiences right lower quadrant pain as you press the left lower quadrant in appendicitis (cross palpation tenderness).
- Rebound tenderness: press deeply into the abdominal wall then quickly release pain results from peritoneal inflammation

b. Palpation of specific organs:**THE LIVER:**

- Start in the right iliac fossa and move gently up to the right hypochondrium.
- Support the last right ribs with your left hand posteriorly.
- Ask the patient to take a deep breath and try to feel the liver margin.
- Advance your right hand upwards and parallel to the rectus muscle and repeat until the costal margin.
- An over-distended gall bladder may form an oval mass below the liver margin.
- If palpable describe:
 - Size in cm below the costal margin.
 - Surface: Smooth or irregular.
 - Edge: smooth or irregular.
 - Consistency: tenderness, pulsations.

Hepatomegaly

- A mass descends from underneath the right costal margin.
- You cannot get above it.
- It moves with respiration.
- It is dull on percussion.
- It has a sharp rounded edge.
- Surface may be smooth or irregular.

THE SPLEEN:

- Normal spleen is not palpable. When enlarged, it grows inferiorly and medially.
- The left hand supports the costal margin.

- Palpate upwards from the right iliac fossa or umbilical area to the left hypochondrium till the costal margin asking for deep breath on the way.
- Get the patient to lie on the right side, facing towards you, and palpate up till the left hypochondrium.
- If you can feel the tip of the spleen it is significantly enlarged perhaps twice its normal size.

Enlarged spleen

- From underneath the left costal margin towards the right iliac fossa
- Firm.
- Smooth.
- Palpable notch in a sharp anterior border.
- Not possible to get above it.
- Moves with respiration.
- Dull on percussion.

PALPATION OF THE KIDNEYS:

- The left hand is placed posteriorly in the costo-vertebral angle (Fig. 8).
- The right hand is placed anteriorly just below the costal margin.
- Palpate deeply while the patient is taking a deep breath and the pulps of fingers of the 2 hands are approximated with expiration.
- Repeat for the left kidney.

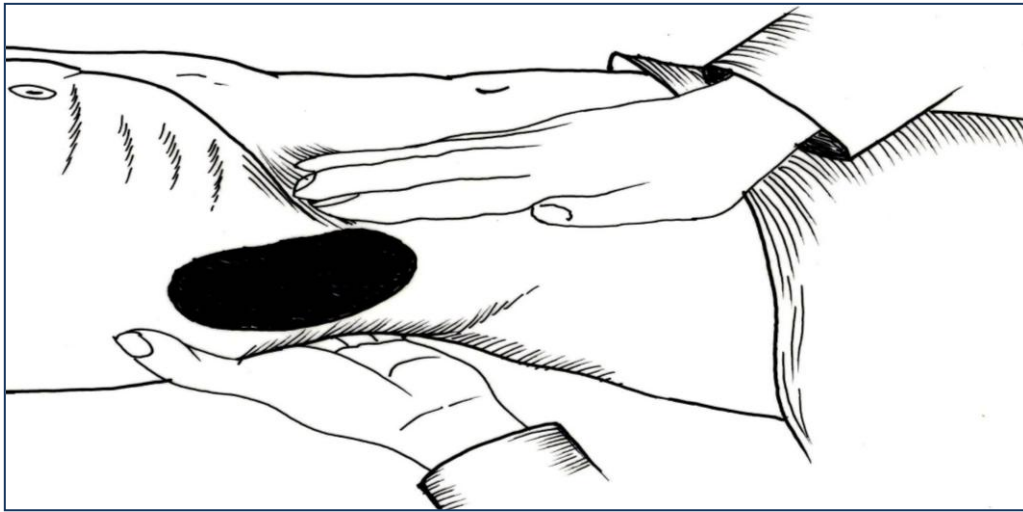


Fig. (8): Bimanual palpation of a right renal mass.

Renal mass:

- A swelling lies in the loin or can be moved back into the loin.
- Usually may maintain the original reni-form or bean shape.
- It moves with respiration.
- Ballotement: It is felt bimanually and can be balloted with 2 hands. Short, quick forward thrusts are made by the posterior hand lead to a bouncing sensation to the anterior hand.
- There may be a band of colonic resonance anteriorly.
- It is dull posteriorly.
- Differentiating splenomegally and an enlarged left kidney is shown in Table 8.

Features of some renal masses:

A. Hydronephrosis:

- Unilateral, large, bean-shaped, mobile mass.
- Well-defined border with rounded lower pole.
- Not tender unless infected.
- Boggy in consistency i.e. like a half-full cyst, and becomes tensely cystic if infected.

B. Polycystic kidneys:

- Bilateral, large, mobile masses.
- The mass is irregular with beaded nodular surface.
- Not tender except in cases of hemorrhage and infection.
- Firm in consistency.
- Uremic face.

C. Pyonephrosis:

- Unilateral mass of moderate size.
- Not a bean.
- Irregular, ill-defined border with nodulated surface.
- Tender and may be fixed due to peri-nephritis.
- Heterogeneous firm consistency.
- Patient looks toxic.

D. Kidney cancer:

- Physical examination may show palpable abdominal mass.
- The loin mass is irregular in shape.
- Feels firm or hard and usually not tender.
- Movement with respiration and ballottement are initially retained to be lost later.
- Palpable left supra-clavicular lymphadenopathy.
- New-onset, non-reducing varicocele.
- Bilateral lower limb edema.

PELVI-ABDOMINAL ORGANS:

- The most common cause of hypogastric mass in males is acute urinary retention.
- The urinary bladder:
 - Start above the umbilicus and work down.
 - Arises in the supra-pubic area.
 - Dull on percussion.
 - Pressure causes a desire to void.
- In females: uterine or ovarian swellings may cause visible, midline lower abdominal masses.

Table (8): Differentiating splenomegally and an enlarged left kidney

	Enlarged spleen	Left renal mass
Palpation	<ul style="list-style-type: none"> - Impossible to feel above. - Hand cannot be insinuated anteriorly 	<ul style="list-style-type: none"> - May feel above the mass
	<ul style="list-style-type: none"> - A notch on the anterior border 	<ul style="list-style-type: none"> - The inner surface is concave, the outer is convex
Direction of enlargement	<ul style="list-style-type: none"> - Towards the umbilicus 	<ul style="list-style-type: none"> - Inferiorly and lateral to midline
Movements	<ul style="list-style-type: none"> - Moves early on inspiration 	<ul style="list-style-type: none"> - Late
Ballottement	<ul style="list-style-type: none"> - Not ballotable 	<ul style="list-style-type: none"> - Ballotable
Percussion	<ul style="list-style-type: none"> - Dull to percuss 	<ul style="list-style-type: none"> - Band of resonance anteriorly due to bowel gas.

D- Percussion:

- Tapping over solid or liquid filled structure → dullness.
- Air filled → tympanitic e.g. stomach.
- Technique:
 - Middle finger of left hand firmly against abdomen.
 - Using flabby wrist action, hammer middle finger of the other hand down aiming for last joint.
 - Percuss lightly in the 4 quadrants.
- **Liver** (6-12 cm):
 - Start in chest below nipple in the right mid-clavicular line and move down to ascertain the upper margin. The liver is an area of dullness below the 6th rib in the mid-clavicular line.
 - The liver dullness is lower during inspiration and in emphysema. It is higher in obesity, hepatomegally, sub-phrenic abscess, ascites and pregnancy.

-
- Tone changes from resonant (lung) to dull (liver) to resonant (intestines).
 - Percuss upward in the same line from below the umbilicus to determine the lower border.
 - **Spleen:**
 - Located in the hollow of ribs.
 - Percussion over last intercostal space in anterior axillary line is normally resonant.
 - Dullness suggests splenomegaly.
 - **Stomach:**
 - Resonant epigastric area.
 - **Kidneys:** There may be a band of colonic resonance anterior to a renal mass. The renal angle (CVA) is normally resonant due to presence of gas in the colon. Dullness may be due to a loaded colon or the presence of a renal mass.
 - **Shifting dullness:**
 - Indicates more than 500 ml of ascitic fluid (Liver cirrhosis, carcinomatosis, congestive heart failure).
 - Intestines will float to surface.
 - Percussion detects air-fluid interface.
 - Change in position shifts point of interface.
 - Percuss from the umbilical area moving down towards one side, when the sound becomes dull, keep your finger and ask the patient to move on the opposite side. Allow fluid to sink and percuss again. If the region becomes resonant that is a positive sign.
 - **The urinary bladder:**
 - In case of acute urinary retention, the distended bladder may be visible. Percussion will determine the extent of fullness and is done from above down wards i.e. from resonant to dull areas.

Clinical Features of a Urologic Mass

S	Site	Level
		Location
		Landmarks
	Size	3 dimensions
	Shape	Borders
		Form
	Surface	
	Sensation	
	Skin surface changes	
C	Consistency	
A	Attachments	
L	Trans-illumination	
P	Pulsations	

Site

Size

Shape

Fixation

Fluctuation

Firmness

Texture

Temperature

Tenderness

A- Anatomy

1- Site

Location	Level	Landmarks
<ul style="list-style-type: none"> - Abdominal region - Pelvic - Penile - Scrotal 	<ul style="list-style-type: none"> - Intra-abdominal renal, adrenal - Parietal 	<ul style="list-style-type: none"> - Relations to bones and strategic points.

2- Size

- Volume \simeq Length x width x height/2.
- One dimension may be ill-defined.
- **Examples:**

Normal kidney: $12 \times 6 \times 3/2 \simeq 108$ mls.

Hydronephrosis: $24 \times 12 \times 6/2 = 884$ mls.

When each of the 3 dimensions is doubled, the resultant volume is increased 8 folds.

- **Normal prostate** is the size of a chestnut, 20 gm.
Enlarged prostate varies in size to simulate a lemon, a plum, an orange or a grapefruit.
 1+ enlarged about size of 25 gm, fills $< \frac{1}{4}$ rectal lumen.
 2+ enlarged about size of 50 gm, fills $\frac{1}{2}$ rectal lumen.
 3+ enlarged about size of 75 gm, fills $\frac{3}{4}$ rectal lumen.
 4+ Huge prostate > 100 gm difficult to feel the whole gland.

3- Shape

- Borders: - Homogenous: round, beaded, heterogeneous.
- Margins may be well delineated (liver, spleen) or ill-defined (malignancy).

- Form:

A- Preserved

- Kidney: bean: outer convex, inner concave.
- Testis: Oval
- Epididymis: Coma

B- Similar to a ball (globular) or an egg.

C- Irregular.

4- Surface

- Homogenous or heterogeneous.
- Smooth.
- Bossy (lobulated, regular, large bosses).
- Nodular (regular, small bosses).
- Irregular.
- Combinations.

5- Sensation

- Temperature.
- Tenderness.
- Crackling e.g. grating of multiple prostatic stones over each other.

6- Skin surface changes

- Inflammatory: redness, hotness, tenderness.
- Infiltrative.

B- Consistency

- The hand can be used as a model to assess consistency:
 - **Hard** as any bony prominence.
 - **Firm** as contracted thenar eminence.
 - **Indurated** as stretched extensor pollices.
 - **Boggy** as non- contracted thenar eminence.

- **Soft** as flesh or fatty areas and lobule of the ear:

Soft solid: no fluctuation.

Soft cystic: fluid fluctuation.

C- Attachments

1- Mobility:

- Attachments will determine the mobility or fixity of the mass.
- Normally, the kidneys move up and down with respiration as well as forwards and backwards within the surrounding fat. The bladder moves freely with filling and voiding. The prostate has limited forwards and backwards mobility during DRE.
- Fixity may be due to advanced malignancy or inflammation and adhesions.

2-Reducibility:

- Primary varicocele is reducible on recumbency while secondary varicocele is non-reducing.
- Hernias can be reduced by relaxation and applying pressure.
- Undescended testis may be replaced downwards.

D- Trans-illumination

- It has been replaced by ultrasonography which defines the lesions much better.
- Helpful in scrotal swellings.
- Translucency indicates clear fluid content of a hydrocele.
- It is lost if there is pus or blood.

E- Pulsations

Thrills, bruits and noises

- a- Aneurysms.
- b- Hypervascular tumors.
- c- Transmitted pulsations by a close relation to a large artery.

Examination of the Back

- The patient is examined while he is sitting and the two sides are compared. **There are 5 areas** (Fig. 9): the spines, 2 para-spinal muscular regions and 2 flanks (extension of lumbar areas).

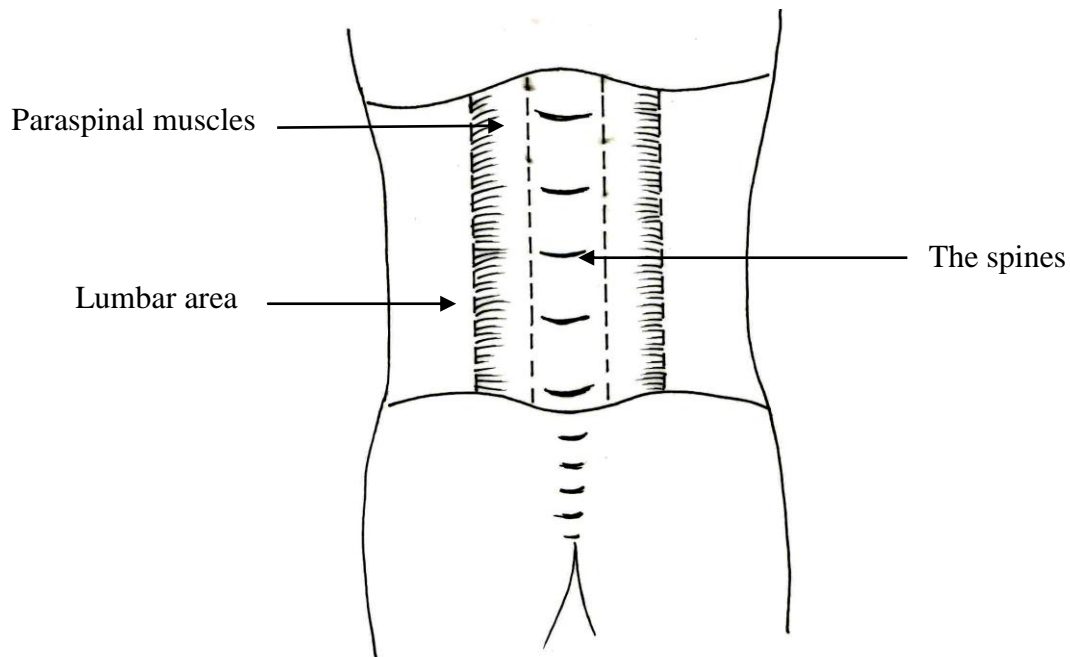


Fig. (9): Division of the back into 5 areas

A-Spinal region:

- Spina bifida: defect of the spino-laminar component of the vertebral column, commonly in the lumbosacral region. There may be an overlying hair tuft.
- Meningocele is a protrusion of meninges through a defect in the spino-laminar segment. The sac may contain the spinal cord and cauda equina (meningo-myelocele).
- Deformities (Kyphoscoliosis, scoliosis, kyphosis, lordosis).
- Pott's disease: tenderness.
- Scars of previous surgery: disc prolapse.

- Swelling.
- Fractured spine.
- Bed sores

B- Muscles of the back:

C- The costo-vertebral angle:

Inspection:

- Swelling or fullness of CVA.
- Signs of inflammation.
- Scoliosis.
- Search for a dimple over the lumbo-sacral area and palpate the sacrum in children with possible neuropathic damage.

Palpation: Murphy's kidney punch determines deep-seated tenderness (CVAT): The thumb is placed under the 12th rib and sharp jabbing movements are made.

Percussion:

- **Resonant CVA is a good negative sign.**
- **Dull CVA:**
 - Loaded colon.
 - Renal mass.
 - Peri-renal collection of fluids (Urine, blood, pus, or combination).

Examination of the Testis and Scrotum

THE SCROTUM

- A muscular out-pouching of the lower part of the anterior abdominal wall.
- Muscles of scrotum and spermatic cord contract and relax moving the testis closer or farther away from the body to control the temperature of the testis.
- Scrotal edema may be localized or a part of generalized edema: acute (insect stings, angioneurotic, trauma), chronic (heart failure, renal failure).
- **Fournier's gangrene (Necrotizing fasciitis):**
 - Acute scrotal inflammation:
 - Rapid onset of gangrene followed by sloughing.
 - Total absence of any of the usual causes of gangrene.
 - Fever, tachycardia and hypotension.
 - Crepitus, swelling and erythema.
- Sebaceous cysts are frequently seen in scrotum: multiple, small.
- Carcinoma: fungating mass or ulcer.
- The scrotal skin may be anchored anteriorly by gumma and posteriorly by tuberculosis of the testis.
- **Cremasteric reflex:**
 - Stimulus: light pinprick is applied to the medial thigh.
 - It tests segments L₁, L₂.
 - Response: homolateral contraction of cremasteric muscle with gradual elevation of the testis.
- **Scrotal reflex:**
 - Stimulus: stroking of perineum or by applying ice cube to scrotum.
 - Response: contraction of dartos muscle.

THE TESTIS

Palpate parts in a definite order Fig. (10).

1. The body of testis, compare with the opposite.
2. The tunica vaginalis is blended with the anterior surface.
3. The epididymis: head, body, tail.
4. Palpate the spermatic cord up to the external inguinal ring. Pass the thumb above and the next 2 fingers under the neck of scrotum and pinch the index finger down upon them. Slip fingers from within outwards.

Vas	Hard whipcord
Small cords	Cremasteric muscle
	Nerves
	Vessels

5. The external inguinal ring.

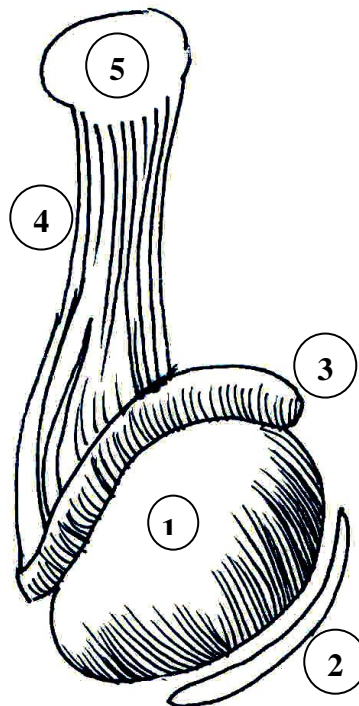


Fig. (10): Examination of the testis: (1) The body of testis, (2) The tunica vaginalis, (3) The epididymis, (4) The spermatic cord and (5) The external inguinal ring.

- **The normal testis:**

- **Site:**

The left testis is a bit lower than the right.

Both are intrascrotal with the long axis in a vertical direction.

- **Size:**

Both testes are normally equal in size, smooth and firm in consistency.

Vertical length = 4.5 x antero-posterior = 2.5 x transverse = 2 cm.

Obstructive azoospermia: high normal size.

Non-obstructive azoospermia: small, low normal volume.

- **Shape:** Ovoid organ.

- **Surface:** Smooth.

- **Sensation:**

Normal special testicular sensation is felt on gentle pressure and lost in testicular cancer.

- **Skin over it:** Freely movable.

- **Consistency:** Firm, homogenous.

- **Testis is freely movable and separable from the epididymis.**

- **Incompletely descended testis (Fig. 11):**

- The testis is arrested in some part of its path from the retroperitoneum to scrotum. An associated indirect inguinal hernia is often present.

Intra-abdominal.

In the inguinal canal: disappears if abdominal muscles contract.

In the external inguinal ring.

At the neck of scrotum.

- When both testes are impalpable the condition is known as cryptorchidism

- The corresponding hemi-scrotum is underdeveloped.

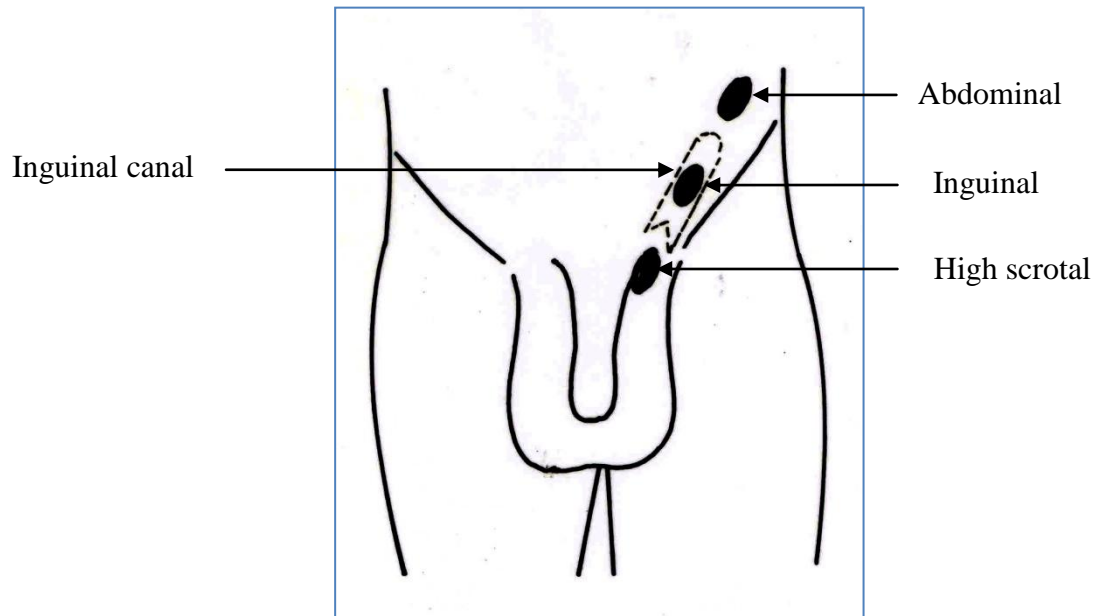


Fig. (11): Potential sites of incompletely descended testis: Abdominal, inguinal and scrotal.

- **The retractile testis:**

- Occurs in childhood due to an overactive cremasteric reflex when the skin of scrotum or thigh is stimulated.
- Can always be brought to bottom of scrotum by squatting or flexation of the thigh to abdomen (chair test) in a warm room Fig. (12).
- Scrotum is well-developed.
- Retractable testis is normal and requires no treatment.

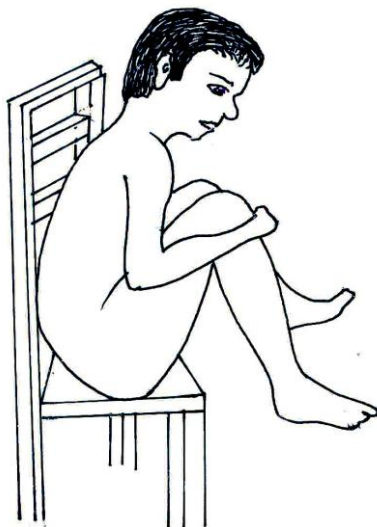

Fig. (12): The chair test

- **Ectopic testis:**

- Very rare.
- The testis is abnormally placed outside its path Fig. (13):
 - At the superficial inguinal pouch: subcutaneous, easily felt, bulges more if the abdominal muscles contract.
 - In the perineum.
 - At the root of the penis.
 - In the femoral triangle.
- The testis is usually well-developed but liable to injury.

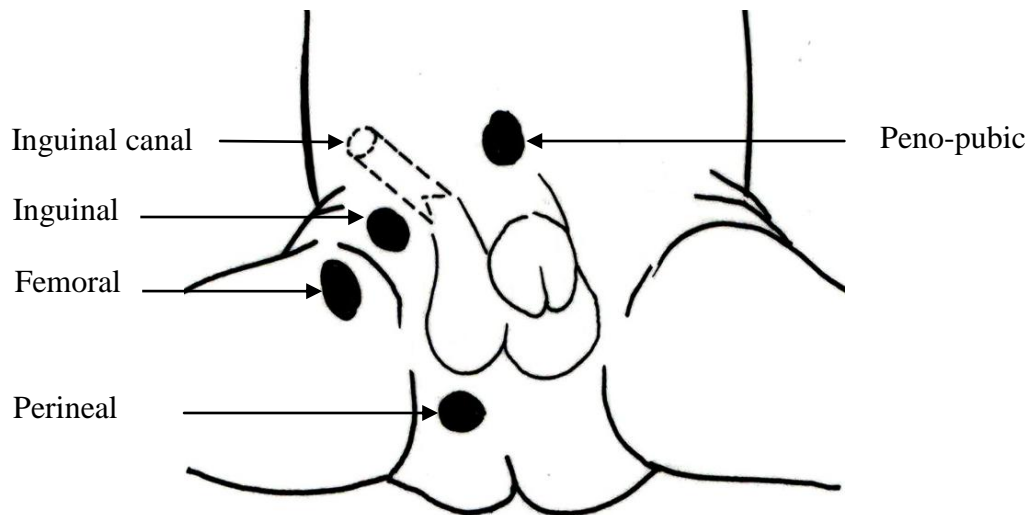


Fig. (13): Potential sites of ectopic testis: (1) Peno-pubic, (2) In the superficial inguinal pouch, (3) Femoral and (4) Perineal.

- **Torsion of the testis:**

- History:
 - Teenager around puberty, the most common peak age at 14.
 - It occurs less frequently during the first year of life.
 - Acute onset.
 - Awakening from sleep 80%.
 - Pain peaks immediately.
 - Nausea, vomiting.
 - Well last night.

50% history of similar episodes.

No recent urethral instrumentation.

No exposure or history of STDs.

- Physical examination:

No urethral discharge.

Normal external urethral meatus.

Swollen scrotal side, testis lies higher than its fellow.

Opposite side: transverse lie or upside down inversion instead of the normal vertical axis Fig. (14).

Prehn's sign negative i.e. ipsilateral scrotal elevation does not relieve pain in torsion. In epididymo-orchitis pain is relieved.

Ipsilateral absent cremasteric reflex.

Urinalysis is normal.

Differential Diagnosis of acute scrotal swelling is shown in Table 9.

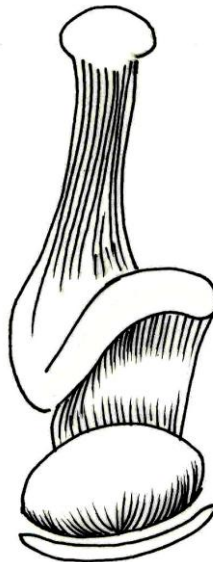


Fig. (14): Examination of the opposite testis in testicular torsion showing a transverse lie and a long meso-orchium

Table (9): Differential diagnosis of acute scrotal swelling

Features	Tumor	Epididymo-orchitis	Torsion
Etiology	Seminoma or non-seminomatous germ cell tumors (NSGCT)	Acute inflammation retrograde or blood-borne	Twisting of testis on cord
Age	20-40	Any, usually >20	12-18
Predisposing factors	- Unknown. - Undescended testis.	-Operations on prostate, urethra. -Post catheterization -Gonorrhea, mumps. -Idiopathic.	Long mesorchium and Horizontal lie of the contralateral testis.
Symptoms	Painless swelling. Sense of heaviness (30%).	Acute onset of pain, fever, rigors, dysuria.	Sudden severe pain swelling of testis.
Signs	Hard painless swelling with absent testicular sensation.	Swollen, red, tender testis, hydrocele, pain decreases with scrotal elevation urine: pus & organisms.	Testis is extremely tender and elevated. Opposite testis: bell clapper.
Ultrasound	Testis solid mass.	Normal or increased blood flow.	Absent blood flow if gangrenous.
Treatment	High inguinal orchidectomy. + Chemotherapy (NSGCT) Radiotherapy (Seminoma)	Bed rest, Antibiotics, Scrotal elevation.	-Detorsion and fixation within 8hrs. -Orchidectomy after 12hrs -Fixation of contralateral testis.

- **Atrophy of the testis:**

Torsion.

Mumps orchitis.

Epididymo-orchitis.

Following operations → vascular injury.

Inguinal hernia

Varicocele

Orchidopexy.

Varicocele.

Klinefelter's syndrome: bilaterally small testes.

Liver cirrhosis.

Estrogen therapy for prostate cancer.

- **Absent testis:**

- Undescended, carefully examine the inguinal canal for a discrete swelling.
- Surgical removal.
- Atrophied and missed.
- Congenital.

- **Impalpable testis:**

- Fluid prevents palpation:
 - Hydrocele
 - Hematocele
 - Lymphocele
 - Pus
 - Scrotal edema
- Bowel prevents palpation:
 - Incarcerated hernia.

- **Orchitis:**

- Inflammation of testis.
- The testis is high, swollen and tender.
- Overlying skin is red and hot.
- The patient is unwell and febrile.

- **Testicular tumor:**

- **Any mass in the testis must be considered to be malignant until proven otherwise, whereas all masses arising from the spermatic cord are benign.**

- **History:**

Cryptorchidism

Atrophy

Recent trauma 10%

Not always painless.

30% of patients have some pain.

- **Physical exam:**

Supraclavicular mass

Gynecomastia- unilateral or bilateral

Abdominal mass in the upper abdomen.

Abdominal, inguinal, pubic and scrotal scars.

Opposite testis

Extensive lymphadenopathy may result in lower limb edema.

- A firm intra-testicular progressively enlarging lesion.
- The testis is enlarged, smooth, firm.
- Later it is irregular, hard.
- Testicular sensation is lost.
- Reactive or secondary hydrocele 10%

- Local Staging:

T1	Tumor confined to testis
T2	Tumor beyond tunica albuginea
T3	Tumor is rete testis or epididymis
T4a	Tumor extends into spermatic cord.
T4b	Tumor invasion of the scrotum

Leydig cell tumors

- 90% are benign with frequent hormonal disorders.
- Prepubertal boys:
 - Precocious puberty.
 - Prominent external genitalia.
 - Masculine voice.
 - Hair growth.
 - Testicular mass.
- Adults:
 - Erectile dysfunction.
 - Gynecomastia.

Sertoli cell Tumor

- 80-90% of cases are benign with infrequent hormonal disorders.
- Age is around 45 years.
- It is suspected in cases of testicular mass with gynecomastia.

Secondary Tumors of the testis***Lymphoma:***

- Rare NHL, age above 50.
- Adenopathy may be present.
- Most common secondary tumor of testis.
- Most common bilateral tumor (50%).
- Usually a systemic disease.

Leukemia:

8% of children with ALL.

Diffuse testicular swelling.

Scrotal discoloration.

Bilateral in 50% of cases.

Metastatic:

Multiple testicular masses

Primary lesion may be prostate, lung, intestinal, kidney cancers.

HYDROCELE

Hydrocele is an abnormal collection of serous fluid in some part of the processus vaginalis, usually the tunica. The testis is impalpable hydrocele transilluminates Fig. (15).

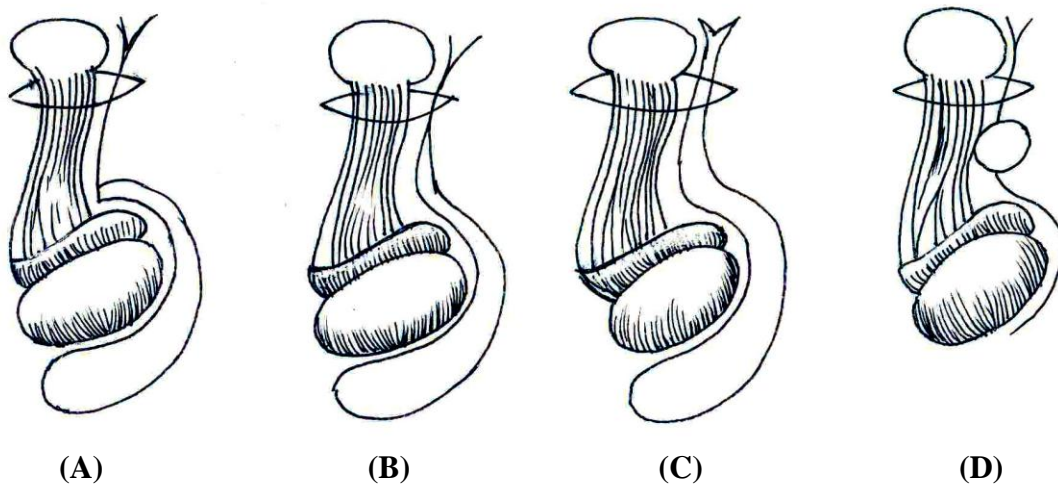


Fig. (15): Types of hydrocele: (A) Vaginal, (B) Infantile, (C) Congenital and (D) Hydrocele of the cord.

CONGENITAL HYDROCELE:

1. Vaginal hydrocele: very common.
2. Infantile hydrocele: the processus vaginalis is obliterated at the external inguinal ring.

3. Congenital hydrocele: The processus vaginalis is patent and communicating with the peritoneum. The swelling is reducing in recumbent position.
4. Encysted hydrocele of the cord.

ACQUIRED HYDROCELE:

- 1- Primary or idiopathic
- 2- Secondary to testicular disease:
 - Torsion.
 - Inflammation.
 - Trauma.
 - **Tumor:** 10% of testicular cancers manifest with an associated reactive hydrocele. Ultrasonography is useful to confirm.
 - Other

HEMATOCLE: Trauma, tapping of a hydrocele.

CHYLOCELE: Filaria.

THE EPIDIDYMIS:

It is a specialized collecting apparatus where spermatozoa are matured before travelling up the vas deferens. Normal epididymis is comma-shaped and 6 cm length.

Globus major (head) is up near the superior pole of the testis; body is posterior and globus minor (tail) is low.

Epididymitis:

- Age is the most important criterion to distinguish from torsion.
- Usually occurs in sexually active men after age 20.
- Enlarged, tender.
- Vas may be thickened.

- Testis indistinguishable.

Spermatocele:

- Mass in upper pole on top of testis.
- Variable in size.
- Firm.
- Transilluminates but not so brilliantly.
- Contains dead sperms.

Epididymal Cysts:

- May be bilateral.
- Any part of epididymis.
- Lobulated.
- Small.
- Harmless.
- Painless.
- Transilluminate.
- Posterior and separable from the testis which is normal.

Adenomatoid tumor of testis:

- Most common paratesticular tumor.
- Mass in lower pole.
- Painless solid mass.
- Older male.
- Not growing.
- Incidental.
- No history of epididymitis, cryptorchidism or trauma.
- Benign variant of mesothelioma.

Rhabdomyosarcoma.

Age is the most important criterion to distinguish from torsion.

Absent epididymis: Testis is present and normal.

Diffuse enlargement: after vasectomy.

Tuberculous epididymo-orchitis:

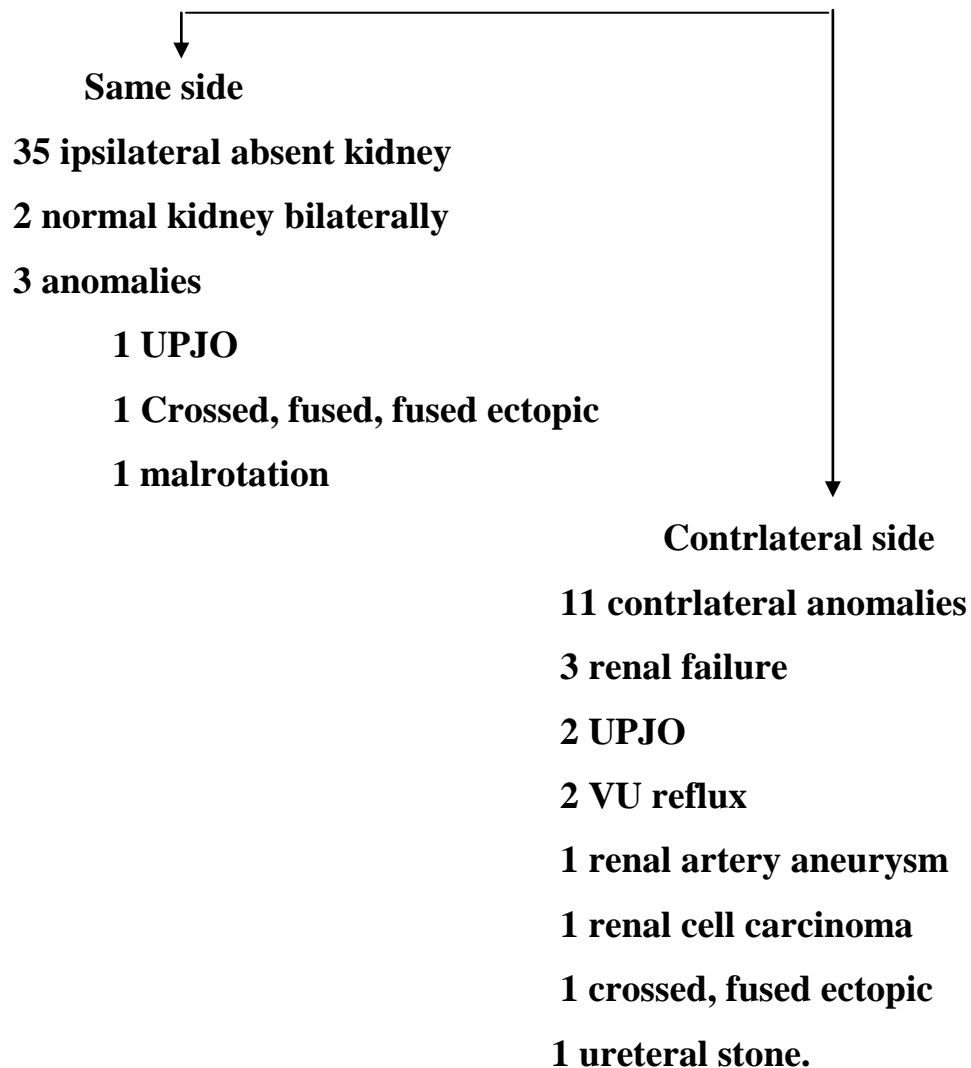
- Epididymis is thickened and craggy.
- Vas is considerably thickened with beading and irregular nodulation.
- The scrotum may be anchored posteriorly.
- Draining scrotal sinus.
- Nodular, tender prostate.

SPERMATIC CORD:

- Suspends the testis in scrotum and runs into the inguinal canal.
- Contains vas deferens, arteries, veins, and nerves.
- Surrounded by internal spermatic fascia from the transversalis fascia, cremasteric muscle and fascia from the internal oblique and external spermatic fascia from the external oblique aponeurosis.

Vas deferens:

- Normal: The vas lies along the posterior aspect of the cord and feels firm and wire-like. It runs from the epididymis to the external inguinal ring.

Unilateral Absence of the vas Deferens: 40 patients- Denver

- **Mass in vas bilaterally after vasectomy.**
- **Congenital Bilateral Absence of Vas Deferens (CBAVD)**
- No palpable vasa.
- Epididymal remnant is firm.
- Testes: normal size & consistency.
- Low-volume, acidic semen.

VARICOCELE:

Primary varicocele:

- Varicose dilatation of the veins draining the testis.
- Warm room, standing position and Valsalva's maneuver allow detection.
- Apparent when patient is standing and disappear or decrease in size when the patient lies down.
- Classification:
 - Subclinical: not palpable or visible. Reflux found upon Doppler examination.
Grade 1: Palpable during Valsalva maneuver only.
Grade 2: Palpable at rest, but not visible.
Grade 3: Visible and palpable at rest.
- 25% of adult males.
- Because of the greater hydrostatic pressure in the left testicular vein compared with the right, 95% of varicoceles occur on the left side.
- The ipsilateral testis is smaller in size in 25%.
- The pampiniform plexus feels like **a bag of worms**.

Secondary varicocele: Important in RCC with caval thrombus.

Patients with sudden onset of a varicocele, a right-sided varicocele or a varicocele that does not reduce in supine position should be suspected to have RCC with IVC thrombus on the right or a retroperitoneal tumor with obstruction of the spermatic vein on the left.

A comparison between primary and secondary varicoceles is enlisted in table (10). The possible signs in cases of kidney cancer are: cervical left supraclavicular lymphadenopathy, palpable renal mass, new-onset varicocele and bilateral lower limb edema. Dilated veins may be noted in abdominal examination.

Table (10): Comparison of primary and secondary varicocele

	Primary varicocele	Secondary varicocele
Age	Since puberty, early adults	Above 40
Onset	Chronic	Acute, new-onset
Symptoms	Asymptomatic Scrotal discomfort Infertility	Abdominal Pain Mass Hematuria
Side	Left in 95% of cases	Right in cases of RCC
Drain with gravity	Reducing	Non-reducing
Associated signs	Ipsilateral testis is smaller in 25% of cases	<ul style="list-style-type: none"> - Normal ipsilateral tests. - Palpable renal mass. - Bilateral lower limb edema. - Left supraclavicular nodes
Etiology	<ul style="list-style-type: none"> - Left testicular vein enters the left renal vein. - Incompetent valves. - Nutcracker compression of left renal vein between aorta and SMA. 	Consider compression of renal vein or IVC: <ul style="list-style-type: none"> - RCC- thrombus. - Testis cancer metastasis - Lymphoma - Retroperitoneal tumor

Value of examination of testis and scrotum in urologic disorders

- **Congenital**
 - Absent vas- absent ipsilateral kidney.
 - Undescended testis - hypospadias.
- **Inflammatory.**
 - UTI: complicated by epididymo-orchitis.
 - TB: beaded vas.
- **Traumatic.**
 - Hematoma & urinary extravasation.
- **Vascular.**
 - Secondary varicocele in RCC associated with IVC thrombus.
- **Neoplastic.**
 - Lymph node metastases of testis cancer may cause hydronephrosis.

Table 11: Findings in testis and scrotum in urologic disorders

	Pathology
Scrotum	<ul style="list-style-type: none"> - Hematoma - Urinary extravasation - Edema (Cardiac, hepatic or renal failure)
Testis & Epididymis	<ul style="list-style-type: none"> - Carcinoma - Infection
Spermatic Cord	<ul style="list-style-type: none"> - Hematocele - Hydrocele - Varicocele - Hernia - Absent vas

Examination of the Penis and Perineum

Inspection:

- Size of the penis.
- Shape.
- **Circumcised or not:** A circumcised man is not likely to have penis cancer and his wife is less likely to develop carcinoma of the cervix.
- Color of skin.
- Site and caliber of the urethral meatus: The normal meatus is a vertical slit at the tip of the glans.
- Any discharge.
- Any abnormal curvature.
- Any lesion:
 - Hematoma.
 - Ulceration.
 - Warts.
 - Sebaceous cysts.

Palpation:

- Put on a pair of gloves.
- The whole length.
- Retract the foreskin to examine the glans and meatus then replace it.
- Palpation of the male urethra. Open the urethral meatus by compressing the glans antero-posteriorly between your thumb and index finger, in order to inspect for discharge and ulcers.
- Palpation of the inguinal lymph nodes.
- Palpation of the perineum, elevate the scrotum: hematoma, urinary extravasation, abscess.

PHIMOSIS:

- Stenosis of the preputial opening preventing retraction of the foreskin and exposure of the glans.
- Insignificant in children and will resolve.
- Secondary to scarring such as balanitis xerotica obliterans and balanoposthitis.
- Chronic retention of urine may occur with ballooning of the prepuce resulting in a second bladder.
- May lead to chronic infection and carcinoma of the penis.
- Treatment: Circumcision.

PARAPHIMOSIS:

- The preputial skin is retracted and acts as a constriction ring.
- Iatrogenic: a complication of urethral catheterization if the foreskin is not replaced to its normal position..
- Lymphatic and venous drainage of tissue distal to the ring is impaired leading to edema and more constriction and necrosis of the glans.
- Treatment: Dorsal releasing incision and later circumcision.

BALANITIS: Inflammation of the glans penis.

Balano-posthitis: Inflammation of the glans and foreskin.

Causes:

- Candida albicans (diabetic patients).
- Herpes.
- Drug eruptions.
- Poor hygiene.
- Cancer.

PENILE ULCERS: (Table 12)

- Herpes simplex (vesicles followed by ulceration).
- Syphilis: non-tender ulceration.
- Malignancy: Squamous cell carcinoma is non-tender.
- Behcet's syndrome.

Table (12): Ulcers of the Penis

	Etiology	Features	Pain	Lymphadenopathy
Genital herpes	<i>Herpes simplex virus</i>	Multiple vesicles → papules→ pustules→ ulcers. Primary: Systemic symptoms. Recurrent: Localized ulcers.	Yes	No
Syphilis	<i>Treponema pallidum</i>	Single ulcer (chancre)	No pain unless infected	Bilateral
Chancroid	<i>Hemophilus ducreyi</i>	Multiple ulcers.	Tender	Bilateral
Lymphogranuloma venereum	<i>Chlamydia trachomatis</i>	Single small vesicle ulcerates.	Not usual	Unilateral, painful (masses, abscesses, fistulae) → Bubos
Granuloma inguinale (Donovanosis)	<i>Calymmatobacterium granulomatis</i>	Single, progressive, beefy-red, highly vascular ulcer. Likely to be inguinal.	No	No
Penile cancer	<i>Squamous cell carcinoma</i>	Single.	Not initially painful	Infected and/or metastatic

HYPOSPADIAS:

- 1- Location and caliber of the external urinary meatus on the under-surface of the penis:
 - Glandular: the most common.
 - Penile.
 - Perineal.
- 2- Downward penile curvature: chordee.
- 3- Distal foreskin: circumcised or not.
- 4- Penile size.
- 5- Undescended testis, cleft scrotum in proximal hypospadias.
- 6- Inguinal hernia.

EPISPADIAS:

- The urethral opening is above the corpora cavernosa on the dorsal surface of the penis.
- When penopubic or associated with ectopia vesicae, urinary incontinence occurs.

FIXED DRUG ERUPTION:

- Cutaneous eruption that can be reproduced at the same site by the same drugs.
- Causes: Sulphonamides, Allopurinol, Salicylates, Tetracyclines, Phenacetin, Hypnotics, Phenolphthalin.
- Genital lesions are usually solitary, well-defined in the glans penis and shaft. They may be bullous and subsequently ulcerate. Repeat exposure may lead to hyperpigmentation of the same site.

CARCINOMA OF THE PENIS:

- Unknown in Muslims and Jews.
- Seen in people who don't practice circumcision.
- Delayed presentation >1y (embarrassment, fear, ignorance).

- Two forms:
 - a) Hard painless papilliferous mass.
 - b) Ulcerative with indurated base.
- Local infection is common causing evil-smelling discharge which later becomes blood-stained.
- Concomitant balanoposthitis.
- Enlarged inguinal lymph nodes: inflammatory or infiltrative (fixed or even ulcerating).

PRIAPISM: (Table 13)***Low-flow (ischemic priapism):***

- **P**ersistent or **p**rolonged (>4hours), **p**ainful, **p**urposeless (in the absence of sexual stimulation) **p**enile erection.
- More common.
- Cavernosal blood gas analysis shows hypoxia and acidosis due to ischemia of corpus cavernosa and veno-occlusive mechanism ($pO_2 < 30$, $pCO_2 > 60$, $pH < 7.25$).
- There is a rigid mildly tender penis while the glans and corpus spongiosum are flaccid.

High-flow (non-ischemic priapism):

- Prolonged, painless penile erection due to upregulated arterial blood flow secondary to post-traumatic AVF.
- Cavernosal blood gas analysis is similar to arterial blood.
- The penis is semi-rigid.

Table (13): Types of priapism

	Low-flow priapism	High-flow priapism
Etiology	Primary: idiopathic. Secondary - Intracavernosal injections. - Drugs - Thrombo-embolic: Sick cell disease, leukemia, thalassemia. - Neurogenic - Infection. - Malignancy: bladder, prostate.	<ul style="list-style-type: none"> • Non ischemic • Penile or perineal trauma → AVF → ↑ arterial flow.
Features	Painful Cavernosal rigidity	Painless Semi-rigid penis.
Cavernosal blood gases	Hypoxia, acidosis	Arterial pattern
Doppler US	Reduced blood flow	Ruptured artery and pooling of blood around.
Treatment	<ul style="list-style-type: none"> - Cavernosal aspiration and irrigation. - Intracavernosal injection of α-adrenergic agonist (Phenylephrine). - Sicklers: alkalization, hydration, oxygenation, analgesia and hematologist referral. - Corporal shunts: distal (Al-Ghorab) or proximal 	<ul style="list-style-type: none"> - Early: cool bath. - Selective embolization of the internal pudendal artery.

PENILE FRACTURE:

- Trauma to the erect penis.
- Tear of the tunica albuginea, surrounding the corpora cavernosa, followed by penile detumescence and ecchymosis.
- Urethrography in suspected urethral injury.

PEYRONIE'S DISEASE:

- Curvature of the penis secondary to formation of fibrous plaques within the tunica albuginea.
- Clinical features:
 - Pain and curvature during erection.
 - Erectile dysfunction.
 - Hard plaques on the penis.
 - Shortening of penis.

- Associated conditions:
 - Dupuytren's contracture.
 - Plantar fascial contractures.
 - Previous penile trauma.
 - Diabetes mellitus.
 - Arterial diseases.

URETHRAL DISEASES: Urethral palpation for tenderness, indurations, stone, stricture, foreign body:

Gonorrhea:

Urethral discharge: Profuse, purulent

Reiter's syndrome: Classic triad:

Urethral discharge: Purulent

Arthritis: Peripheral joints

Conjunctivitis: Red eye

Urethral trauma: (Table 14)

Table (14): Features of urethral injuries

Features	Rupture Posterior Urethra	Anterior Urethra
Mechanism	Pelvic fracture	Falling astride
Blood at external urethral meatus	Minimal but evident on underclothes.	Profuse
Bleeding	-Perineum shows no signs of bleeding hematoma and bruising -Excessive pelvic hematoma above the pelvic diaphragm may lead to shock	Excessive perineal hematoma
DRE	-High- riding prostate or a boggy mass. -Blood if there is rectal injury.	Free
Associated injuries	Head, thorax, abdomen, long bones	
Management	- Diagnosis: Retrograde urethrogram - Discourage urethral catheterization - Diversion of urine by suprapubic catheter	

Stricture: Usually not felt.

Urethral carcinoma:

- Blood discharge.
- Localized indurations or masses.
- Retained urethra after cystectomy.
- Palpable inguinal lymph nodes (20%).

Urethral Diverticulum:

- May follow hypospadias repair.
- Pouch on the under-surface of penis.
- Apparent more during urination.
- Soft swelling.
- Pressure: Urine or turbid fluid expressed through the meatus.

EXAMINATION OF THE PERINEUM:

- The perineum is the area between the anus and the scrotum and the base of the thighs
- The scrotum should be elevated for proper evaluation:
 1. Hematoma in ruptured urethra.
 2. Bulbous peri-urethral abscess is mostly a complication of a urethral stricture.
 3. Abscess of the bulbo-urethral (Cowper's) gland.
 4. Watering-can perineum and scrotum in neglected urethral stricture and schistosomiasis.

PERI-ANAL SENSATION.

Acute central disc herniation causes saddle anesthesia.

Anorectal Examination

- Anorectal examination is an essential part of physical assessment of a urologic patient.
- It can be an extremely painful or a painless according to the skill and patience of the examiner.
- Ensure privacy of the examination.
- Remember: if you don't put your finger in it, you may put your foot in it!!
- Emptying the bladder before DRE is helpful.
- The possible limit of digital rectal examination (DRE) is 10 cm.
- Equipment: chaperone, non-sterile gloves, tissues and lubricating jelly.
- The patient is handed some tissue paper for later use at the end of the examination.

1- Positioning the patient:

A. Dorsal position:

- Patient is semi-recumbent with flexed knees.
- Convenient to the patient and urologist.
- Bimanual examination is done easily.

B. Lithotomy position:

- To perform bimanual examination under anesthesia, cystoscopy and biopsy.
- Helpful also in difficult clinical situations e.g. obesity.

C. The knee- elbow position:

- The prostate is decongested and changes in its consistency are easier to palpate.

D. The left lateral (Sims's) position:

- The left leg is lower and semi-extended while the right one is upper and flexed.

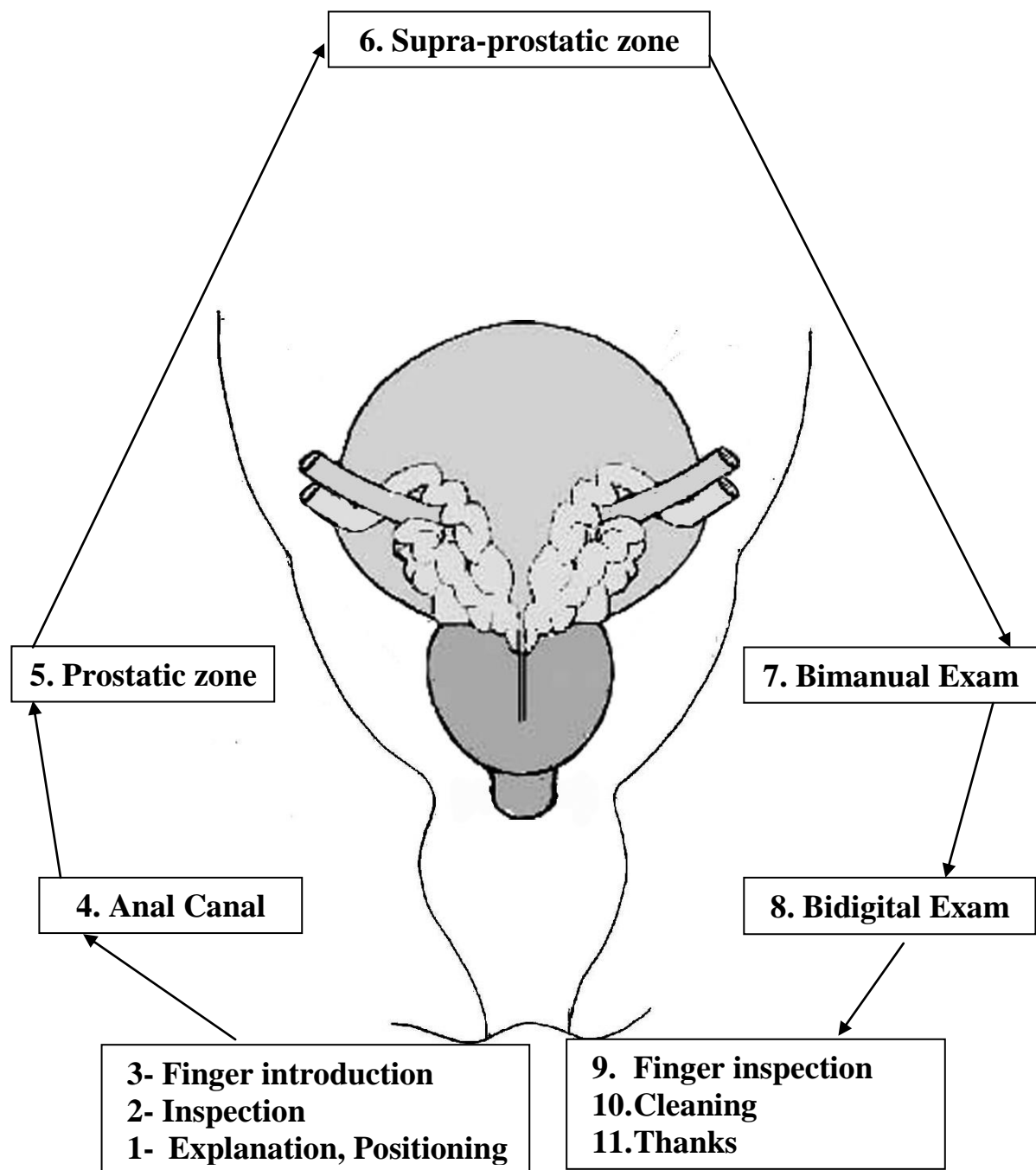


Fig. (16): Steps of anorectal examination in the male.

- The buttocks project over the edge of the table and the trunk should be across the couch.
- The steps of anorectal examination in the male are shown in Fig. 16.

2- Inspection of the anal verge:

- It is important to guide the examining finger and observe:

A) Closure of the anal verge.

B) Corrugations.

C) Anal reflex: Contraction of the external anal sphincter in response to painful stimuli nearby e.g. pin scratch. It checks S2-4.

D) Local pathology:

Piles:

- Prolapsed internal piles.
- Straining with relaxation of the external sphincter may show internal piles.
- External piles covered with skin.

Rectal prolapse.

Cutaneous tag marks the distal end of anal fissure.

Anal fistula: An opening is seen and felt as a small elevation.

Abscesses, fecal soiling, blood, mucus.

Imperforate anus in neonates is associated with recto-urethral fistula in boys.

3- Finger introduction:

- Explain what you are about to do and ask permission: I will examine the back passage without hurting you. Open your mouth and breathe quietly in and out during the procedure.
- Generous lubrication of the gloved index finger. It might feel cold.
- Use the little finger in children.

- Put the pulp of the finger on the anal verge and rotate with gentle pressure until the sphincter is felt to relax. Most sphincters reflexly tighten when touched but quickly relax with continued pressure. If the patient experiences severe pain on pressure consider: anal fissure, abscess, ulcer, thrombosed piles or prostatitis. You may need local anesthetic gel to proceed.
- Introduce the finger slowly, gently and stepwise: the first phalanx examines the anal canal, the second to palpate the prostate and the third to assess the supra-prostatic zone. This might feel a little uncomfortable.

4- The anal canal:

c) The canal walls:

- The anal canal, in adults is 2-3 cm, in length.
- Felt as a groove between the external and internal sphincter muscles.
- Anal fissure: DRE is contraindicated because of spasm of the sphincter and severe pain.
- Internal piles can be felt when thrombosed or engorged.

d) Sphincter integrity:

- Absence of normal resistance to finger introduction and laxity or diminished anal tone indicate:
 - Neuropathic damage
 - Local iatrogenic injury of the sphincter
 - Senility.
- Assess the anal tone by asking the patient to clench your finger.
- Ability of the patient to squeeze your finger with the anal sphincter indicates spinal cord integrity.
- Spasm of the sphincter is seen in neuropathic damage.

e) Bulbocavernous reflex (BCR) is elicited by squeezing the glans penis or clitoris or by gentle pulling on an indwelling urethral catheter. The normal response includes contraction of the anal sphincter and bulbocavernosus muscles. Positive BCR indicates that the afferent and efferent nerves of the sacral spinal cord (S2-4) and the sacral are intact.

f) The anal summit:

The anal canal commences where the rectum passes through the pelvic diaphragm and ends at the anal verge.

The junction between the rectum and anus is felt as a thickened ridge or ring. The posterior and lateral parts of the ring are felt easily because of the puborectalis.

Following examination of the anal canal the finger is introduced to palpate the rectum observing the following anatomical areas:

A- Anterior wall (prostate, seminal vesicles, recto-vesical pouch and urinary bladder).

B- Right lateral wall.

C- Left lateral wall.

D- Posterior wall (hollow of sacrum, coccyx).

Examine all 360° by moving the finger in sweeping motions. Note irregularities in rectal wall, presence of palpable feces and any points of tenderness.

Possible rectal pathology to palpate are polyps, stricture, malignancy and anorectal abscess.

5- The prostatic zone:

Next, in the male identify the prostate gland.

A) As a whole for shape, size, outline, consistency, symmetry and sulci.

B) Each lobe for shape, surface and sensation.

C) The para-prostatic gutters.

DRE is crucial in diagnosis of prostatic disorders Table (15).

The Normal Prostate:

- The posterior aspect of the prostate is palpated.
- It is felt as a chestnut or walnut size and shape.
- Like an inverted pyramid, the widest base is superior at bladder neck (transverse diameter 4 cm) while blunt apex is the lowest part. The vertical length is 3 cm and the postero-anterior is 2 cm. The upper border is felt as a transverse groove.
- The gland is divided between posterior urethra (median furrow or sulcus) and two lateral sulci into two equal triangles.
- The 2 lateral sulci (the antero-lateral angles of the rectum with the prostate) are normally obtuse.
- The rectal mucosa is sliding over it.
- Consistency is symmetrical and rubbery (like the thenar eminence when the thumb is opposed to fifth finger).
- Prostate is soft solid or mushy if congested due to lack of intercourse or in chronic infection with impaired drainage.

BPH:

- A disease of old age characterized by regular ballooning of lateral lobes.
- Edges are rounded.
- Sulci are obviously acute deep or exaggerated.
- The rectal mucosa is moving over it.
- As the prostate enlarges, the anterior rectal wall is pushed backwards.
The degree of rectal bulging of the prostate is proportional to the increase in size: mild BPH 1-2 cm, moderate 2-3, huge >3 cm.
- The prostate retains its normal limited mobility.
- Consistency is firm elastic and homogenous.
- The findings are consistent with a regular generalized enlargement with preservation of shape and exaggeration of sulci.

Prostate cancer:

- Most of prostate cancers begin in the posterior lobe (peripheral zone) and are very accessible during DRE (Fig. 17).
- It may occur primarily or on top of a pre-existing BPH.

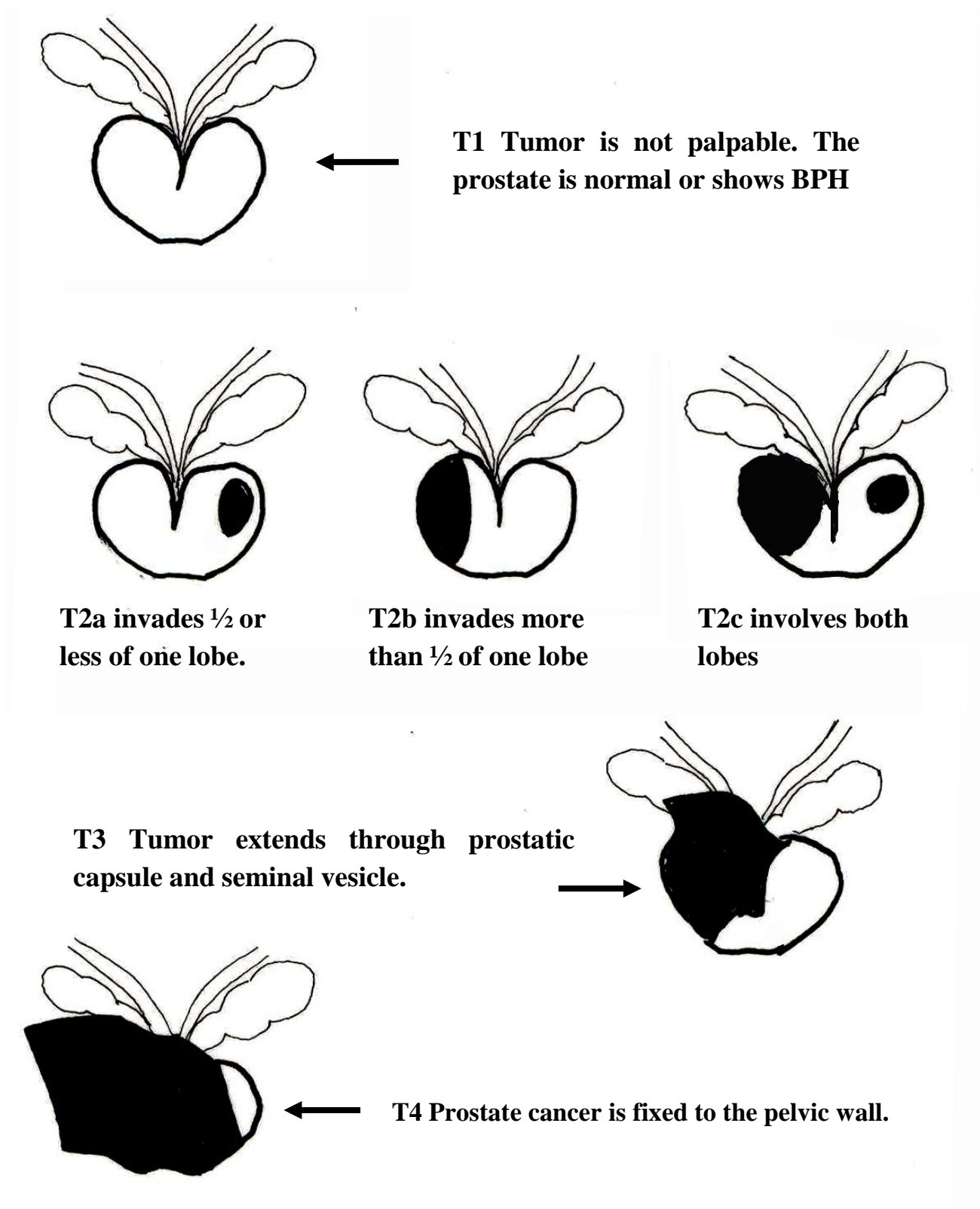


Fig. (17): Anorectal examination in patients with prostate cancer.

- DRE depends on stage.
- Prostate cancer arises as a peripheral hard nodule in the posterior lobe and the gland feels irregular and asymmetrical (T_2) as shown in Fig. (18, 19).
- Sulci may be obliterated and tumor may extend through capsule into seminal vesicles (T_3).
- T_4 tumors are fixed to pelvic wall or invading adjacent structures.

Table (15): Features of prostate by DRE in health and disease

Feature	Normal prostate	BPH	Prostate cancer
Site	prostate is palpable pelvic organ in front of the lower rectum		
Shape	inverted pyramid	generalized enlargement preserved shape	according to stage irregular enlargement
Size	chestnut	mild, moderate or marked	variable
Sulci	one median/ and two lateral	exaggerated/ or deep	obliterated
Rectal mucosa	Sliding	sliding	moving except late
Consistency	rubbery, homogenous	firm elastic, homogenous	rocky hard, heterogeneous
Mobility	little, variable	little	T_4 is fixed

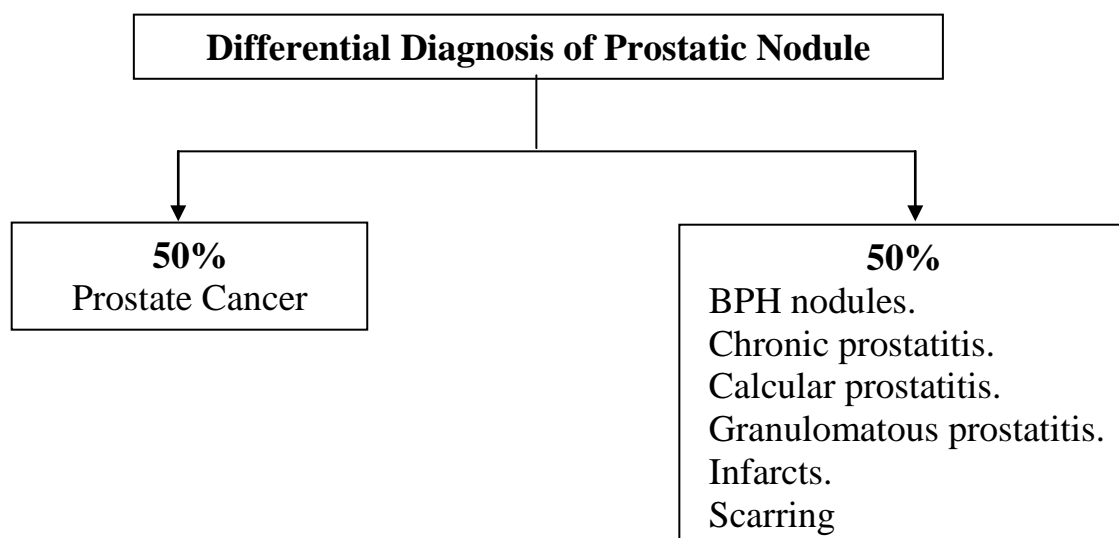


Fig. (18): Differential Diagnosis of Prostatic Nodule

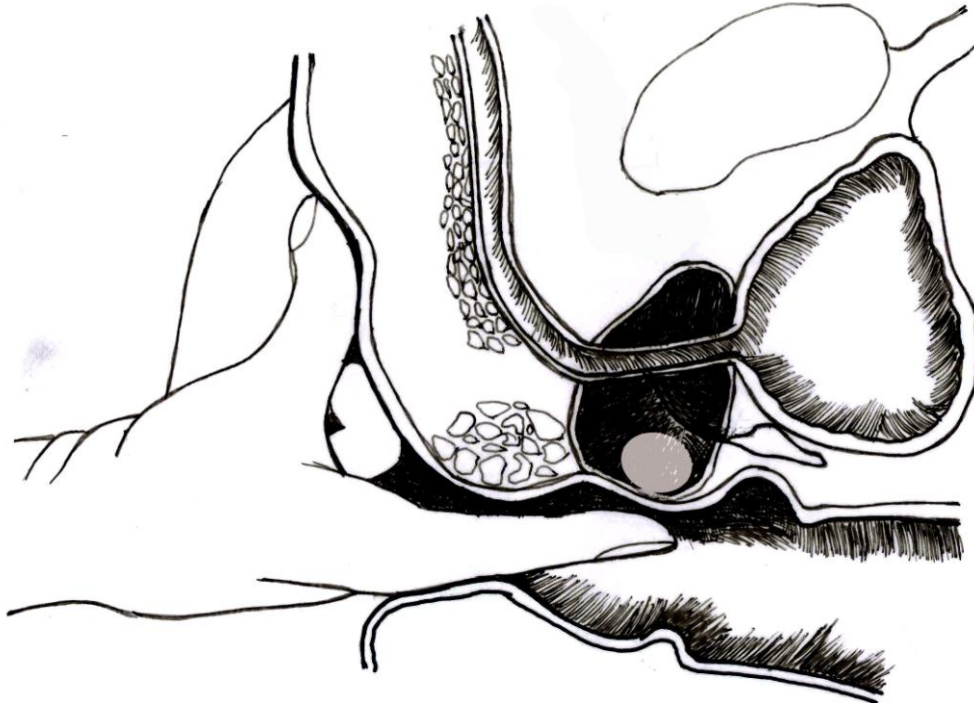


Fig. (19): Digital rectal examination of the prostatic zone.

Acute Prostatitis:

- Dysuria, perineal pain, urine retention, urethral discharge, fever/chills, tenesmus.
- DRE must be very gentle.
- The prostate is enlarged, tense, tender and hot.
- Abscess is felt as an area of softening, bogginess or fluctuation.

Chronic Prostatitis:

- Size: normal or slightly enlarged.
- Tenderness: Absent or slight.
- May be indurated, show some nodules, or boggy spots.

Tuberculous Prostatitis:

- The prostate is hard, irregular and nodular.

- Seminal vesicles are involved similarly.
- Vas deferens is thickened and beaded.
- Ask the patient to bear down (Valsalva's maneuver) to check the farthestmost rectal mucosa for masses.

Prostatic Calculi

- Irregular hard prostate when the stones are peripheral.
- Free stones are felt as "beads in a bag" giving the crackling sensation.

Rupture Posterior Urethra

- In cases of fracture pelvis and rupture posterior urethra, the prostate is high-riding with a soft boggy mass in its place.
- Blood in the rectum indicates concomitant rectal injury.

6. The supra-prostatic zone:

- This area is evaluated by full finger introduction during DRE and completed by bimanual examination.
- When the patient is obese or the prostate is markedly enlarged, palpation will be difficult.
- Palpation will assess:

The urinary bladder

The seminal vesicles.

Recto-vesical pouch.

The urinary bladder:

- The normal bladder and seminal vesicles are not palpable.
- The supra-prostatic zone is felt as an empty area unless the bladder is full.

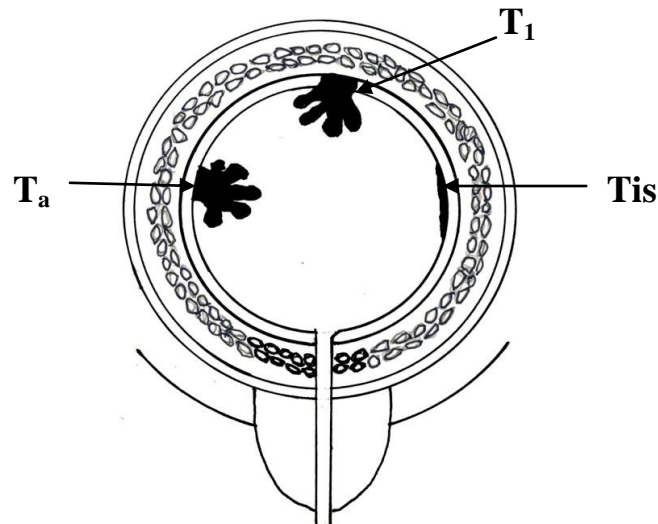
- Carcinoma of the bladder is the most common cause of a palpable mass felt from the posterior wall by DRE and from the anterior wall and dome during bimanual examination.

The seminal vesicles:

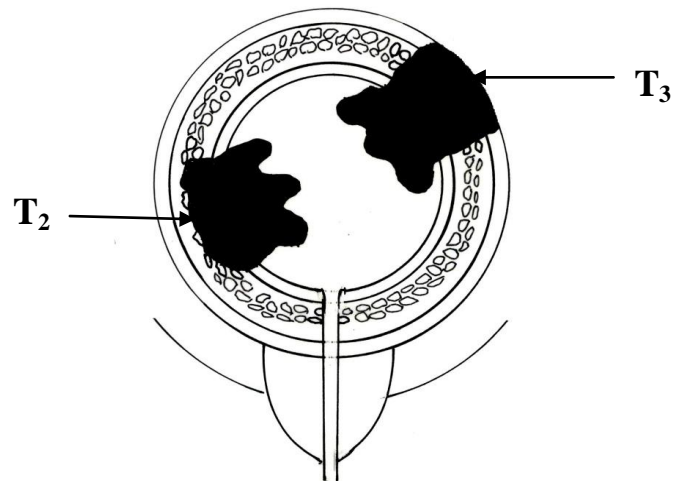
- They are enlarged and palpable as a result of chronic inflammation and obstruction.
- They show a characteristic craggy sensation in tuberculosis.

7. Bimanual examination (Fig. 20, 21):

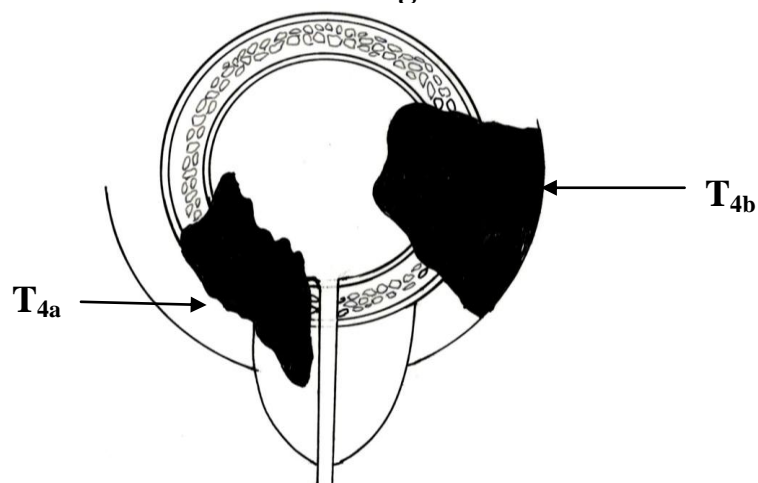
- With a finger in the rectum and the other hand on the lower abdomen.
- Best performed under anesthesia.
- It is important to evaluate a bladder mass. Ta and Tis are not felt. T1 is generally not palpable, but occasionally felt as a mouse mobile within the bladder. T2 and T3 are felt as a 3-dimensional mass mobile with the bladder. T4 indicates involvement of the adjacent organs or a fixed mass.
- Mobility/fixation of pelvic organs is the most important information gained.
- Ask the patient to bear down (Valsalva's maneuver) to check the farthestmost rectal mucosa for masses.



Bimanual examination: Non-muscle invasive bladder tumors (T_a , T_1 , T_{is}) are not palpable.



Bimanual examination: bladder tumor invading the muscle (T_2) or perivesical fat (T_3) are felt as a 3-dimensional mass, induration or thickening.



Bimanual examination: bladder tumor invading the prostate (T_{4a}) or a mass fixed to the pelvic wall (T_{4b}).

Fig. (20): Bimanual examination in patients with bladder cancer

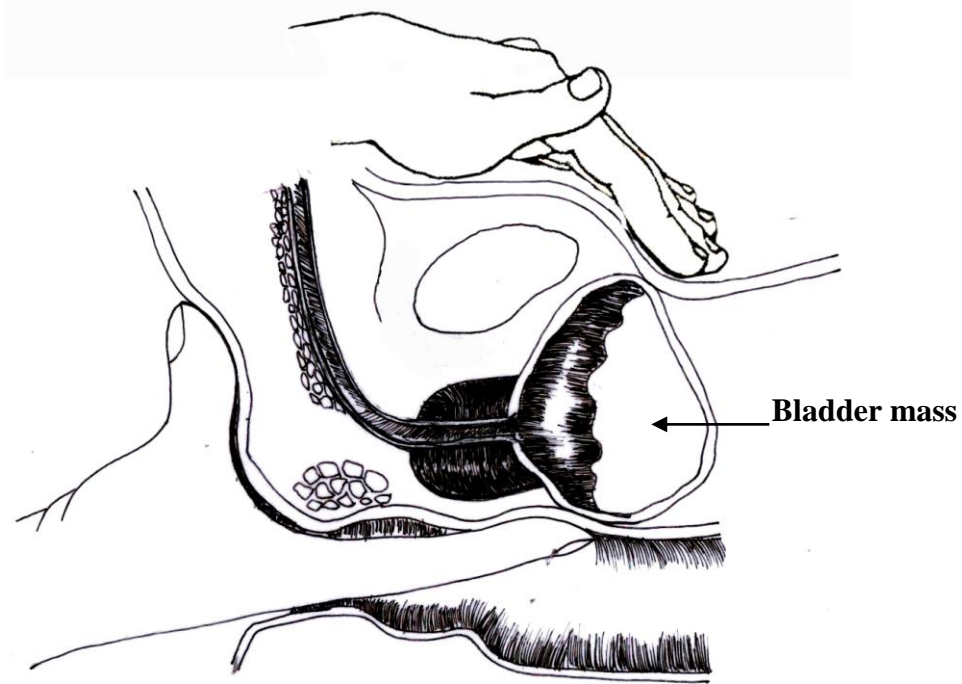


Fig. (21): Bimanual palpation of a bladder mass in the male.

The internationally agreed system for staging of urologic tumors is the TNM classification. Staging may be either RADIOLOGICAL OR PATHOLOGICAL.

Radiological staging is a preoperative tool for planning for surgery and neoadjuvant treatment.

Pathological staging is performed on surgical specimens and used to plan adjuvant treatment and is important to inform about prognosis.

Staging by clinical examination is **not recommended** because of under- and over- estimation of the extent of the disease.

8. Bidigital examination (Fig. 22):

- Cowperitis: inflammation of the Cowper's gland.
 - The index finger is in the rectum and the thumb of the same hand on the perineum.
 - The tissues in between can be palpated.
 - Acute infection: severe pain.
 - Chronic infection: the gland is enlarged and hard.
- Bidigital palpation detects the indurations around an anal fistula which feels like a whip-cord.

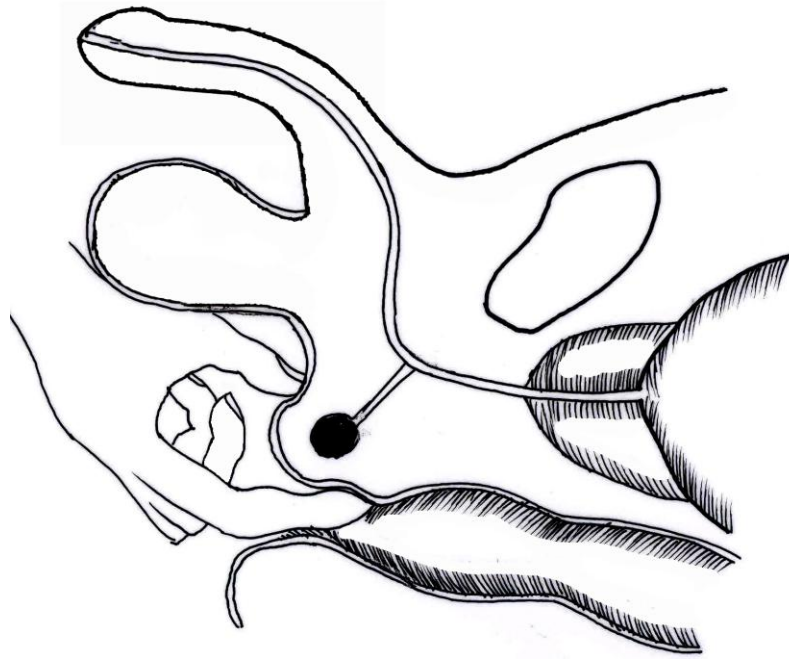


Fig. (22): Bidigital anorectal examination to assess Cowper's gland enlargement.

9. Withdrawn finger inspection:

- When DRE is completed, look at your finger for blood, mucus, or pus according to the local anorectal pathology. In fracture pelvis, with posterior urethral rupture, rectal injury may coexist.

10. Cleaning:

- At the end of anorectal examination, wipe the lubricant or any feces with tissues or ask the patient to do so. Otherwise, he will be extremely uncomfortable when dressed.

11. Thank the patient and ask him to redress. You may need to help.

Vaginal Examination

- Male urologists should perform
- The vaginal examination with a female nurse while the patient is in the lithotomy position.

A- Inspection:

- 1- The external genitalia and introitus are examined. Does the vaginal introitus look normal? Is there a vaginal prolapse? Are there scars of previous surgery, sinuses or other lesions? Possible causes of dysuria: atrophic changes, erosions, ulcers, discharge and warts.
- 2- The urethral meatus is inspected for:
 - Size and location.
 - Caruncle: a benign, erythematous, tender lesion arising from it.
 - Mucosal prolapse and cysts.
 - Urethral tumor: bloody spots.
- 3- Valsalva maneuver:
 - Cystocele: prolapse of the bladder.
 - Rectocele: prolapse of the rectum.
- 4- Coughing may precipitate stress urinary incontinence.

B- Palpation:

- 1- The urethra is examined for indurations (a sign of chronic inflammation or malignancy) or the presence of a diverticulum that gives purulent discharge on pressure.
- 2- Vesico-vaginal fistulae are better evaluated in the Sims's position.
- 3- Bimanual examination:
 - With 2 fingers in the vagina and the other hand on the lower abdomen, the bladder, uterus and adnexae are palpated.

- Is the cervix present and normal? Is the vagina of normal caliber and sensation? Is there tenderness in the vaginal fornices?
- Any abnormality anterior to the cervix denotes an affection of the bladder or pelvic connective tissue, while posterior abnormalities are in the Douglas pouch.
- Important findings in the genital tract may be palpated:
 - Carcinoma of the cervix.
 - Fibroid.
 - Ovarian cyst.
 - Carcinoma of the uterus.

Basic Urology

Egypt 2011