

Basic Clinical Urology

History Taking & Physical Examination

Editor

Atallah Ahmed Shaaban

Professor of Urology
Faculty of Medicine
Urology and Nephrology Center
Mansoura - Egypt

Basic Clinical Urology

History Taking & Physical Examination

Edited by

Atallah Ahmed Shaaban

Professor of Urology

Faculty of Medicine

Urology and Nephrology Center

Mansoura- Egypt

بسم الله الرحمن الرحيم

Preface and Dedication

The first edition of "Basic Urology: History Taking and Physical Examination" reflects a collection of some notes of information during my development as an urologist. I have tried to concisely summarize the data as simple as possible. The ultimate teachers through the cruise of medical knowledge are always the patients. For all friends who read this book, I would be grateful to have advices, suggestions and possible help for a future edition. I am particularly grateful for all staff at Faculty of Medicine and Urology Department in Mansoura University for their support.

I wish to thank Mrs. Hala Fatehy for her diligent preparation of this handbook and Mr. Fetoh Ateyia for the illustrations.

This work is lovely dedicated to all with intention to be urologists. All are kindly requested to devote themselves to the service of our patients.

Atallah Ahmed Shaaban

Urology and Nephrology Center

Mansoura, Egypt 2011

E-mail: shaaban1953@yahoo.com

Preface and Acknowledgements to the Second Edition

The purpose of **Basic Clinical Urology: History Taking and Physical Examination**" is to provide residents in the urology service with the guides to interview and examine patients attending to urologic practice. The interpretation of clinical data provides the plan for further evaluation of patients. I hope that medical students, house officers, and urology residents will find this book a useful guide in the care of urologic patients and to pass urology examination on clinical cases. This initial approach to patients should not be overlooked by the reliance on laboratory and radiologic investigations or medical reports.

Since I owe a great debt to my ultimate teachers especially late professor Mahmoud M. Badr; it would be a great pleasure to transmit this knowledge to the new generations.

The collaboration of my colleagues has led to inclusion of many illustrative figures in this book that are entertaining and provide basic clinical science. I am truly grateful for their efforts and support throughout the process of producing this edition. I would like to appreciate professors Mostafa el-Refaie, Mostafa el-Hilali, Ibraheim Eraky, Mohamed Dawaba, Ashraf Hafez, Mohamed Abou-el-Ghar and Adel al-Dayel for their support. I am also grateful to Drs, Ahmed el-Hefnawy, Ahmed el-Shal, Ahmed Harraz, Ahmed Mansour, Ahmed el-Sherbeny, Amr el-Sawy, Hussein Sheashaa, Kareem Soliman, Khaled Atallah, Kerolos Nazmi, Mahmoud el-Baz, Mahmoud Laymon, Mohamed Zahran, Mohamed el-Khamesy, Mohamed Badawy, Tamer Helmy, Tamer Zewin, Fady Kamal and Osama Mahmoud.

Also, I wish to thank Mrs. Hala Fatehy, Walaa Tahseen and Ola Zein for their diligent preparation of this book and Mr. Fetoh Ateyia for the illustrations.

I am greatly indebted to my wife for her support and encouragement.

Atallah Ahmed Shaaban
Urology and Nephrology Center
Mansoura, Egypt 2017
E-mail: shaaban1953@yahoo.com

List of Contents

Chapter	Contents	Page
Chapter 1	History taking	1
	Identification: Personal history	2
Chapter 2	Urologic symptoms	3
	Pain	4
	Voiding function and dysfunction	7
	Changes in the gross appearance of urine	19
	Swelling	23
	Urethral discharge	24
	Symptoms of chronic kidney disease	25
	Male genital symptoms	27
	Female genital symptoms	30
Chapter 3	History of present illness	31
Chapter 4	Past history	33
	Medical history	33
	Surgical history	45
	History of trauma	46
Chapter 5	Family history	49
Chapter 6	Social history	51
Chapter 7	Systematic review	53
Chapter 8	Indirect urologic symptoms	55
Chapter 9	Asymptomatic cases in urology	57
Chapter10	Hematuria	61
Chapter11	Acute renal failure: Oliguria and anuria	67
Chapter12	Urine Retention	73
Chapter13	General examination	77
	Vital signs	78
	The head	80
	Integuments	86
	The neck	89
	Body habitus	90
	Lymph nodes	95
Chapter14	Chest and heart	101
Chapter15	Abdominal examination	103
	Inspection	105
	Auscultation	119
	Palpation	120
	Percussion	126
Chapter16	Clinical features of a urologic mass	129
Chapter17	Examination of the back and spine	133
Chapter18	Examination of the scrotum and testis	137
	Testis	139
	Epididymis	154
	Spermatic cord	156
Chapter19	Examination of penis and perineum	161
Chapter20	Digital Rectal Examination	177
Chapter21	Vaginal Examination	191
Chapter22	Urological diagnosis and management	197

List of tables

Table	Contents	Page
Table 1	International Prostate Symptom Score	13
Table 2	Physical characters of urine	19
Table 3	Common causes of colorful urine	20
Table 4	Classification of CKD by Glomerular Filtration Rate	26
Table 5	Features of Uro-genital Bilharziasias	34
Table 6	Drug-Induced Urogenital Symptoms	36
Table 7	Urogenital Features of Diabetes Mellitus	39
Table 8	Features of Urogenital Tuberculosis	44
Table 9	Paraneoplastic Syndromes with Renal Cell Carcinoma	58
Table 10	Diagnosis of Acute Urine Retention and Obstructive Anuria	75
Table 11	Performance Status	78
Table 12	Classification of Body Built According to BMI	90
Table 13	Important chest problems in urologic practice	102
Table 14	Inguinal hernias	115
Table 15	Differentiating Splenomegally and an Enlarged Left Kidney	125
Table 16	Clinical characterization of features of a mass	129
Table 17	Differential Diagnosis of Acute Scrotal Swelling	148
Table 18	Comparison of Primary and Secondary Varicocele	159
Table 19	Ulcers of the Penis	165
Table 20	Types of Priapism	172
Table 21	Features of urethral injuries	173
Table 22	Features of prostate by DRE in health and disease	185

List of figures

Figure	Contents	Page
Figure 1	Classification of urologic symptoms	3
Figure 2	Distribution of renal pain and ureteral colic	5
Figure 3	Post-micturition dribbling	10
Figure 4	Lower urinary tract symptoms	11
Figure 5	Classification of causes of nocturia	15
Figure 6	Differential diagnosis of abdominal swelling	23
Figure 7	Classification of mechanisms of injury in urology	46
Figure 8	Classification of adrenal masses	59
Figure 9	Causes of intrinsic acute renal failure	69
Figure 10	Features of Cushings' syndrome	81
Figure 11	Features of Tuberous Sclerosis Complex	83
Figure 12	Features of Birt - Hogg - Dubé Syndrome	84
Figure 13	Kaposi sarcoma	88
Figure 14	Differential diagnosis of pitting edema	93
Figure 15	Cervical lymphadenopathy	98
Figure 16	Clinical and radiological manifestations of lymph node metastases in some genito-urinary tumors	99
Figure 17	Division of the abdomen into 5 areas	104
Figure 18	Division of the abdomen into 9 areas	104
Figure 19	Inspection of the abdomen	105
Figure 20	Clinical features of right renal tumor with an IVC	106
Figure 21	Recurrent stone disease with an incisional hernia	107
Figure 22	Features of Cushings' syndrome	108
Figure 23	Ileal loop conduit stoma	109
Figure 24	Ileal loop conduit stoma with an intestinal fistula	109
Figure 25	Continent cutaneous diversion: Self catheterization	110
Figure 26	Left-sided terminal colostomy, stomal stenosis and parastomal hernia	110
Figure 27	Divarication of recti muscles	111
Figure 28	Wound infection and dehiscence	117
Figure 29	Gunshot injury of the right upper abdomen	118
Figure 30	Bimanual palpation of a renal mass	122
Figure 31	Suprapubic swelling simulating a full urinary bladder, diagnosed as a huge ovarian cyst	125
Figure 32	The back areas in a case of right peri-nephric abscess	133
Figure 33	Kypho-scoliosis in a patient with a left kidney stone	135
Figure 34	Myelomeningocele	135
Figure 35	Lipoma in the lumbar area with a hair tuft overlying , and pre-sacral hemangioma and dimple	136
Figure 36	A case of sacral agenesis	136
Figure 37	Scrotal edema secondary to lymphatic obstruction	138

Figure	Contents	Page
Figure 38	Examination of the testis	139
Figure 39	Potential sites of incompletely descended testis	141
Figure 40	Cancer in an abdominal undescended testis	142
Figure 41	The chair test	143
Figure 42	Potential sites of ectopic testis	155
Figure 43	Ectopic right testis in the perineal region	144
Figure 44	Torsion of the right testis in adult	146
Figure 45	Left testicular torsion in a child	146
Figure 46	Examination of the other testis in testicular torsion	146
Figure 47	Explosive injury of the testis	147
Figure 48	Solitary left testis and abdominal mass	150
Figure 49	High inguinal orchidectomy for right testicular tumor	151
Figure 50	Non-Hodgkin lymphoma of the testis and opposite inguinal lymphadenopathy	152
Figure 51	Types of hydrocele	153
Figure 52	Right epididymal cyst	155
Figure 53	Unilateral absence of the vas deferens	157
Figure 54	Gangrene of glans penis and skin of the penile shaft	161
Figure 55	Peyronie's disease	162
Figure 56	Fracture penis "eggplant deformity"	162
Figure 57	Carcinoma of the penis	163
Figure 58	Post-circumcision phimosis	164
Figure 59	Different types of hypospadias	166
Figure 60	Hypospadias with chordee	167
Figure 61	Post-circumcision urethrocutaneous fistula	167
Figure 62	Male penopubic epispadias	168
Figure 63	Classic bladder exstrophy in newly-borne	169
Figure 64	Classic bladder exstrophy in a newly-borne boy and at followup after repair	169
Figure 65	Penile strangulation caused by a hair tie	170
Figure 66	Duplicated urethra	170
Figure 67	Urethro-cutaneous fistula and peri-urethral abscess	174
Figure 68	Complete cloacal duplication	175
Figure 69	Steps of digital rectal examination in men	178
Figure 70	DRE of the prostatic zone	181
Figure 71	The chestnut	182
Figure 72	DRE in patients with prostate cancer	184
Figure 73	Differential diagnosis of prostatic nodule	185
Figure 74	Bimanual palpation of a bladder mass in the male	187
Figure 75	Bimanual examination in bladder cancer	189
Figure 76	Bidigital examination to assess Cowper's gland	190
Figure 77	Imperforate hymen	191
Figure 78	Prolapsed thrombosed female urethra	192
Figure 79	Prolapsed ureterocele in an adult lady	193

CHAPTER 1 HISTORY TAKING: IDENTIFICATION

History Taking

History taking and clinical examination include the initial approach to the patient and collection of the database information which represent the most important steps in reaching the diagnosis. Laboratory data, radiology films, and reports giving a certain diagnosis, should be considered in the proper time, without overlooking the initial steps of basic clinical urology.

Tips for history taking:

The great gifts you can give to the patient are your attention, concern, and **respect**. Competence is achievable through a constant effort to keep your **knowledge** through continuous medical education. Above all, you should be honest, straightforward and trustworthy at all times. Never give any false comment. Your **smile** will establish a friendly doctor-patient relationship and is encouraging.

All personal information should be kept confidential. Never tell anyone about the patient data unless it is directly related to their care.

It is better to keep your case notes as brief and as clear as possible, using clear, short, and specific terms. The four ethical principles to consider law, morals, and maintain confidentiality through the medical practice, include:

1. Recognition of patient autonomy
2. Emphasis of beneficence
3. Non-maleficence, and
4. Justice.

The universal precautions to avoid viral and other possible blood-borne infections should always be considered and applied.

IDENTIFICATION: PERSONAL HISTORY

Source of history:

History taking is usually obtained from the patient. A family member, friend, referral letter, or the medical records are helpful.

Date of history: The time of patient evaluation should be documented.

Patient data:

Name: The use of the patient name will make you friendly and seem to be taking a greater interest with full attention.

Age is a guide to the nature of urologic diseases. Some conditions are specific to men at certain ages e.g. BPH and prostate cancer.

Gender: Certain disorders are found exclusively in men or women. The possibility of pregnancy is considered in any woman of child-bearing age; and is important in planning the investigations and decision making.

Residence (past & present): Some diseases are common in certain ethnic groups.

Occupation (past & present): Aniline dyes, used in color fabrics, are urothelial carcinogens. Contact with rubber and textile industries, plastics, or tar represent occupational and environmental hazard to the urinary tract. Dye and textile workers are at risk for bladder cancer. If the patient is retired, ask what did he do before?

Education

Marital status: Married or not, Do they have children, Are they healthy?

Referring physician or agency

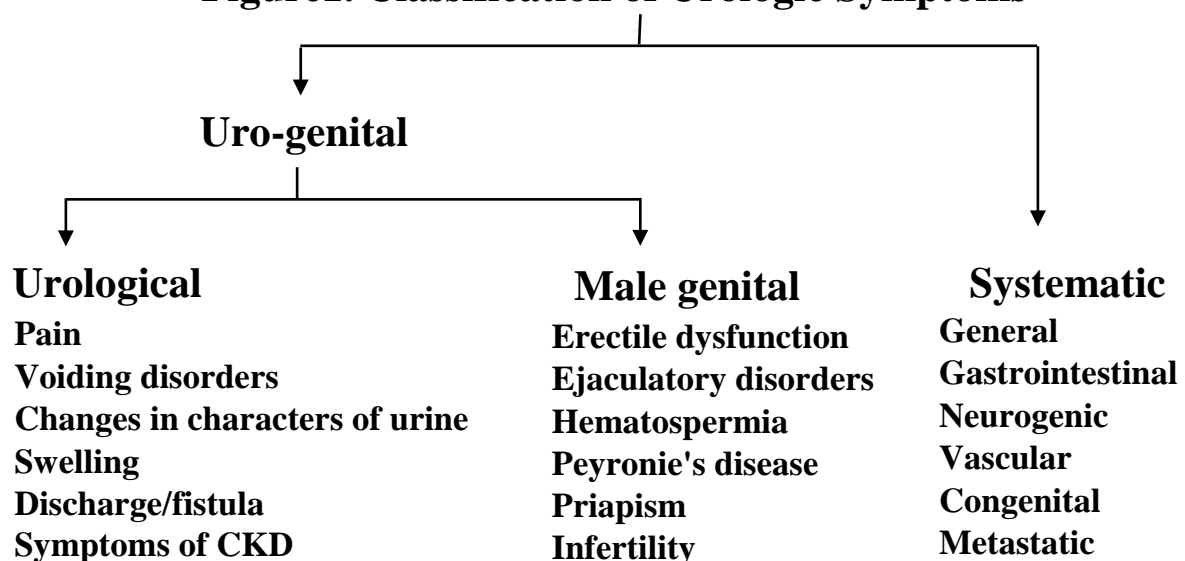
CHAPTER 2 UROLOGIC SYMPTOMS

Urology (genito-urinary surgery) focuses on the surgical and medical diseases of the male and female urinary tract organs (kidneys, adrenals, ureters, urinary bladder, and urethra), and the male reproductive system (testes, epididymis, vas deferens, seminal vesicles, prostate and penis).

The classification of urologic symptoms is shown in figure 1. Complaints are reported in the patient own words e.g. I have passed some blood in my water; he or she wets the bed; he has difficulty during urination and feeling as he cannot empty his bladder completely.

You should always trust the patient. If the patient is quite certain that he has a testicular swelling, and you are not able to feel it, proceed according to his complaint to scrotal ultrasonography.

Figure1. Classification of Urologic Symptoms



PAIN

Pain within the genitourinary tract usually arises from obstruction or inflammation. Referred pain is common. Acute inflammation of parenchyma produces severe pain and fever e.g. pyelonephritis, prostatitis and epididymo-orchitis. Tumors usually do not cause pain unless they produce obstruction or extend to adjacent nerves.

1- Renal pain:

- Renal or flank pain is a visceral pain that results from obstruction of urine flow with distension of the collecting system or the renal capsule.
- Pain due to inflammation is dull, aching and steady.
- It is felt in the posterior renal (costo-vertebral) angle, below the last rib and lateral to the sacrospinalis muscle (Figure 2).
- Pain may radiate anteriorly toward the umbilicus.
- It may be associated with gastrointestinal symptoms e.g. nausea and vomiting.
- Differential diagnosis:
 - **Causes of upper abdominal pain**
 - **Radicular pain:**
 - It results from irritation of costal nerves most commonly T₁₀-T₁₂.
 - Not colicky
 - It is felt in the renal angle and radiates towards the umbilicus.
 - The intensity is altered by changing the position.

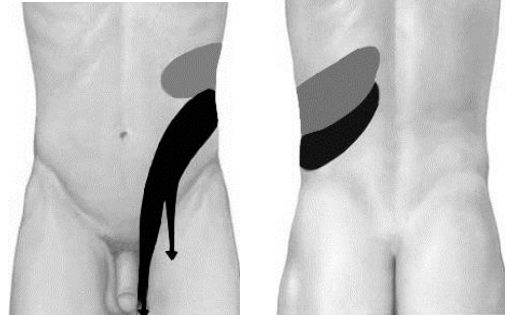
2- Ureteral colic:

- A ureteral stone is the most common cause leading to hyper-peristalsis and ureteral colic.
- The most severe pain a human-kind can experience.
- Patients with ureteral colic are usually moving around in agony, and holding the flank (**the rolling sign**) while patients with intra-peritoneal pathology prefer to lie motionless.
- Ureteral pain is colicky, intermittent, and occurring in waves.
- The site of maximum intensity varies with the site of obstruction.

- Ureteral colic is usually accompanied by renal pain due to distension of the renal pelvis.

Figure 2.

Renal pain is felt in the posterior costo-vertebral angle and radiates anteriorly towards the umbilicus (grey). Ureteral colic distribution and referral is illustrated in black.



- The nerve supply of the upper ureter is by T 10; hence pain may be referred to the umbilicus. Lower down pain is felt at progressively lower levels.
- Pain is originating at the costo-vertebral angle and radiating around the trunk into the lower quadrant of the abdomen, or possibly into the anterior aspect of upper thigh and testicle or labium (figure 2).
- Pain in mid-ureter simulates appendicitis or diverticulitis.
- The lower ureter sends sensory nerves common with pelvic organs. Pain is felt as suprapubic discomfort with vesical irritability (urgency, frequency) and radiates along urethra to tip of penis.
- Often associated with restlessness, nausea, vomiting, sweating, and collapse.
- Associated fever, chills and hematuria may exist.
- Pain is aggravated by jogging movements such as car journeys.

3- Bladder pain:

- Acute urine retention: The sudden inability to urinate inspite of the desire to do so. Pain is severe, bursting, felt in the suprapubic area. The bladder is full and over-distended due to complete obstruction.
- Chronic retention is painless and dribbling is noted as overflow incontinence.
- Cystitis: Suprapubic burning pain is severe when the bladder is full and is relieved partially by voiding. It is associated with frequency and dysuria.

Sharp stabbing suprapubic pain at the end of micturition is termed **strangury**.

- Constant suprapubic pain that is not related to acute retention is seldom of urologic origin.
- **Interstitial Cystitis or Bladder Pain Syndrome (IC/BPS):** Interstitial Cystitis is currently not a scientifically accurate term because many patients have no interstitial pathology and no bladder inflammation. IC/BPS may be associated with urinary urgency, frequency, and nocturia, and sterile urine culture. Those with IC/BPS may have symptoms that overlap with other urinary bladder disorders such as urinary tract infection and overactive bladder,

4- Prostate pain:

- It is due to acute inflammation.
- Localized in the perineum and referred to lower back and rectum.
- Acute prostatitis is associated with fever, frequency, dysuria or acute retention and tenesmus.

5- Penile pain:

- Pain in the flaccid penis is usually due to bladder or urethral inflammation or a stone.
- Paraphimosis: The uncircumcised foreskin is trapped behind the glans penis
- Priapism: Painful, persistent, purposeless penile erection

6- Testicular pain:

- Primary pain is due to acute epididymo-orchitis, torsion of the testis or trauma.
- In patients with testicular discomfort and a normal scrotal examination, renal or retroperitoneal disease should be considered.
- Referred in renal or ureteric colic.

- Hydrocele, varicocele and testicular tumor may be associated with scrotal discomfort.

7- Urethral pain:

- Burning or scalding during micturition is usually due to inflammation or a stone.
- Dysuria is pain or burning during micturition usually caused by inflammation.

VOIDING FUNCTION AND DYSFUNCTION

NORMAL VOIDING

Micturition is urine disposal from the bladder to outside through the urethra. The process is voluntary in adults and depends upon learned behavior, while in infants it is an involuntary reflex. Micturition occurs as coordination between the vesico-urethral unit and the nervous system.

A. Filling or storage phase:

During bladder filling the sympathetic tone predominates (T_{10} to L_2 through the hypogastric nerve). Alpha-receptors increase the muscle tone in the bladder outlet, while beta- receptors in the bladder body relax the detrusor. Pudendal nerve (somatic S_{2-4}) causes contraction of the striated external urethral sphincter. The normal adult bladder can hold up to 500 ml of urine. We become aware of the need to void at 150 ml. At 400 ml we are seeking an appropriate toilet.

B. Voiding or emptying phase:

When the bladder is full stretch receptors are activated and signals are transmitted to the sacral cord. The pelvic nerve endings (parasympathetic, S_{2-4}) release acetylcholine and the detrusor contracts. Inhibitory impulses from the CNS to the sympathetic and pudendal nerves relax the bladder neck and external urethral sphincter to allow continuous, complete emptying of

the bladder in a single setting. A strong warning is given to men not to hold urine in. As soon as you feel the need to go, excuse yourself from whatever you are doing and find a bathroom.

The process of normal urination is defined as follows:

A. Initiation:

A human can start the act of urination even when the bladder is not full. Animals void only when the bladder is full. A human can postpone voiding of a full bladder until he can find a socially suitable place, go to it, adopt it and then start to pass urine.

B. Maintenance:

The normal urinary stream is continuous and free of pain, with adequate force, form and caliber.

C. Termination:

A human can void all urine with no post-voiding residual.

VOIDING DISORDERS

DIFFICULTY

(A) Difficulty in relation to voiding:

1- Difficulty to start:

Hesitancy: The need to wait before urine stream is voluntarily initiated.

Urgency is defined by the ICS (International Continence Society) as the complaint of a sudden compelling desire to pass urine which is difficult to defer.

Urge incontinence: A sudden severe urge to void with involuntary loss of urine. It is caused by bladder muscle contraction.

Overactive bladder (OAB) is a symptom complex, defined by the ICS as urgency, usually accompanied by frequency and nocturia, with or without urge incontinence, in the absence of infection or other obvious pathology. Food and Drug Administration (FDA) defined OAB as "symptoms of urgency, urge urinary incontinence, and frequency." The symptoms have a differential diagnosis including infection, stone, tumor and neurological disorders, which need to be excluded. Urgency is the hallmark symptom of OAB.

2- Difficulty to maintain: Stream abnormalities include:

Intermittency: Involuntary stop and start of urine stream.

Weak stream: Decreased force and caliber of stream.

Bifurcation or spraying of stream

Straining is the use of abdominal muscles to increase intra-abdominal pressure to urinate. Straining will help to void urine in case of **urethral stricture**. However, in prostatic obstruction, the increased intra-abdominal pressure will lead to more obstruction by occlusion of the posterior urethra.

3- Difficulty to terminate:

Sense of incomplete emptying: A feeling that the bladder is not completely emptied at the end of urination.

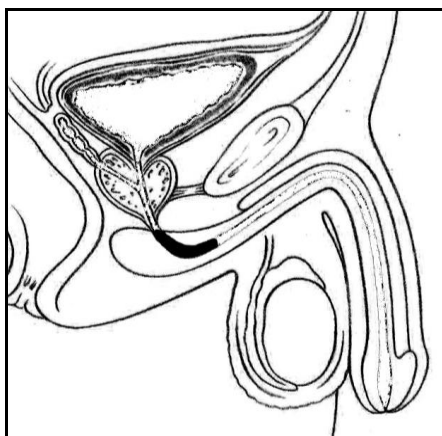
Strangury: Incomplete emptying with sharp stabbing suprapubic pain.

Post-voiding dribbling of urine:


- Release of drops of urine after completion of urination is due to pooling of small amount of urine in the bulbar urethra (figure 3). Normally the last few drops of urine are expelled by contraction of the bulbo-cavernosus and bulbo-spongiosus muscles.

- Post-micturition dribble is fairly a common and benign symptom, and not closely related to outflow obstruction.
- Manual compression and evacuation of the bulbar urethra is effective. Patient is advised to contract the sphincter muscles several times, and exert manual pressure on the perineum, immediately after voiding, to empty the bulbar urethra into the pendulous urethra from which it will drain by gravity.
- Shaking the penis at end of micturition is ineffective.
- Management in the absence of other symptoms, normal flow rate and normal prostate feeling by DRE and PSA, is basically reassurance.
- It is an early symptom of BPH. A small amount of residual urine is normally milked back into the bladder at the end of urination whereas in BPH, it escapes into the bulbar urethra and leaks out at the end of micturition.

Figure 3. Post-micturition dribbling is due to the pooling of small amount of urine in the bulbar urethra (black).



(B) Lower Urinary Tract Symptoms (LUTS): The term **LUTS** was developed to replace "**prostatism**" as a reminder that urinary symptoms may have non-prostatic alternative causes, and to avoid treating the prostate when the problem is elsewhere. Classification of LUTS into irritative and obstructive group is shown in figure 4.

Figure 4. Lower Urinary Tract Symptoms

(C) **The American Urological Association symptom score (table 1)** is widely used to assess men with LUTS. It includes seven questions. The total score ranges from 0 to 7, 8 to 19, and 20 to 35 indicate mild, moderate and severe LUTS, respectively. The International Prostate Symptom Score (I-PSS) is helpful in the clinical management of men with LUTS and in assessment of treatment response. The international prostate symptom score (IPSS) gives a useful measure of both symptom severity and degree of bothersomeness.

Limitations of the AUA symptom score:

- Non-specific
- Patients with neurologic disorders and dementia may have difficulty in completion.
- Conditions other than BPH may have similar symptoms.
- Similar scores were recorded in age-matched men and women over 55 year.

(D) LUTS in prostatic disorders:

In **uncomplicated BPH**, LUTS are **periodic** and exaggerated by 5 **Ws**:

1. Excess **water**, diuretics, caffeine
2. **Wine**: Alcohol causes excessive urine production.
3. Cold **weather**
4. Sexual excitement by **women** without relief
5. **Withholdment** of urination: Some people e.g. teachers and surgeons who do not have time for regular bathroom breaks tend to hold urine. The bladder can develop chronic overdistension leading to chronic emptying problems.

An important item is the degree of bother that the symptoms cause.

In **prostate cancer** most of cases are incidental, and when LUTS develop, they tend to be **progressive**.

(E) The urologist must be careful not to attribute irritative symptoms to BPH unless there is documented evidence of obstruction.

(F) Hematuria associated with irritative symptoms should direct the attention for further work-up for the possible diagnosis of urothelial **carcinoma in situ**.

(G) Another important example is irritative symptoms resulting from **neurologic disease**, such as diabetes mellitus, cerebro-vascular accidents, and Parkinson's disease. The urologist should be careful to exclude neurologic disorders before performing surgery to relieve bladder outlet obstruction. Surgery will fail to relieve irritative symptoms and may result in permanent incontinence.

(H) Common causes of LUTS:

Outflow obstruction: BPH, BNO, urethral stricture, meatal stenosis.

Infection: Cystitis, prostatitis, urethral diverticulum.

Impaired detrusor function: Neuromuscular dysfunction, detrusor instability, impaired detrusor contractility.

Neoplastic: Prostate cancer, bladder carcinoma in situ.

Psychogenic

Table 1. International Prostate Symptom Score (IPSS)

	Not at all	Less than 1 time in 5	Less than half the time	About half the time	More than half the time	Almost always	Patient score
1. Incomplete emptying Over the past month, how often have you had a sensation of not emptying your bladder completely after you finished urinating?	0	1	2	3	4	5	
2. Frequency Over the past month, how often have you had to urinate again less than two hours after you finished urinating?	0	1	2	3	4	5	
3. Intermittency Over the past month, how often have you found you stopped and started again several times when you urinated?	0	1	2	3	4	5	
4. Urgency Over the past month, how often have you found it difficult to postpone urination?	0	1	2	3	4	5	
5. Weak stream Over the past month, how often have you had a weak urinary stream?	0	1	2	3	4	5	
6. Straining Over the past month, how often have you had to push or strain to begin urination?	0	1	2	3	4	5	
	None	1 Time	2 time	3 times	4 times	5 times +	
7. Nocturia Over the past month, how many times did you most typically get up to urinate from the time you went to bed at night until the time you got up in the morning?	0	1	2	3	4	5	
Total IPSS Score							
Quality of life due to urinary symptoms	Delighted	Pleases	Mostly satisfied	Mixed-about equally satisfied And dissatisfied	Mostly dissatisfied	Unhappy	Terrible
If you were to spend the rest of your life with your urinary condition just the way it is now, how would you feel about that?	0	1	2	3	4	5	6

FREQUENCY

Normal adult voids 5-6 times per day and arises no more than twice at night, with a volume of about 300 ml each.

Frequency refers to increased number of times one feels the need to urinate. The patient passes frequent small amounts of urine.

Frequency is expressed by finding out how often the patient pees by day and by night, and can be easily written: D = 5-6 / N = 1-2, if the patient has to void five to six times by day and once or twice at night.

Causes include functional or organic decrease in bladder capacity:

- Inflammation: Edema and impaired elasticity
- Obstruction e.g. In BPH and urethral stricture, the high residual urine decreases the effective functional bladder capacity.
- Stones
- Foreign body
- Tumors
- Neuropathic bladder
- Contracted bladder: Bilharziasis, TB, radiation, interstitial cystitis
- Pharmacological agents
- Psychogenic frequency: Anxiety (no nocturia)

Polyuria

Polyuria is the passage of large volumes of urine with an increase in urinary frequency. It is accompanied with polydipsia (excessive thirst).

Causes of polyuria:

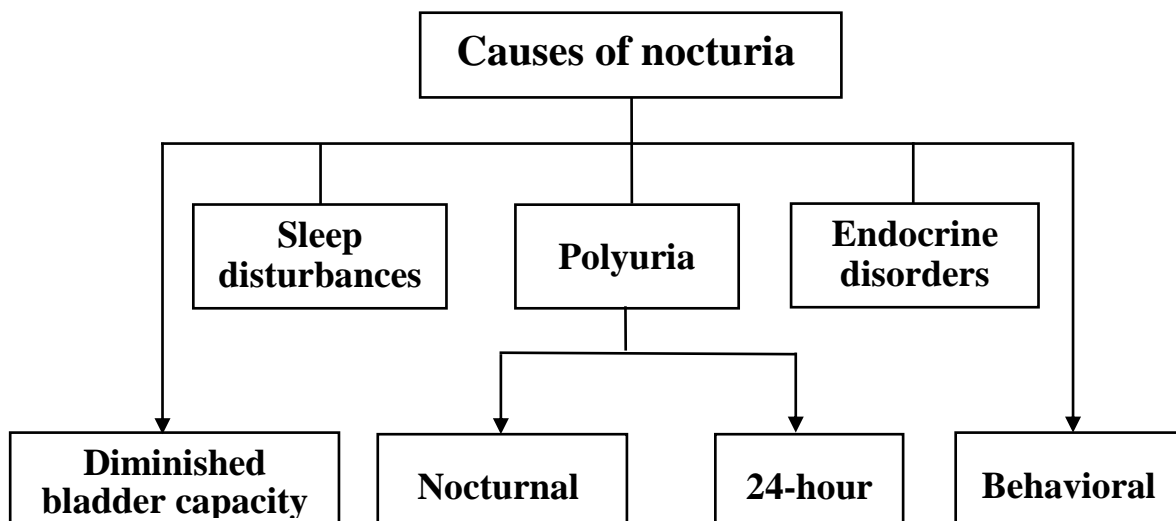
- Endocrine: Diabetes mellitus, cranial diabetes insipidus, Cushings' syndrome, primary hyper-aldosteronism
- Renal: Chronic kidney disease, post-obstructive diuresis, diabetes insipidus
- Iatrogenic: Diuretics

- Alcohol
- Hypercalcemia
- Psychogenic: Compulsive water intake

Nocturia

Nocturia is voiding during nocturnal sleep hours, preceded and followed by sleep. It is also defined by the ICS (International Continence Society) as the complaint of waking at night one or more times to void. Generally, nocturia more than once is bothersome. Diagnosis is based on general medical evaluation combined with **voiding diary analysis** (fluid intake and output chart). This chart helps to avoid the misinterpretation between frequency/nocturia and polyuria. The prevalence of nocturia in women (43%) is similar to that in men (37%). It is a little more common in younger women and older men in whom causes other than BPH should be excluded.

Figure 5. Classification of Causes of Nocturia



Causes of nocturia (figure 5):

- Diminished bladder capacity: Causes of frequency.
- Nocturnal polyuria:
 - Peripheral edema (congestive heart failure, venous stasis, nephrotic syndrome, liver failure, hypo-albuminemia).
 - Renal concentrating ability decreases with advanced age.
 - The renal blood flow increases at night as a result of recumbency.
- Sleep disturbances: Obstructive sleep apnea
- Endocrine disorders: Diabetes mellitus, diabetes insipidus
- Behavioral: Excessive nighttime fluid intake especially coffee and alcoholics.

Dysuria is painful micturition due to cystitis, urethritis, bladder stones or malignancy.

NOCTURNAL ENURESIS

Bedwetting at night is physiologic during the first 3 years of life but becomes troublesome to parents after that. It persists in 15% of children at age 5 and about 1% at age 15.

a) Functional:

It is secondary to delayed maturation of the vesico-urethral components.

b) Organic:

- Distal urethral stenosis in girls
- Posterior urethral valves in boys
- Infection
- Neuropathic bladder

URINARY INCONTINENCE

Incontinence: Neither men nor women are totally continent. Slight stress incontinence in women and post-micturition dribbling in men are so common as to be normal.

A) True incontinence:

It is defined as continuous involuntary loss of urine at all times and in all positions.

- Vesico-vaginal fistula: the most common cause.
- Exstrophy-epispadias.
- Neuropathic bladder.
- Sphincter injury by prostatectomy.
- Ectopic ureter that enters the female genital tract results in normal voiding with continuous small urinary leak. Ectopic ureters do not produce incontinence in males.

B) Stress Urinary Incontinence (SUI):

Stress urinary incontinence has 3 components by the ICS definition:

- **A symptom:** Complaint of involuntary leakage on exertion.
- **A sign:** Leakage of urine synchronous with exertion on examination.
- **Urodynamic finding:** Leak of urine during increased abdominal pressure, with no detrusor contraction.
 - Sudden loss of urine is associated with physical strain e.g. coughing, sneezing, laughing, exercise, having sex and lifting heavy objects.
 - The intra-abdominal pressure exceeds the urethral resistance.
 - SUI is seen in women after childbearing or menopause due to loss of muscle support.
 - In men, SUI may be seen after prostatectomy.

C) Urge incontinence:

- It is sudden strong desire to void with involuntary leakage of urine.
- Causes include acute cystitis in women, neuropathic bladder, and bladder outlet obstruction.

D) False (overflow or paradoxical) incontinence:

- Loss of urine due to chronic retention as in cases of enlarged prostate, stricture urethra or secondary to a flaccid bladder.
- The bladder is decompensated and acts as a fixed reservoir. When the intravesical pressure equals the urethral resistance, constant dribbling of urine occurs (mechanical overflow).

Clinical evaluation of urinary incontinence:

History:

Onset, duration, pattern (diurnal, nocturnal, occasional, continuous)

Type: Stress, urge, total, and overflow

Voiding pattern: Normal, frequency, urgency, straining.

Drugs: Anticholinergic, alpha adrenergic blockers, diuretics, sedatives, hypnotics, opiates.

Surgery: Hysterectomy, prostatectomy, orthotopic neobladder, anti-incontinence procedures.

Obstetric: Parity, deliveries, trauma.

Physical examination:

General: Obesity

Abdominal: Chronic retention

Vaginal examination: Masses, prolapse, cystocele, rectocele.

DRE: Anal tone, voluntary control, fecal impaction.

BPH, masses.

Bladder: Post-voiding residual urine.

Stress bladder test

Neurological: Peri-anal sensation, sacral reflexes.

CHANGES IN THE GROSS APPEARANCE OF URINE

Table 2. Physical Characters of Urine

	Normal	Abnormal
Color	Straw color or Amber yellow	Red urine Milky urine
Aspect	Clear	Turbidity
Nature	Liquid	Gas : Pneumaturia Solid: Stones, Blood clots (red clots), Foreign bodies e.g. stents, Fecaluria Necroturia (tumor tissues or white clots)
Odor	Aromatic	Fishy Ammoniacal Fruity (acetonuria)
Volume	1 ml/min in adults (about 1500 ml/day)	No urine: Acute retention Anuria Oliguria Polyuria

The physical characters of urine in normal individuals and abnormal conditions are enlisted in table 2. The normal yellow color of urine is caused by the presence of various amounts of urochrome, a pigment produced from hemoglobin degradation.

Causes of colorful urine (table 3):

A. Red urine: Hematuria is the most important symptom in the whole of urology, and will be discussed in a separate section. The other causes of red urine are enlisted in table 3.

B. Milky urine: The passage of lymphatic fluid (chyle) is noted by the patient as milky white urine. Chyluria is caused by filariasis, trauma, T.B. and retroperitoneal tumors leading to lymphatic-urinary fistula.

Table 3. Common Causes of Colorful Urine

Colorless	Overhydration
Cloudy/Milky	Phosphaturia Pyuria Chyluria
Red Urine	Hematuria Hemoglobinuria/myoglobinuria Anthrocyanin in beets and blackberries Chronic lead and mercury poisoning Phenolphthalein (in bowel evacuants) Phenothiazines Rifampin
Orange	Dehydration, drugs (Pyridium, Sulfasalazine)
Yellow	Normal, Drugs (Phenacetin, Riboflavin)
Green-Blue	Biliverdin Indicanuria (tryptophan indole metabolites) Amitriptyline Indigo carmine Methylene blue Phenols [cimetidine (Tagamet), promethazine (Phenergan)] Resorcinol Triamptere (Dyrenium)
Brown	Urobilinogen Porphyria Aloe, fava beans and rhubarb Chloroquine and primaquine Furazolidone (Furoxone) Metronidazole (Flagyl) Nitrofurantoin (Furadantin)
Brown-Black	Alcaptonuria (homogentisic acid) Hemorrhage Melanin Tyrosinosis (hydroxyphenylpyruvic acid) Cascara, senna (laxatives) Methocarbamol (Robaxin) Methyldopa (Aldomet) Sorbitol

Passage of stones: An important symptom in stone formers.

Turbidity "Cloudy urine":

a) **Phosphaturia:** The most common cause of cloudy urine.

Phosphate crystals precipitate in alkaline urine causing turbidity. It clears if acetic acid is added.

b) **Uricosuria:**

Uric acid crystals are dissolved in urine at body temperature. Uric acid precipitates if urine is left to cool down at room temperature causing turbidity. Urine becomes clear if heated.

c) **Pyuria :**

- Bacterial infections
- Abacterial or sterile pyuria (stones, obstruction, tumors, T.B.).
- Turbidity which neither disappears by acidification nor by heating is caused by pus.

Passage of mucus: Incorporation of intestinal segments into the urinary tract is associated with passage of mucus in urine.

Pneumaturia:

The passage of gas bubbles or flatus in urine can be caused by:

- a. Fistula between bowel and bladder is secondary to diverticulitis, colon cancer, Crohns disease and trauma. Usually there is coexistent presence of faeces (**fecaluria**). Important examples include pneumaturia and fecaluria following radical prostatectomy and cystectomy due to improper management of rectal injuries with subsequent development of uro-rectal fistula.
- b. UTI by sugar-fermenting organisms in poorly controlled diabetic patients.

- c. Iatrogenic: Recent urinary tract instrumentation
- d. Congenital: Urethro-rectal fistula

Necroturia:

The passage of pieces of tumor tissue in cases of carcinoma of the bilharzial bladder is described by the patient as "pieces of fat".

Odor Changes

Urine normally does not have a strong odor.

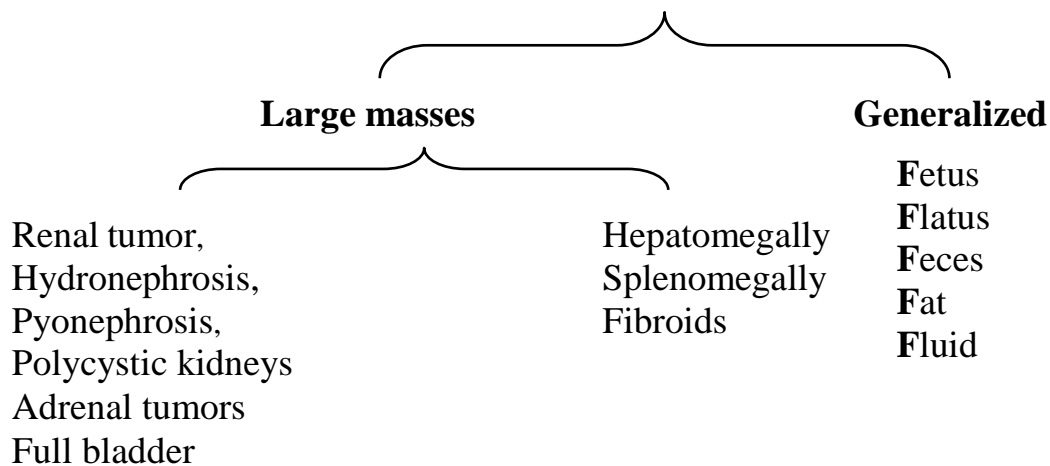
- a. Fishy smell is characteristic of E.coli infection.
- b. Ammonical smell is due to alkaline decomposition of urine. A pungent odor may be due to urinary tract infection or urinary stones, which can create an ammonia-like odor.
- c. Diabetics might notice that their urine smells sweet, because of excess sugar.
- d. Some foods can also change urine odor.

SWELLING

The patient may present with a swelling or a mass as a symptom: A big abdominal mass in a wasted baby was the classical way in which children with Wilms' tumor are brought to attention.

1. Abdominal swellings (figure 6):

Figure 6. Differential Diagnosis of Abdominal Swelling



2. Lumps in the groin:

- Hernia (inguinal, femoral)
- Enlarged inguinal lymph nodes
- Saphena varix
- Hydrocele of the cord
- Undescended testis
- Lipoma of the cord
- Femoral aneurysm
- Psoas abscess

3. Lumps in the scrotum:

- Orchitis, TB epididymo-orchitis
- Testicular tumor
- Gumma of the testis
- Hydrocele: Fluid-filled cyst around the testis, which is difficult to feel.
- Epididymal cysts: A fluid-filled cyst lies behind the body of the testis.
- Varicocele
- Sebaceous cyst
- Carcinoma of scrotal skin

4. Cervical lymph node: Mass in the left supraclavicular nodes can be due to metastatic spread of testis and abdominal cancers.

URETHRAL DISCHARGE

Discharge is the passage of abnormal fluid through a natural passage e.g. urethral purulent discharge in men due to *Neisseria gonorrhea* or *Chlamydia trachomatis*. It is the most common symptom of venereal infection. A scant and watery discharge is generally associated with nonspecific urethritis. Comment on the following points:

- Amount
- Color
- Presence of blood
- Relation of discharge to urination and ejaculation
- Pain
- Associated symptoms: Conjunctivitis and arthralgia
- Relation to sexual contacts
- Exposure to STDs

FISTULA

A fistula is an abnormal connection between organs that are naturally separate. **Fistula is manifest by the passage of normal fluid or body contents through an abnormal passage.**

- **Uro-gynecologic fistula:**

- a) Vesico-vaginal fistula: Total urinary incontinence.
- b) Uretero-vaginal fistula: Paradoxical incontinence.
- c) Vesico-uterine fistula: Cyclic hematuria.

- **Uro-intestinal fistula:**

Colovesical fistula is abnormal connection between colon and bladder that may develop in men or women with inflammatory bowel disease or diverticulitis and can result in passage of gas (pneumaturia) or stool (fecaluria) in urine, UTI's and sepsis.

- **Uro-cutaneous fistula:**

The urinary tract can communicate to the skin at any level from the kidney to the urethra as a complication to surgery, trauma or disease.

URETHRAL BLEEDING

Urethral bleeding is seen following urethral injuries, and in cases of tumors of the urethra. Bleeding per urethra should be differentiated from hematuria.

URETHRORRHAGIA

Urethrorrhagia refers to urethral bleeding in prepubertal boys. Blood spots are found on underwear after voiding. This causes anxiety to the patient and the parents. The condition is recurrent for several months, and has a benign self-limited course. Radiological as well as endoscopic studies are unnecessary.

SYMPTOMS OF CHRONIC KIDNEY DISEASE

- Chronic kidney disease (CKD) is defined as sustained kidney damage greater than 3 months resulting in glomerular filtration rate (GFR) of less than 60 ml/min/1.73 m². The most common causes of CKD are diabetes mellitus (about 50%) and hypertension (25%), followed by glomerulonephritis.
- CKD consists of five stages of functional deterioration (table 4), according to the GFR, associated with specific clinical and biochemical abnormalities. The spectrum of symptoms is variable according to the stage of CKD, comorbid conditions and the presence of complications.

Table 4. Classification of CKD by Glomerular Filtration Rate

<i>Stage</i>	<i>Description</i>	<i>GFR (ml/min/1.73 m²)</i>
I	Kidney damage with normal or increased GFR	≥ 90
II	Kidney damage with mild decrease in GFR	89 to 60
III	Moderate decrease in GFR	59 to 30
IV	Severe decrease in GFR	29 to 15
V	Kidney failure	<15 (or dialysis)

- Mild cases of CKD are asymptomatic or present with nonspecific symptoms as headache and fatigability, or discovered incidentally.
- Advanced cases have the symptoms of anorexia, nausea, vomiting, salt retention, acidosis, insomnia, anemia, muscle fatigability, and worsening control of hypertension.
- The commonest symptoms are poor appetite, nausea, and vomiting followed by fatigability and headache.
- The symptoms of chronic renal failure are summarized as follows:
 - Lack of concentration is the earliest symptom.
 - Headache
 - Blurring of vision
 - Epistaxis
 - Dry mouth
 - Tachypnea
 - Palpitations
 - Gastrointestinal manifestations (anorexia, dyspepsia, bitter taste, constipation, bleeding)
 - Genital problems (loss of libido, erectile dysfunction, infertility)
 - Itching and hiccup are late.

Male Genital Symptoms

Sexual activity includes libido (interest in sex), function (ability to achieve and maintain an erection), satisfactory intercourse, orgasm and ejaculation. Sexual counseling should discover the main problem.

I. DISAPPOINTMENT



It is important to realize that the early sexual activity, a novelist man can achieve a satisfactory intercourse, is **tri-daily**, then **tri-weekly**, then **tri-monthly**...!! Normal performance diminishes with age at varying rates and a man will **try oysters** and sea food, and then he is advised to **try anything** prescribed, at last he is asked to **try to remember**...!! Patients may have normal sexual function with exaggerated expectations.

II. DISORDERS OF EJACULATION

a) Premature ejaculation is persistent occurrence of ejaculation with minimal sexual stimulation before or shortly after penetration.

- It is common for men to ejaculate within 2 minutes after initiation of coitus. Men with true premature ejaculation reach orgasm within less than 1 minute, before penetration or before his partner has achieved climax. Let the couple have a rest and try again a little later...!!
- It is always psychogenic.
- Consider medications, surgery, neurologic deficits, or androgen deficiency.

b) Retarded ejaculation is undue delay to reach orgasm e.g. anxiety.

c) Retrograde ejaculation is backflow of semen into the bladder due to: Anatomic causes e.g. incompetent bladder neck after prostatic surgery, neurological e.g. spinal cord injuries, diabetes mellitus, retroperitoneal lymph node dissection, multiple sclerosis, and pharmacologic e.g. alpha adrenergic blockers.

- d) No ejaculation:** Failure to ejaculate at all may result from diabetic autonomic neuropathy, retroperitoneal lymph node dissection for testicular cancer, alpha-adrenergic blockers, androgen deficiency, and prostatic surgery. The cause may remain obscure.

III. IMPOTENCE: NO ERECTION

Erectile dysfunction (ED) is defined as the consistent or recurrent inability of a man to achieve and/or maintain a penile erection sufficient for sexual activity. ED can have organic, psychogenic or mixed etiology.

A. Organic ED develops gradually and is related to physical risk factors. Etiology is usually multifactorial.

Iatrogenic ED: Radical pelvic surgery and radiotherapy; damage to neural control; damage to pelvic vasculature e.g. aorto-iliac surgery, a second contralateral kidney transplant with end-to-end internal iliac artery anastomosis, surgery for priapism, Peyronie's, urethroplasty.

Medications: Antihypertensive, sedatives, psychotropic, hormones.

Penile vasculogenic ED is due to reduced arterial inflow e.g. arteriosclerosis.

Obesity

Trauma: Spinal cord injuries and pelvic fractures associated with urethral disruption.

Endocrine abnormalities mainly hypogonadism may lead to ED. Hyperprolactinemia and thyroid disorders are rare causes. About 50% of all diabetic men develop ED.

Neurogenic: Supraspinal, spinal and peripheral nerve lesions.

Cardiovascular: Heart disease, hypertension, high cholesterol.

Endurance: Smoking, alcohol, aging, chronic renal failure.

B. Psychogenic ED has an abrupt onset secondary to marital stress, anxiety, insomnia, depression, and relationship difficulties. Patients will note early morning erections, and respond to different forms of sexual stimulation e.g. erotic videos and masturbation.

IV. LOSS OF LIBIDO: NO DESIRE

Depression, drugs and medical diseases may be associated with loss of libido or sex drive. A middle aged ambitious man has a work-related stress and has no time and no interest in his wife, and collapses exhausted to bed, is advised to leave his work at the office..!!

V. LOSS OF ORGASM: Anorgasmia is the inability to achieve the pleasurable sensation of orgasm during intercourse.

Psychogenic

Psychotropic drugs

Decreased penile sensation e.g. in diabetic neuropathy.

HEMATOSPERMIA:

- The presence of blood in seminal fluid is usually due to nonspecific inflammation of the prostate or seminal vesicles or after a prolonged sexual abstinence and resolves spontaneously within several weeks.
- Exclude tuberculosis and prostate cancer if hematospermia persists.

PEYRONIE'S DISEASE: Curvature of the penis secondary to formation of fibrous plaques within the tunica albuginea

PRIAPISM is persistent or prolonged (>4h), painful, purposeless (in the absence of sexual stimulation) penile erection.

INFERTILITY is the inability to conceive after one year of unprotected sexual intercourse.

Testicular pain or masses, and testicular self-examination practices, history of sexually transmitted diseases, and treatments; and possible HIV infection should be considered.

There is an increased risk of infections among men engaging with prostitutes or anal intercourse.

Female Genital Symptoms

Obstetric and gynecologic histories (menstrual history, obstetric history, birth control, and sexual function)

Menstrual history is important to avoid confusion between menstrual blood loss and hematuria, and we should not have unnecessary X-rays during pregnancy.

Note the date of last menstruation on the X-ray request.

Menstruation: Age at menarche; regularity, frequency, and duration of periods; amount of bleeding, bleeding between periods, last menstrual period; dysmenorrhea, premenstrual tension.

Vaginal manifestations: Discharge, itching, sores, lumps, and history of STDs.

Pregnancies: Number, types, and complications of deliveries, and abortions.

Birth control methods

Menopause: Onset, menopausal symptoms, postmenopausal bleeding. Sexual activity: Interest, function, satisfaction, dyspareunia.

The possibility of pregnancy must be entertained in any woman in the child-bearing age.

CHAPTER 3: HISTORY OF PRESENT ILLNESS

- The reason presenting the patient to the urologist is **the chief complaint**.
- Put the pertinent positives first, and include all the relevant negatives e.g. **no hematuria**, that help to clarify the differential diagnosis.
- Symptoms are arranged in a chronological sequence. Renal colic followed by hematuria is suggestive of stones, while hematuria followed by colic may result from a tumor.
- Information obtained from the retrieval and review of the patient old records is important.

- **Details of the current symptoms (OLD CARTS):**
 - **O**nset: date it began, sudden or gradual, over how long?
 - **L**ocation and radiation: ask the patient to point to the site with one finger and whether the pain moves anywhere else?
 - **D**uration
 - **C**haracters: nature of the symptom
 - **A**ggravating factors: What makes the symptom worse?
 - **R**elieving factors: What makes the symptom better?
 - **T**iming and frequency: improving or deteriorating with time
 - **S**everity

- Setting in which the symptom occurs
- Details of previous similar episodes
- Associated manifestations
- Details of investigations and treatment for the current problem
- Extent of functional disability
- Menstrual and reproductive history for women

CHAPTER 4: PAST HISTORY

Details of **the therapeutic history**, whether medical or surgical, are critical and of great importance in diagnosis of a disease and decision making. Also, we should ask about health maintenance and **screening tests** such as abdominal ultrasound and serum PSA testing.

Medical History

Asking the patient: Have you ever had any medical problem, or been to hospital for anything? Medical history is reported about important diseases e.g. diabetes, hypertension, hepatitis, bronchial asthma, and cardiac conditions. It is important to record hospitalizations (dates, locations, service) within the past medical history.

Allergies and Reactions:

- Any adverse effects or reactions to medications and contrast media?
- Anaphylaxis or immediate hypersensitivity is a life-threatening reaction and an absolute contraindication to re-exposure.
- Medical allergies should be marked **boldly** on the patient's chart.
- Antiallergic, antihistaminic and sympathomimetic drugs precipitate LUTS, a fact that should be taken in consideration in elderly men.

Bilharziasis (Schistosomiasis):

- Bilharziasis is endemic in Egypt and has a causal relationship to a wide range of clinical syndromes and systemic complications.
- A thorough evaluation is mandatory, during the preparation of a patient with hepatosplenic bilharziasis, for urologic surgery.
- Pathological and clinical features of genitourinary bilharziasis are enlisted in table 5.
- History of exposure of the patient to disease: Where have you been?

Table 5. Features of Uro-genital Bilharziasias

	Pathological features	Clinical features
Urinary bladder	<p>A. Mild lesions: Tiny granulomas and hyperemia.</p> <p>B. Gross changes:</p> <ol style="list-style-type: none"> 1. Sandy patches 2. Polyps & granulomas 3. Chronic ulcers 4. Urothelial changes: Brunn's nests, Cystitis cystica, Hyperplasia and dysplasia, Cystitis glandularis, Squamous metaplasia & Leukoplakia. <p>C. Complications:</p> <ol style="list-style-type: none"> 1. Secondary bacterial infection 2. Bladder neck obstruction 3. Fibrotic contracted bladder 4. Bladder cancer associated with bilharziasis 5. Secondary renal changes 	<p>A. Simple bilharzial cystitis:</p> <ol style="list-style-type: none"> 1. Vague suprapubic pain relieved by voiding 2. Mild frequency 3. Terminal drop hematuria 4. Slight turbidity of urine <p>B. BNO: Straining</p> <p>C. Contracted bladder: Frequency</p> <p>D. Cancer of bilharzial bladder: Progressive cystitis with alterations and additions:</p> <ol style="list-style-type: none"> 1. Severe suprapubic pain not relieved by voiding, dysuria, penile, perineal, renal, back and sciatic pains. 2. Severe day and night frequency, urgency-even active incontinence 3. Total, subtotal, clot hematuria (pieces of liver) 4. Gross pyuria, necroturia (pieces of fat)
Ureters	<p>A. Gross changes:</p> <ol style="list-style-type: none"> 1. Sandy patches 2. Polyps & granulomas 3. Ulcers 4. Epithelial changes: ureteritis cystica, glandularis and calcinosa. <p>B. Complications:</p> <ol style="list-style-type: none"> 1. Ureteric strictures 2. Ureteric stones 3. Vesicoureteric reflux 4. Hydroureteronephrosis 5. Carcinoma of the ureter 	<p>A. Symptoms and signs of infection, obstructive uropathy, and stone formation</p> <p>B. Bilateral ureteric pathology may lead to chronic renal failure or obstructive anuria</p>
Kidneys	<p>A. Secondary complications: Hydronephrosis, pyelonephritis, stones, pyonephrosis and renal failure</p> <p>B. Glomerulonephritis and glomerulosclerosis</p>	<p>A. Manifestations of obstructive uropathy, infections, and stone formation</p> <p>B. Renal failure</p> <p>C. Xanthogranulomatous pyelonephritis</p>
Male urethra	<p>A. Bilharzial changes in roof of bulbous urethra</p> <p>B. Bacterial periurethritis</p> <p>C. Urethrocutaneous fistulas</p>	Watering can perineum develops when urethrocutaneous fistulas occur.
Prostate	<p>A. Rarely involved.</p> <p>B. Granulomatous, nodular, enlarged, hard prostate</p>	Lower urinary tract symptoms
Seminal vesicles	<p>A. Fibrosis, and calcification</p> <p>B. Cystic dilatation</p>	Hemospermia is rare, Radiological "honey-comb" appearance
Spermatic cord and testis	<p>A. Granulomas of the cord</p> <p>B. Granuloma of the epididymis</p> <p>C. Secondary hydrocele</p>	Mass of the cord: solitary, diffuse, or multiple nodules

- Pre-localization: Swimmer's itch with fever
- Localization: The commonest initial pathological disease process is simple bilharzial cystitis.
- Diagnosis
- Treatment: type and response
- Complications

Calculi:

- Renal colic
- Passage of stones
- Treatment
- Complications
- Causes of stone formation:
 - o Hereditary disorders: Renal tubular acidosis, cystinuria
 - o Dietary excess of oxalates, purines, calcium
 - o Urinary tract infection and obstruction
 - o Dehydration states e.g. hot climates and diminished fluid intake
 - o Gout
 - o Hyper-calcemic disorders e.g. primary hyper-parathyroidism and prolonged immobilization

Drugs:

A list of medications should be developed including: type, dosage, route of intake, frequency, and duration. Of particular interest are the drugs relevant to urologic symptoms and planning for surgery (table 6). Drugs must be disclosed because serious problems may result. For example, the use of aspirin, which may be considered too simple to mention, can increase bleeding during surgery.

Table 6. Drug-Induced Urogenital Symptoms

Symptoms	Drugs	Examples
Hematuria	Anticoagulants Chemotherapeutics	Warfarin and heparin Cyclophosphamide and Ifosphamide
Colorful urine	Rifampicin	
Obstructive LUTS	Antimuscarinic drugs Anxiolytics Calcium-channel blockers Antiparkinsonian α - Adrenergic agonists Antihistamines	Oxybutynin ,Flavoxate , Propantheline ,Tolterodine Diazepam Nifedipine Levodopa and carbidopa Pseudoephedrine, phenylephrine Loratadine, Diphenhydramine
Acute renal failure	Antimicrobials NSAIDs Radio-contrast agents Immunosuppressant Chemotherapeutics	Aminoglycosides Cyclosporine Cisplatinum
Incontinence or impaired voiding	Direct smooth muscle stimulants Smooth and striated muscle relaxants	Vasopressin Furosemide Valproic acid Diazepam Baclofen
Erectile dysfunction	Antihypertensives Psychotropic drugs	Hydrochlorothiazide Propranolol Benzodiazepines
Ejaculatory dysfunction	α -Adrenergic antagonists Psychotropic drugs	Prazosin, Tamsulosin α -Methyldopa phenothiazines Antidepressants
Priapism	Antipsychotics Antidepressants Antihypertensives	Phenothiazines Trazodone Hydralazine, Prazosin
Decreased spermatogenesis	Chemotherapeutics Drugs abuse Drugs affecting endocrine function	Alkylating agents Marijuana, Alcohol, Nicotine Antiandrogens Prostaglandins

Endocrine diseases:

Diabetes mellitus is associated with an earlier onset and increased severity of urologic diseases. It frequently results in vascular complications, neuropathy and nephropathy. Urologic complications of diabetes include bladder dysfunction, urinary tract infections, and chronic kidney disease. Sexual problems in men with diabetes include erectile dysfunction and retrograde ejaculation.

Wound complications are common in diabetic patients.

Features of the disease are shown in table 7. Note:

- Type, medications taken, and recent evaluation
- Age of onset, duration, organ involvement
- Development of complications.

Adrenal disorders include Cushing syndrome, hyper-aldosteronism, congenital adrenal hyperplasia, pheochromocytoma, and adrenal insufficiency.

Primary hyperparathyroidism is caused by parathyroid adenoma, and characterized by abdominal groans, psychic moans, cystic bones, kidney stones and fatigue overtones. Primary increased activity of parathormone will cause osteitis fibrosa cystica, hypercalcemia, hypophosphatemia, nephrocalcinosis and stones.

Secondary hyperparathyroidism is a result of parathyroid hyperplasia in cases of vitamin D deficiency and chronic renal insufficiency, and characterized by accumulation of phosphates, hypocalcemia and bone demineralization.

Tertiary hyperparathyroidism: Long term stimulation of parathyroid glands may lead to development of autonomous activity, with persistent overproduction of the hormone, even after renal transplantation, leading to osteolysis and soft tissue calcification.

Male sexual development:

The normal development occurs as follows:

- 1- Chromosomal sex: 46XY
- 2- Gonadal sex: The hypothalamus- pituitary-testes axis
- 3- Phenotypic differentiation: Secondary sex characters
- 4- Gender assignment: Rearing as a male
- 5- Gender identity: Psychological sex is a reaction to social factors.

Abnormal development:

- 1- Undescended testis
- 2- Micropenis
- 3- Gynecomastia
- 4- Delayed puberty
- 5- Precocious puberty

Reproductive disorders in adults:

- 1- Hypogonadism
- 2- Impotence
- 3- Infertility
- 4- Gynecomastia

Table 7. Urogenital Features of Diabetes Mellitus

	Pathological features	Clinical features
Urinary bladder	UTIs Osmotic diuresis Diabetic cystopathy: Urothelial dysfunction Detrusor damage Neuropathy Vasculopathic disorder	Asymptomatic bacteriuria Symptomatic UTIs Emphysematous cystitis Polyuria LUTS Urine retention Incontinence Cystometry: Increased residual urine Impaired sensation Involuntary contractions Increased capacity Decreased contractility
Kidneys	Increased infections Diabetic nephropathy	Abscess formation Renal papillary necrosis Emphysematous pyelonephritis Infections with <i>Klebsiella</i> and <i>Candida albicans</i> Bacteremia Tuberculosis Microalbuminuria Chronic kidney disease
Genitalia	Men: Impaired neurogenic and endothelial – mediated relaxation of the cavernosal smooth muscles Female sexual dysfunction Increased infections	Erectile dysfunction. Disorders of desire, libido and orgasm. Retrograde ejaculation. Female disorders of desire and arousal; inhibited orgasm and sexual pain. Prostatitis & abscess formation. Epididymo-orchitis.

Fever is an increase in body temperature resulting from a cellular response to inflammation, immunological disorders or malignancy.

- Onset, duration, recurrences.
- Relation to urologic symptoms.

- Relation to pyuria: drainage of an abscess into the urinary tract leads to pyuria and fever diminishes.
- Associated symptoms e.g. neurological and gastrointestinal.
- **Chills:** Sensation of chilliness is a feeling of coldness occurring during a high fever because the inflammatory response releases chemicals that increase the set point for body temperature in the hypothalamus. Some cold receptors will discharge a brief action potential as a response to high temperatures, and this is known as paradoxical cold sensation.
- **Rigors** are uncontrollable shaking or shivering followed by excessive **sweating** that follows a rapid increase in body temperature (characteristic of acute pyelonephritis).
- **Causes of fever:**
 - a) **Inflammation of the urinary tract:** Acute infections of parenchymatous organs result in fever with chills.
Kidney: Acute pyelonephritis, renal abscesses
Prostate: Acute prostatitis and prostate abscess
Testis: Acute epididymo-orchitis
 - b) **Acute urinary tract obstruction:** In cases of infected hydronephrosis, pyonephrosis and emphysematous pyelonephritis; fever with chills indicate impending septicemia and require urgent management and relief of obstruction.
 - c) **Surgical and post-traumatic:** Patients with collection of pus have a high-grade swinging fever with rigors. Infected collections of blood or urine will also cause fever.
 - d) **Malignancy:** Kidney cancer will cause fever, particularly when it is metastatic or necrotic.
 - e) **CNS:** Head injury, cerebral hemorrhage
 - f) **Metabolic:** Acute gout
 - g) **Drugs:** Morphine, sulfonamides and hypersensitivity conditions

- **Causes of postoperative fever:**

Febrile postoperative patient who had surgery is presumed to have infectious complications until proven otherwise. Causes of post-operative fever include:

A. Infections related to original surgery:

- Wound infection
- Abscess formation
- Peritonitis

B. Hospital acquired (nosocomial) infections:

- UTIs
- Pneumonia
- Bacteremia
- Catheter infection
- Antibiotic-associated colitis

C. Non-infections causes:

- Systemic inflammatory response syndrome e.g. post-angioembolization
- Endocrinopathies: Adrenal insufficiency, thyrotoxicosis
- Drug reactions
- Transfusion reactions

- **Hypothermia:** Shock states, starvation, prolonged unconsciousness, and elderly immobile patients during winter and severe hypothyroidism

Genital infections:

- Urethral discharge, gonococcal infections
- Mumps may be complicated by orchitis.
- Sexually transmitted diseases (STDs)

Hypertension may cause chronic kidney disease and it may be a complication of a renal disorder. Endocrine hypertension is important. Hypertension and its medications may result in sexual dysfunction.

Hormonal hypertension of urologic importance:

High renin hypertension:

- 1) Renovascular abnormalities
- 2) Juxtaglomerular cell tumors are rare and benign. They occur in young people less than 20 years and are curable by surgical excision. There are high peripheral renin and secondary hyperaldosteronism leading to hypokalemia, nocturia and polyuria.
- 3) Bilateral endocrine dysfunction of the kidney
- 4) Renal tumors: Hypertension is the commonest paraneoplastic syndrome.

Low renin hypertension:

- 1) Conn's syndrome (primary hyperaldosteronism): Patients are usually women between the ages of 30-50 years. They have muscle weakness and cramps, hypokalemia, metabolic alkalosis and suppressed plasma renin levels. Nocturia and polyuria are also present. Secondary hyperaldosteronism can be due to renal artery stenosis, heart failure, and liver cirrhosis, pregnancy, and juxtaglomerular cell tumors. It is important to remember that essential hypertension treated with diuretics is the most common cause of hypokalemia. Therefore, in cases with hypertension due to Conn's syndrome, treatment with diuretics may precipitate muscle weakness and cramps.
- 2) Cushing syndrome
- 3) Congenital adrenal hyperplasia

High catecholamines:

A. Pheochromocytoma: Symptoms may be paroxysmal including:

Palpitations (fast forceful heartbeats),

Headache,

Episodic profound sweating (diaphoresis), and

Orthostatic hypotension: A fall in blood pressure upon standing from contraction of blood volume.

Pallor, tremors, anxiety and abdominal pain are found. The spells may be precipitated by physical exertion, anxiety or stress, changes in body position, bowel movement, labor and delivery, drugs e.g. anesthetic agents and metoclopramide, maneuvers that increase the intra-abdominal pressure e.g. lifting, exercise and trauma.

Hypertension resulting from PHEO is classified into:

Sustained hypertension	30%
Paroxysmal hypertension	30%
Combined sustained & paroxysmal hypertension	30%
Normotensive patients, incidental PHEO	10%

B. Neuroblastoma:

While hypertension is due to high levels of catecholamines in neuroblastoma, renin is responsible in children with nephroblastoma.

Infections of specific etiology:

Urogenital tuberculosis (TB) is a manifestation of a systemic disease. The age and sex incidence of urogenital TB parallels the primary pulmonary TB. Time lag between primary pulmonary TB and secondary urogenital TB is 5-10 years. The clinical and pathological features of urogenital TB are shown in table 8. Extrapulmonary sites account for 10 % of tuberculosis cases. Urogenital TB is responsible for 30-40% of extrapulmonary cases, second only to lymphatic tissue involvement. Symptoms arise when there is involvement of the urinary bladder. Where TB is concerned, the kidneys are mute and the urinary bladder plays the role of the vocal cords!

Table 8. Features of Urogenital Tuberculosis

	Pathological features	Clinical features
Primary sites	Renal TB is hematogenous secondary to spread of primary pulmonary or gastrointestinal TB. Glomerulus is the primary site. Ureteric and bladder TB is descending from kidneys. The epididymis and prostate are involved by hematogenous spread.	Underlying conditions are chronic alcoholism, diabetes mellitus, and immunodeficiency as HIV, malnutrition, and malignancy. Patients with history of pulmonary TB will develop sterile pyuria and hematuria. Constitutional symptoms: fatigue, weight loss, fevers.
Kidneys	Renal TB is always bilateral but the radiological brunt usually is apparent on one side. Granuloma (tuberculoma) Caseation Cavitation Calcification (curvilinear) Ulceration Fibrosis Autonephrectomy	TB is the great imitator. Renal mass problem with different features of TB kidney may be misdiagnosed as cancer. Renal failure occurs with bilateral renal or ureteric disease.
Ureters	Stricture formation: ureterovesical junction pelviureteric obstruction mid-ureteric multiple	Obstructive uropathy: hydronephrosis, pyonephrosis. Differential diagnosis of filling defects in urinary tract.
Bladder	TB bladder is secondary or iatrogenic caused by intravesical BCG. The bladder wall is red, inflamed, with ulceration, tubercles (yellow lesions with a red halo) and subsequent fibrosis.	Irritative LUTS Any patient with recurrent or relapsing UTIs, resistant to antibiotics. Sterile pyuria Secondary UTIs Contracted bladder: late
Male sexual organs	Granuloma, cavitation, calcification and fibrosis. Fistulas may form.	Painless epididymal mass adherent to posterior scrotum that may fistulize (scrofula). Extension to the testis may be misdiagnosed as testicular cancer. Thickened beaded vas. Azoospermia and infertility due to bilateral obstruction. Hard nodular prostate
Adrenal gland	Bilateral calcifications and hypofunction	Generalized lassitude Skin hyperpigmentation Addisonian crisis

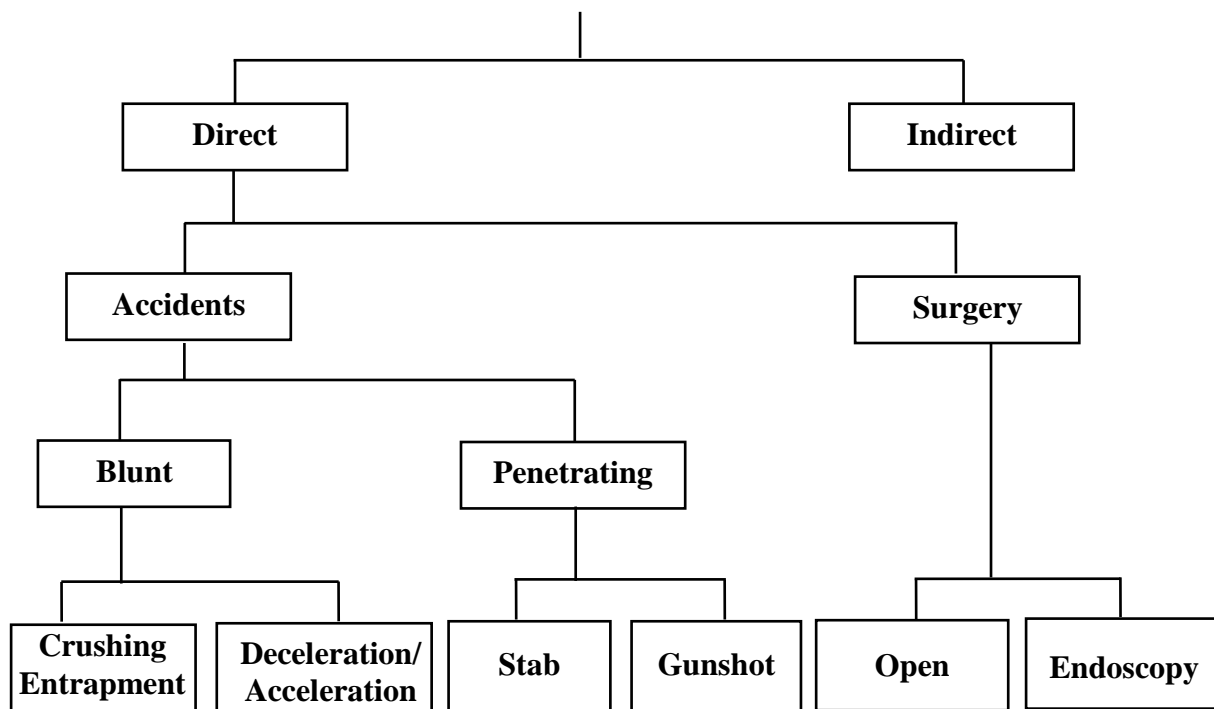
Past Surgical History

- Was the patient ever subjected to surgical operation(s)?
- When? List and date all previous operations.
- What? The type of the operation or instrumentation: Open versus endoscopic surgery. Urethral instrumentation, catheterization, and dilatation may cause UTIs or urethral strictures.
- Why surgery was performed? Indications of surgery are included.
- Where? Surgeon, hospital name and location should be listed.
- Were there any **complications**? Nature, management, and outcome, including problems with anesthesia.
- Reports, files and radiology of previous surgery are helpful. Contact with the surgeon may be necessary.
- All information should be correlated with the surgical scars on physical examination.
- Outcome of the surgical procedure.
- Possible additional management with surgery e.g. chemotherapy and radiotherapy for malignant disorders.
- Previous surgery has an impact on any subsequent operation, and may make it more difficult, especially if it was performed in the same anatomical area.

History of Trauma

- Trauma to the urinary tract gives a time for diagnostic procedures and decision making in the majority of cases.
- Poor management may result in a greater damage than the untreated primary injury.

Figure 7. Classification of Mechanisms of Urologic Injury



Mechanisms of trauma (Figure 7):

- **Blunt trauma** e.g. road traffic accidents:
 - **Crushing/entrapment** e.g. in straddle injury, the bulbar urethra is crushed between the hitting force and pubic bone.
 - **Deceleration** e.g. in motor vehicle accidents when deceleration occurs, the victim's body is thrown against the interior of the vehicle which had lost its movement. The extent of deceleration is crucial. Rapid deceleration may cause renal vascular damage, resulting in renal artery thrombosis, renal vein disruption, or renal pedicle avulsion.

- **Acceleration**, on the other hand, occurs when a pedestrian is struck by a fast-moving vehicle.
- **Penetrating injuries:**
 - **Gunshot** injury to the upper abdomen or lower chest may be associated with renal trauma. The weapon characteristics are important. The extent of injury is proportional to the kinetic energy (KE), which is mainly dependent on the bullet velocity (V). High velocity weapons produce the greatest soft tissue damage. The KE is proportional to bullet mass (M) x (V²). The degree of tissue destruction exceeds the pathway of the bullet, because of the change of kinetic energy into thermal energy.
 - **Stab wounds** result from assaults. The extent of tissue injury depends on the weapon length and width.
- **Iatrogenic injuries** are common in urologic practice e.g. urethral and ureteral strictures complicating surgical procedures.
- **Indirect trauma** is also important e.g. injury of the liver causing hemorrhagic shock may result in acute renal failure.

CHAPTER 5: FAMILY HISTORY

- Are there any diseases that run in your family?
- Ask about the age, health or cause of death of parents, grandparents, siblings, children, and grandchildren and close relatives.
- Genetically transmitted diseases of urologic importance:
 - Polycystic kidney disease
 - Tuberous sclerosis complex
 - Von Hippel-Lindau disease
 - Renal tubular acidosis
 - Cystinuria
- Alport's syndrome is a hereditary form of nephritis causing deafness and renal impairment.
- Diabetes and hypertension are common familial diseases but not due to a single gene disorder.
- Environmental risk: If a woman's husband died of lung cancer, she will be a passive smoker. Members of the same family may have the same life-style e.g. diet and sexually transmitted diseases, as risk factors for prostate cancer.
- Geneticists divide families into three groups, depending on the number of men with prostate cancer and their ages of onset:
 - a) **Sporadic** (by chance): A family with prostate cancer presents in one man at a typical age of onset.
 - b) **Familial**: A family with the disease present in more than one person, but with no definitive pattern of inheritance and usually an older age.
 - c) **Hereditary**: A family with prostate cancer in each of three generations on either the mother or father's side, or a cluster of two relatives affected at a young age (55 or less). 5-10% of prostate cancer patients have a hereditary form with earlier age of onset, due to DNA genetic mutations.

CHAPTER 6: SOCIAL HISTORY

Components include inquiries about:

1. Special habits to identify risk factors for particular diseases.

a. Smoking:

- Smoking is one of the leading causes of bladder cancer.
- It is also one of the risk factors of kidney cancer.
- Tobacco increases the likelihood of chronic kidney disease.
- Smoking increases the risk of erectile dysfunction.
- It can damage the genetic material in sperms which may cause infertility or genetic defects in children.
- Smokers who undergo surgery are more likely than nonsmokers to have complications (infections e.g. pneumonia, heart attack, stroke) or to die (cardiac arrest) shortly after surgical procedures.
- Past & present
- Active: quantify: 1 pack-year is 20 cigarettes per day for one year.
- Passive smoking

A strong warning should be given to the patient to stop smoking.

b. Alcohol alone is implicated in liver cirrhosis and may contribute to cancers of the breast and large bowel.

c. Opium

d. Illicit drugs are risk factors for HIV and hepatitis virus infections.

2. Overseas travel: Has the patient been abroad recently or spent any time abroad in the past?

3. Living conditions: Document details of patient's personal life which are relevant to the diagnosis.

4. Prison is predisposing factor for tuberculosis.

5. Religion

CHAPTER 7: SYSTEMATIC REVIEW

History taking includes "yes / no" questions about different systems, from crown to heel, to complete the interview.

- a) General: Changes in weight, appetite, weakness, fatigue, fever
- b) Head, eyes, ears, nose, and throat (HEENT)
- c) Skin changes
- d) Neck swellings
- e) Breasts lumps
- f) Cardiopulmonary: A relevant preoperative history includes information about symptoms suggesting an active cardiopulmonary disorder (e.g., cough, chest pain, dyspnea, ankle swelling) or infection.
- g) Gastrointestinal:
 - Difficult swallowing, nausea, vomiting,
 - Abdominal pain,
 - Distension,
 - Bowel movements, constipation, diarrhea,
 - Bleeding
 - Stool color, pain with defecation, rectal bleeding or black stools,
 - Jaundice, liver or gallbladder disease
- h) Peripheral vascular system: Intermittent claudications, leg cramps, varicose veins, swelling of legs, color and temperature changes of tips of fingers and toes
- i) Neurological: Headache, dizziness, weakness, paralysis, tremors or other involuntary movements, numbness or loss of sensation, fits, faints, changes in speech sphincter disturbances.
- j) Others: Musculoskeletal (muscle and joint disease), hematological diseases.

CHAPTER 8: INDIRECT UROLOGIC SYMPTOMS

1. Gastrointestinal symptoms of urologic diseases:

- Acute pyelonephritis is associated with generalized abdominal pain and distension.
- Ureteric colic is associated with nausea, vomiting and distension.
- Silent urologic diseases (e.g. hydronephrosis, staghorn stone, chronic pyelonephritis and cancer) may present with gastrointestinal symptoms that mislead the clinician.

Causes:

- A. Common sensory and autonomic innervations of the two systems.
- B. Peritoneal irritation by inflammation.
- C. Anatomical relationships.

2. Neurologic disorders:

A) Neurologic lesions cause urinary and sexual dysfunction:

- Diabetes mellitus
 - Multiple sclerosis: Urinary symptoms are the first manifestations in 5%.
 - Cerebro-vascular disease
 - Spinal cord injury
 - Parkinsonism
 - Meningo-myelocele
 - Spinal surgery
 - Inter-vertebral disc herniation
 - Pelvic surgery (hysterectomy, abdomino-perineal colo-rectal resection)
- B) Bladder dysfunction may result from poor voiding habits in children, aging and anxiety disorders.

3. Vascular disorders:

- **Hypertension** may be a manifestation of renal vascular disorders or adrenal masses.
- Symptoms in pheochromocytoma (**PHEO**):
 - P** **Palpitations (forceful heart beats)**
 - H** **Headache**
 - E** **Episodic sweating**
 - O** **Orthostatic hypotension**

- **Pregnancy-induced hypertension** or “**pre-eclampsia**” typically occurs in the third trimester and is distinguished from pheochromocytoma by the presence of proteinuria and the absence of paroxysmal symptoms. In cases of pheochromocytoma, hypertension can occur at any stage of pregnancy.

4. Congenital disorders:

- Adult polycystic kidney, von Hippel-Lindau and tuberous sclerosis complex are autosomal dominant diseases.
- Undescended testis and hypospadias have hereditary tendency.
- Congenital diseases are usually associated with other anomalies e.g. tuberous sclerosis patients present with adenoma sebaceum, epilepsy and mental retardation.

5. Symptoms of metastases:

- Bones: Pain, swelling, nerve compression, spontaneous fracture.
- Lungs: Persistent cough, hemoptysis, blood-staining, pleural effusion. The presence of cough is common and nonspecific in smokers. New and persistent cough should be evaluated.
- Liver metastases develop late symptoms.
- Brain: Headache, vomiting, visual disturbances, convulsions.
- Adrenal metastases are usually bilateral and primary tumors of the breast and lungs should be taken in consideration.

6. General symptoms:

- Hematologic: Anemia, easy bleeding, blood transfusions, transfusion reaction

Urologic complications of sickle cell anemia:

Recurrent priapism
Erectile dysfunction
Papillary necrosis

- Weight loss and cachexia in cases of malignant tumors
- Manifestations of uremia .

CHAPTER 9: ASYMPTOMATIC CASES IN UROLOGY

Many pathologic entities are clinically silent in urology, develop in asymptomatic behavior and diagnosed incidentally. Some important examples are shown in this section.

PROSTATE CANCER: Since the widespread use of serum PSA testing, and the implementation of screening programs for early detection, 50 to 60% of patients with prostate cancer are discovered incidentally. The possible clinical presentations can be grouped as follow:

- 1. Asymptomatic:** Men may be concerned and attend requesting for a prostate health check following the information about prostate cancer in the media. It is important particularly when any first-degree relative has developed the disease. The disease is detected by high PSA and/or abnormal DRE.
- 2. Manifest:**
 - Progressive LUTS due to coexisting BPH
 - Hematospermia
 - Perineal pain due to coexisting prostatitis
- 3. Complicated:**
 - Hematuria is due to coexisting BPH.
 - Symptoms of acute renal failure: Oliguria or anuria resulting from bilateral ureteral obstruction by the carcinoma.
 - Symptoms of chronic renal failure
 - Retention of urine (acute or chronic)
 - Intestinal obstruction may be caused by compression of the rectum.
- 4. Metastatic disease :**
 - Asymptomatic (occult)
 - Anorexia, anemia, asthenia
 - Bone aches and pathological fractures
 - Swelling of the lower limb due to lymphatic obstruction
 - Neurological manifestations due to spinal cord compression
 - Hemoptysis or dyspnea
 - Jaundice

KIDNEY CANCER:

1. Asymptomatic:

Kidney cancer used to be the internist's tumor, may now be the radiologist's tumor as more than 50% of cases are diagnosed incidentally on abdominal imaging carried out to investigate unrelated symptoms.

2. Manifest:

- Hematuria 50%, Loin pain 40%, Mass 30%
- Triad of pain, hematuria and mass in 10%
- Non- reducing varicocele due to obstruction of the testicular vein by tumor within the left renal vein or the IVC

3. Paraneoplastic syndromes (table 9):

The most common paraneoplastic syndrome with renal cell carcinoma is hypertension. Another important example is the Stauffer's syndrome, a reversible condition of hepatic dysfunction in the absence of liver metastases.

Table 9. Paraneoplastic Syndromes with Renal Cell Carcinoma

Syndrome		Causes
Hypertension	(40%)	Renin
Hypercalcemia	(10-20%)	PTH-like substance
Stauffer syndrome	(3-20%)	Granulocyte-macrophage CSF
Polycythemia	(3-10%)	Erythropoietin
Cushing		ACTH
Galactorrhea		Prolactin
Hypoglycemia		Insulin
Decreased libido, balding.		Gonadotropins
Gynecomastia, hirsutism, amenorrhea		

4. Metastatic disease:

- Metastatic symptoms: Lungs, bones, liver, brain
- Bilateral lower limb edema due to venous obstruction
- Fever, fatigue, weight loss, hemoptysis

ADRENAL INCIDENTALOMA:

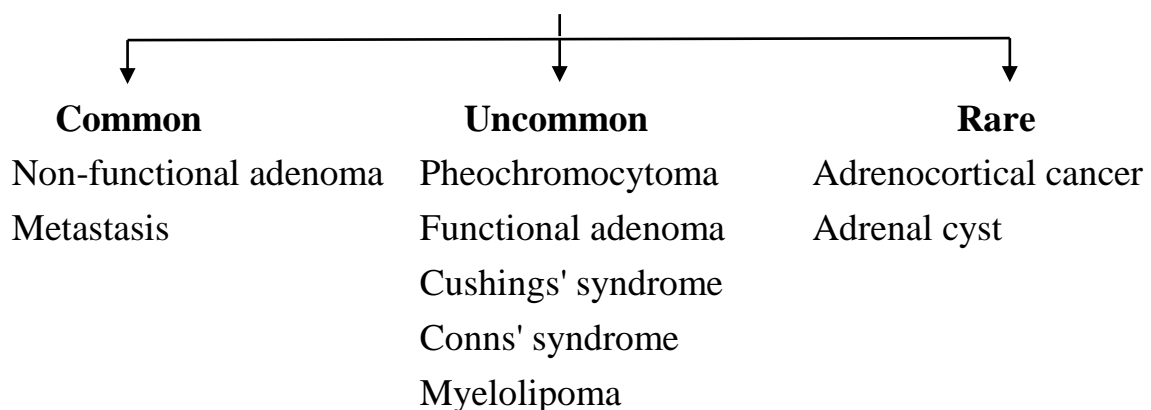
An incidentaloma is an adrenal mass, generally 1 cm or more in diameter that is discovered incidentally during imaging (Ultrasound, CT scan, and MRI) performed to investigate indications other than an adrenal disease. This definition excludes cases in which symptomatic adrenal-dependent disorders are "missed" because of an incomplete history taking and clinical examination. The majority of cases are clinically benign non-functioning adenomas (figure 8).

Functioning adrenal masses could be cortisol-secreting adenoma, pheochromocytoma, primary hyper-aldosteronism, and adrenal cortical carcinoma.

About 5% of all incidentalomas are pheochromocytomas, and about 25% of all pheochromocytomas are found incidentally. Myelolipomas are uncommon. Adrenal cysts are very rare.

History or diagnosis of an extra-adrenal cancer is important to consider a metastatic disease. Metastases to the adrenal gland from other primary tumors are more common than primary adrenal tumors.

Figure 8. Classification of Adrenal Masses



CHAPTER 10: HEMATURIA

Hematuria can be classified in different ways:

A) Intensity:

- 1- Gross or macroscopic hematuria: Urine is red and hematuria is visible to the naked eye. This is a "**red sign**" for the patient to ask for medical advice.
- 2- Microscopic hematuria is detected by microscopic urine analysis (the presence of >5 RBCs / hpf).

B) Origin:

- 1- Systemic disease
- 2- Urinary tract pathology

C) Relation to micturition:

- 1- Total hematuria is present all over the voided urine. Underlying pathology may be in kidney, ureter, bladder or prostate or systemic. Bleeding from kidney is associated with cylindrical worm-like clots. Hematuria from bladder and prostate is associated with big irregular or discoid clots.
- 2- Terminal drop hematuria, at the end of micturition, is of vesical origin e.g. active bilharzial cystitis. It is usually due to bladder neck or prostatic inflammation.
- 3- Initial hematuria at the beginning of micturition indicates urethral pathology.

D) Associated symptoms:

- Painless hematuria (no other urinary symptoms): All cases should be investigated for urologic malignancy. Bladder cancer is the most common cause of gross hematuria and should be excluded.
- Hematuria associated with other symptoms:

- Simple cystitis: Frequency, burning, urgency and suprapubic pain.
- Malignant cystitis: Severe frequency, suprapubic pain, urge incontinence, total hematuria with clots or necroturia.
- Ureteral obstruction due to blood clots is the most common cause of renal pain associated with gross hematuria.
- Stones: Renal pain
- BPH and prostate cancer are associated LUTS (prostatism).
- Surgical trauma to kidney and bladder e.g. PCNL & TURBT.

E) Etiologic:

I) General or systemic causes:

- Bleeding disorder: Thrombocytopenia, leukemia, hemophilia
- Liver cirrhosis
- Anticoagulants
- Hypertension

II) Renal causes:

a) Nephrologic: Dysmorphic red blood cells and proteinuria

- Glomerular disease e.g. acute glomerulonephritis (poststreptococcal) is the most common cause in children and young adults.
- Tubulointerstitial diseases: Papillary necrosis (Sickle cell disease, analgesic nephropathy), polycystic kidney disease, medullary sponge kidney.
- Vasculitis

b) Urologic: Normomorphologic RBCs

- Congenital: Polycystic kidney
- Inflammation: Pyelonephritis, TB.
- Trauma: Blunt and penetrating
- Stones
- Obstruction
- Kidney cancer & upper tract urothelial carcinoma

- Vascular diseases: Arteriovenous malformations, renal arterial aneurysms and pseudoaneurysms, thrombosis, hemangioma, Nutcracker syndrome, loin pain hematuria syndrome.

III) Ureteral:

- Stones
- Iatrogenic trauma e.g. ureteroscopy
- Tumors: Urothelial tumors
- Heavy bleeding can cause clot colic due to ureteric obstruction.

IV) Bladder:

- Bladder cancer is the most common cause of gross hematuria in a patient above the age of 50 years.
- Bladder cancer is the most common tumor in men in Egypt.
- Cystitis: Bacterial, bilharzial, TB.
- Stones
- Traumas e.g. post TURBT

V) Prostate

- BPH: Most common cause of gross hematuria in men above 60.
- Prostate cancer: In significantly locally-advanced disease.
- Prostatitis
- Iatrogenic e.g. after TURP.

VI) Posterior urethra:

- Inflammation
- Trauma
- Tumor

Differential Diagnosis:

Test the urine with a dipstick or microscopic examination before you settle on the term hematuria.

- **Red Urine (false hematuria):** No RBCs by microscopy
 - Hemoglobinuria → purple color
 - Food pigments(beetroots) → red translucent urine
 - Drugs: Rifampicin → red translucent urine

- **Urethral bleeding:** Suspect with blood present at the meatus in the absence of micturition and in case of initial hematuria.
 - Trauma: Most common cause in men. Iatrogenic e.g. catheterization & optical urethrotomy. Blunt trauma: The lesion is distal to the external urethral sphincter e.g. rupture anterior urethra due to falling astride. Blood is seen on the underwear without micturition.
 - Urethritis: Infections, chemical irritants, Reiter's syndrome
 - Urethral diverticulum
 - Urethral tumors
- **Factitious hematuria** is the presence of red blood cells in urine from a source outside the urinary tract e.g. vaginal bleeding. **Menstrual blood:** In women, be sure to distinguish it from hematuria.

Diagnosis:

A) History

- Age: < 40 years: inflammation, stones
 > 40 years: tumors
- Sex: BPH, prostate cancer in elderly men
- Trauma: Violence, accidents → blunt, penetrating
 Surgery: Open, endoscopic
- Bilharziasis and stone disease
- Systemic disease: liver cirrhosis
- Obstructive symptoms: BPH, prostate cancer

B) Physical examination:

- General: Hypertension, petechial hemorrhages
- Abdominal: Renal mass
- Genital: T.B. thickening and beading of vas
- DRE: Bladder mass, BPH, prostate cancer
- P.V.: Bladder mass

C) Investigations:**Laboratory:**

- Blood: CBC, liver function tests, creatinine, blood glucose
- Attention to platelets, prothrombin, clotting and coagulation times
- Urine analysis and culture: Microscopic hematuria with pyuria (UTI), crystals (stones)

Radiologic:

- Ultrasound: Renal masses, stones, polycystic kidneys, bladder mass
- KUB: Radio-opaque stones
- Non-contrast CT: Stone disease
- CT with contrast: kidney, ureteric, bladder and prostate cancer evaluation.

Endoscopic:

- Ureteroscopy: Stones and tumors of ureter
- Cystoscopy: Diagnostic and therapeutic in bladder cancer

Treatment**A) Emergency measures:**

- Blood transfusion if necessary
- Clot retention is an emergency condition.
- Clots are evacuated and triway 22 F urethral catheter is inserted with continuous irrigation.
- Cystoscopy and coagulation of the bleeding source e.g. bladder tumor, post- TURBT or TURP
- Arterial embolization is performed in significant hematuria after PCNL or kidney trauma
- Open surgery may be necessary if other measures fail.

B) Treatment of the cause

CHAPTER 11: ACUTE RENAL FAILURE

OLIGURIA AND ANURIA

- Anuria is complete absence of urine production by the kidneys for 12 hours or more.
- Oliguria is decreased urine volume to less than 400 ml in a day.
- Anuria and oliguria are symptoms of acute renal failure (ARF) which is divided into:

I- Prerenal ARF:

Pathophysiology:

Hypotension → shock → ↓ renal perfusion → ↓ GFR → ARF.

Causes:

1. Hypovolemia: Dehydration, prolonged vomiting, diarrhea, burns, excessive sweating.
2. Hemorrhagic shock: Trauma, surgery and postpartum.
3. Sepsis: Urinary and biliary
4. Cardiogenic shock: Myocardial infarction and pulmonary embolism.

Investigations:

1. Urine analysis: Oliguria, high specific gravity.
2. High serum creatinine.
3. Hyperkalemia and acidosis may complicate the condition.
4. Ultrasonography: Normal appearance of both kidneys.

Treatment:

Correct the shock

Treat the cause

II-Renal:

Intrinsic acute renal failure may be due to: acute glomerulonephritis, ATN, acute interstitial nephritis, infiltrative myeloma or lymphoma. ATN may be toxic, ischemic or combined.

Pathophysiology: Acute tubular necrosis (ATN) → oliguria → recovery within 2-3 weeks of proper management. Prolonged prerenal ARF resulting in prolonged renal ischemia may lead to ischemic ATN.

Causes of intrinsic acute renal failure (figure 9):

- 1- Nephrotoxic drugs given to patients with impaired renal function:
 - Aminoglycosides.
 - Prolonged use of NSAIDs.
 - Angiotensin – converting enzyme inhibitors (ACEIs)
 - Cisplatinum
 - Cyclosporine overdosage in kidney transplant patients.
- 2- Poisons.
- 3- Contrast media in patients with diabetes mellitus and multiple myeloma.
- 4- Anesthesia.
- 5- Eclampsia.
- 6- Incompatible blood transfusion.
- 7- Disseminated intravascular coagulopathy (DIC).
- 8- Myoglobinuria: Crush syndrome.
- 9- Kidney transplantation: prolonged ischemia, acute rejection, cyclosporine toxicity.

Investigations:

Urine analysis: low specific gravity, tubular cells.

Ultrasound: ↑ kidney size, no change in parenchymal architecture.

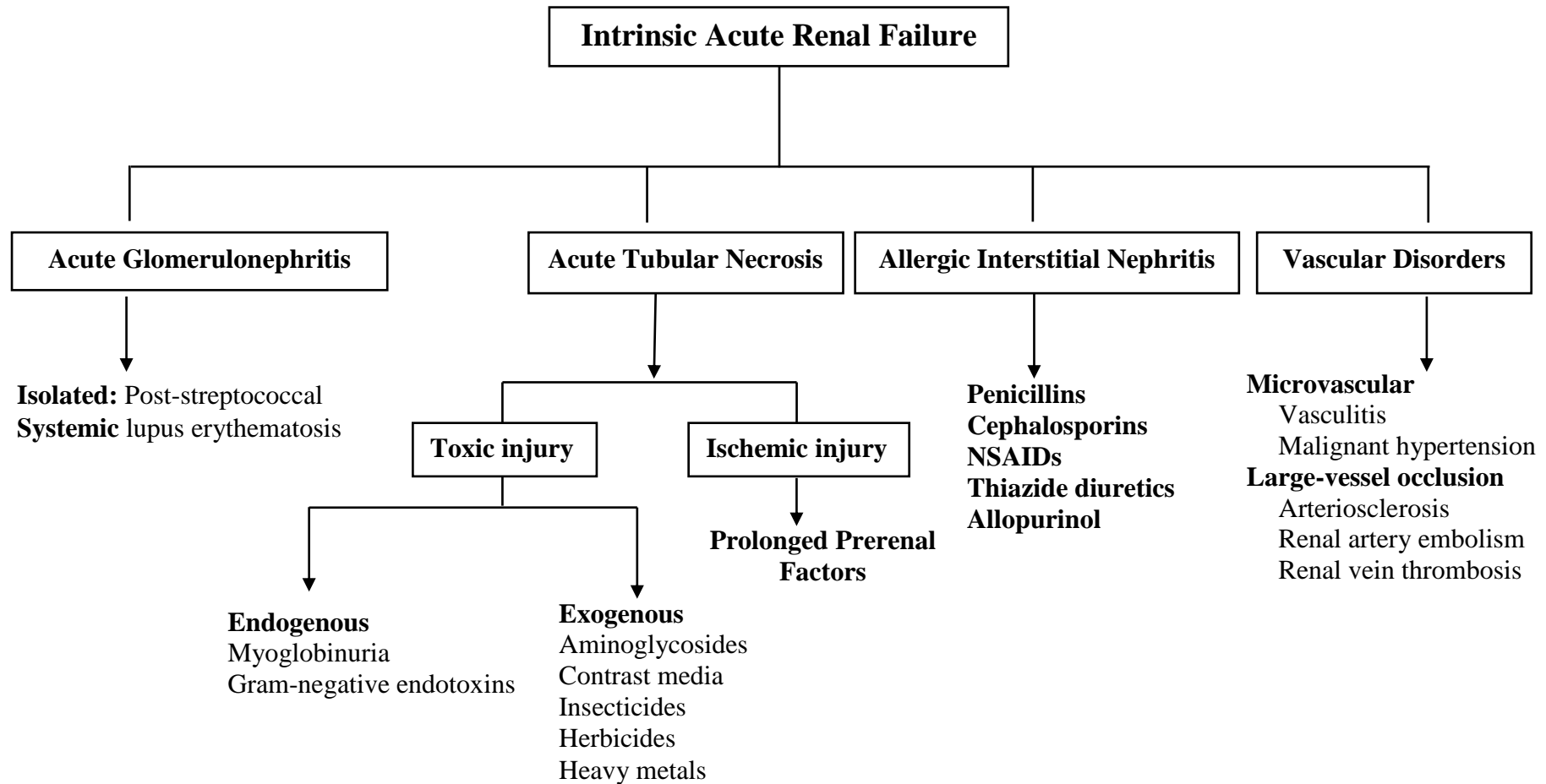
Fine needle aspiration biopsy (FNAB) in kidney transplant:

- Acute rejection: lymphoblastic cells.
- Cyclosporine toxicity: damaged tubular and endothelial cells.

Treatment:

- Fluid intake should be equal to daily urine volume + sweat + perspiration. Excessive intake may lead to congestive heart failure and pulmonary edema.
- ATN following kidney transplant should be differentiated from acute rejection and cyclosporine toxicity.
- Dialysis if the condition is prolonged.

Figure 9. Causes of Intrinsic Acute Renal Failure



III- Postrenal (obstructive) anuria:

The classic example is a stone impacted in the ureter of a solitary kidney (spasm of ureteral muscle, edema of the mucosa). There is renal pain and anuria. The urinary bladder is empty. There is circulatory volume and osmotic overload. Serum creatinine is rising and electrolyte imbalance will occur.

Causes:

- 1- Stones are the most common cause. The other kidney may be surgically absent or nonfunctioning.
- 2- Malignant tumors causing bilateral ureteral obstruction: prostate, bladder, cervix, rectosigmoid
- 3- Surgery e.g. bilateral ligation of the ureters during hysterectomy.
- 4- Retroperitoneal fibrosis.
- 5- Bilharzial ureteric strictures.
- 6- Crystaluria: uric acid crystals in patients receiving chemotherapy for lymphoma and leukemia.

History:

Renal pain or colic
 Anuria
 No desire to micturate
 Etiologic e.g. hysterectomy

Examination:

- The urinary bladder is empty on catheterization.
- Prostate, bladder, cervical or rectal tumors can be palpated.

Investigations:

- Serum creatinine is elevated.
- Electrolytes: Na, K, pH
 [Hyperkalemia > 7 mEq/l may lead to arrhythmia and cardiac arrest].

- Ultrasonography: Hydronephrosis, stones
- KUB: Radio-opaque stones
- Spiral CT: Stones, dilatation of pelvicalyceal system proximal to obstruction.

Treatment:

- Cystoscopy and ureteral catheterization to bypass the obstruction and drain the kidney.
- Percutaneous nephrostomy (PCN) if ureteric catheter fails.
- Treatment of the cause e.g. ureteroscopic stone removal.
- Postobstructive diuresis: Relief of obstruction is followed by diuresis due to volume and osmotic overload. Adequate fluid balance should be observed.
- Treatment of hyperkalemia:
 - a) Calcium resonium enema, intravenous injection of calcium to protect the heart from the toxic effect of hyperkalemia.
 - b) Glucose 25% with insulin to shift potassium from extracellular to intracellular fluid compartments.
 - c) Correction of acidosis
- Dialysis-indications:
 - Life threatening hyperkalemia
 - Uncontrolled acidosis
 - Congestive heart failure
 - Uremic encephalopathy

CHAPTER 12: ACUTE URINARY RETENTION

Acute urinary retention (AUR) is a sudden painful inability to urinate in spite of a full bladder due to complete obstruction of lower urinary tract. Relief of pain follows drainage by catheterization.

Normal micturition cycle:

Filling phase: Impulses from the CNS to sympathetic and pudendal nerves relax the bladder and close the outlet.

Voiding phase: Inhibition of the sympathetic and the pudendal nerve impulses, and stimulation of parasympathetic motor nerves (S2-4) will lead to detrusor contraction and urination, if the lower urinary tract is free of obstruction.

Causes:

A. Mechanical or obstructive:

1- Bladder:

- Stone, bladder neck obstruction, cancer

2- Prostate:

- BPH is the most common cause of AUR in men over 50 years.
- Acute prostatitis and abscess
- Prostate cancer

3- Urethra:

- Stone, stricture, urethritis, injury, phimosis, posterior urethral valves.

4- Clot retention in severe hematuria e.g. cancer, trauma.

5- Women: pelvic masses, urethral stenosis and diverticulum, pelvic prolapse, hysterical.

B. Functional and neurogenic:

1- Postoperative AUR is common:

- Pain, limited mobility, drugs, bladder nerve injury e.g. hysterectomy and resection of the rectum.
- Prevention is important by catheterization after surgery to bladder, prostate, urethra.

2. Drugs: Anesthetics, anticholinergics, sympathomimetics

3- Neurogenic:

- a. Spinal cord injury.
- b. Diabetic neuropathy.
- c. Cauda equina lesions.
- d. Intervertebral disc prolapse.
- e. Neurotropic viruses: Herpes simplex or zoster.
- f. Multiple sclerosis.
- g. Transverse myelitis.
- h. Tabes dorsalis.

History:

- Cause- related:
 - A complication of BPH
 - Drugs
 - Urethral trauma
 - Stone disease
- Suprapubic bursting pain, no urine, strong desire to urinate.
- Acute urine retention should be differentiated from obstructive anuria (table 10).

Abdominal examination: The full bladder is felt as a midline globular tender mass in the suprapubic region.

Genital examination: Phimosis, severe urethral meatal stenosis.

DRE: BPH, prostate cancer.

Table 10. Differential Diagnosis of Acute Retention and Obstructive Anuria

	Acute urine retention	Obstructive anuria
Desire to urinate	Yes	No
Suprapubic pain	Yes	No
Renal pain	No	Yes
General examination	Good	May be uremic
Abdominal exam.	Full bladder	Empty bladder Tender loin
Emergency measures	Urethral or suprapubic catheter	Ureteral catheter / DJ stent / ureteroscopy / PCN if ureteral manipulations fail.

Treatment:**A) Conservative measures in non-obstructive causes:**

- Patient is asked to go out of bed.
- Hot bath.
- Parasympathomimetics.
- Failure → catheterization.

B) Urethral catheterization: Nelaton or Foley's:

- It is absolutely contraindicated in urethral injury.
- Sterilization
- Adequate lubrication
- Gentle manipulation
- Proper catheter size selection

Children	6-12 F
Adults	16 F

Catheter caliber is standardized in French (F) units, also known as Charriere (Ch) units. Each unit is 0.33 mm, so a 14-F catheter is 4.6 mm in diameter. The circumference of a catheter circular cross section, expressed in French units, is approximately a threefold of the diameter. Therefore, an 18-F catheter has a circumference of 18 mm, and a diameter of about 6 mm, and a radius of 3 mm.

Clot retention:

- Triway 22F urethral catheter with irrigation.
- Evacuation of clots.
- Cystoscopy diagnostic and therapeutic.

C) Suprapubic cystocath:

- Urethral trauma
- Urethral stricture
- Failure of urethral catheterization

D) Treatment of the cause e.g.

- TURP for BPH
- Endoscopic urethrotomy or urethroplasty for urethral stricture.
- Endoscopic crushing of vesical stone.

Chronic Retention of Urine

It is a gradual development of a painless full bladder due to chronic incomplete obstruction of lower urinary tract, characterized by involuntary dribbling of urine (false or overflow incontinence).

Causes: Long standing incomplete obstruction

- **Mechanical :** BPH, prostate cancer
- **Functional:** Neuropathic flaccid bladder
- Large amounts of residual urine exist in the urinary bladder.
- When the vesical pressure exceeds the urethral resistance, the patient will pass some urine or dribble continuously. This condition is called false or overflows incontinence.

Complications: Bilateral hydronephrosis & uremia.

Treatment:

- Urethral catheterization is done if upper urinary tract deterioration exists.
- Investigation for the cause.
- Treat the cause.

CHAPTER 13: GENERAL EXAMINATION

Urologist should ensure that no part of the physical examination is missed. General principles, to have adequate relaxation and maximize patient comfort, are applied during examination and include the following:

- Good light, warm room.
- Full exposure from nipples to knees.
- Supine position, head supported by a pillow and knees are slightly flexed with feet on table.
- Arms across chest or on sides.
- Watch the patient face for signs of pain.
- Explain what you are about to do and ask permission.
- Look, listen then feel and percuss.
- The painful area should be examined last.
- Stand on the right side of the patient.

General Appearance: Development, nutrition (well-nourished versus cachectic), mood (calm versus anxious), level of consciousness (alert versus obtunded), apparent age, position in bed, degree of illness (acute versus chronic), and the presence of obvious abnormalities. Note gait, motor activity, dress, and personal hygiene.

Performance Status: It is important to assess the performance status as an attempt to quantify the general well-being of patients. There are various scoring systems (table 11). The most commonly used are the Karnowsky and the Zubrod scores. The Karnowsky performance score is a standard method which measures the ability of patients to perform ordinary activities of daily life and is used to determine whether cancer patients can receive certain treatments and may be used to determine prognosis. The Karnowsky performance scores range from 0 to 100. A higher score means the patient is better able to carry out daily activities. It is also used in oncological randomized studies to assess the quality of life.

Table 11. Performance Status

ECOG/WHO/Zubrod Score		Karnowsky Performance Score	
Normal activity	0	Normal, no evidence of disease Able to perform normal activity with only minor symptoms	100 90
Symptomatic and ambulatory Cares for self	1	Normal activity with effort, some symptoms Able to care for self but unable to do normal activities	80 70
Ambulatory >50% of time Occasional assistance	2	Requires occasional assistance, cares for most needs Requires considerable assistance	60 50
Ambulatory \leq 50% of the time Nursing care needed	3	Disabled, requires special assistance Severely disabled	40 30
Bedridden	4	Very sick, requires active supportive treatment Moribund	20 10

VITAL SIGNS: Temperature, pulse, blood pressure, respiratory rate, height, and body weight should be recorded.

Temperature:

- Recording will depend on the site of measurement. Normal oral temperature is 37°C (36.5-37.2°C). Rectal temperature is 0.5 °C higher. Axillary temperature is 0.5 °C lower than oral and is extremely inaccurate.
- Causes of falsely low oral temperatures include tachypnea with respiratory rate more than 20, recent ingestion of cold substances, or failure to keep the lips closed. Causes of falsely high oral temperatures include failure to shake down the thermometer, ingestion of hot substances, or smoking.
- Average oral temperature of 37°C equals 98.6 °F. The temperature conversion between in degrees of Centigrade and Fahrenheit is through the formula:

$$T^{\circ}\text{F} = 9/5(T^{\circ}\text{C}) + 32 \quad \text{or} \quad T^{\circ}\text{C} = 5/9 [(T^{\circ}\text{F}) - 32]$$

Radial Pulse:

Radial pulse is used to assess the heart rate.

Frequency: A rate faster than 100 beats/minute is considered a tachycardia; and below 60/minute is a bradycardia.

Regularity: The normal pulse is regular when each beat comes at the expected time. Arrhythmias can be regular irregularities or irregular irregularities.

Volume: Amplitude and contour of the pulse wave

Arterial Blood Pressure: Hypertension of urologic importance (p 37).

Respiratory Rate:

- Normally, adults have 12-20 quiet, regular breaths per minute; while children have higher rates.
- Tachypnea is a rapid shallow breathing is seen in pleural chest pain and restrictive pulmonary disease.
- Hyperpnea is a rapid deep breathing as in anxiety and exercise.
- Kussmaul respiration is a deep sighing breathing in metabolic acidosis which may have normal, fast or slow rate.
- Bradypnea is a slow breathing as in diabetic coma and respiratory depression due to drugs.
- Cheyne-Stokes respiration is rhythmic alternating periods of hyperpnea and apnea seen in uremia and respiratory depression due to drugs.

Neurological examination should be performed in patients with any indication from the history to have a possible neurologic defect. Sensory deficits in the penis, scrotum, labia, vagina, and perianal area generally indicate damage or injury to sacral roots or nerves. The important reflexes are the bulbocavernosus reflex (BCR), and the cremasteric reflex will be discussed later.

Urinalysis: Chemical and microscopic urine analyses should be performed because this may provide data critical to diagnosis and treatment of urologic patients.

EXAMINATION OF THE HEAD

A. Examination of the Face:

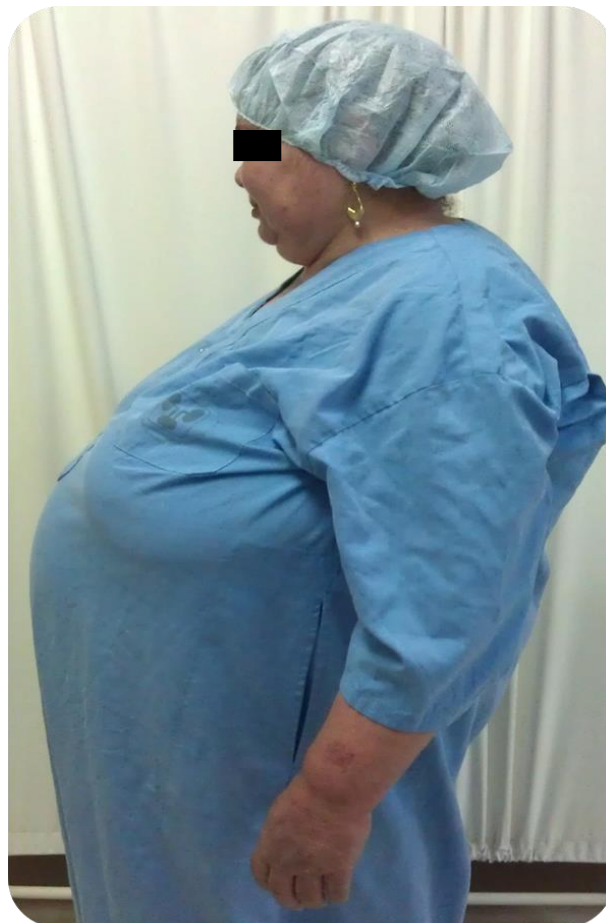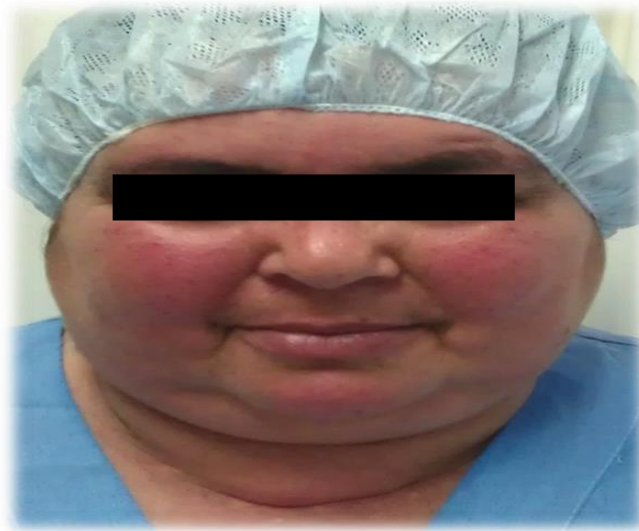1- Uremia:

- Sallow complexion (a dirty brown appearance, muddy face or uremic tinge) due to impaired excretion of urochromes and anemia.
- Uremic frost is a white crystalline deposit seen especially on the face of undialyzed patients with uremia who are comatose.
- Hyperventilation due to metabolic acidosis
- Hiccup
- Uremic fetor: Ammoniacal fish breath due to breakdown of urea
- Puffy face due to salt and water retention; pallor due to anemia
- Eyes: Anemia, jaundice, and band keratopathy: calcium deposition beneath the corneal epithelium in line with the inter-palpebral fissure due to excessive calcium replacement or hyperparathyroidism.
- Muscle twitches due to tetany and epilepsy
- Subcutaneous nodules (calcium phosphate)

2- Cushing's syndrome (figure 10):

- Patient may be asymptomatic.
- Symptoms may include weight gain with central obesity, plethora, moon face, supraclavicular and dorsocervical pads of fat. Acne hirsutism may appear. Purple striae, thinning of skin, and easy bruising are found with poor wound healing. Also proximal muscle weakness is observed. Osteoporosis and fractures may result.
- Patient may have emotional and cognitive changes e.g. depression, irritability, restlessness, and spontaneous tearfulness.
- Hypertension and diabetes mellitus
- Opportunistic and fungal infections

Figure 10. Features of Cushings' syndrome: Plethora, rounding of a full moon face, supraclavicular and dorsocervical fat pads and central obesity, are observed in a female aged 43.



3- Tuberous Sclerosis Complex (figure 11): TSC is a rare multi-system genetic disease that causes benign tumors to grow in the brain, kidneys, skin, heart (rhabdomyomas), eyes, and lungs (multiple cysts). The disease is characterized by:

- Autosomal dominant pattern of inheritance
- Adenoma sebaceum (facial angiofibromas) appears as reddish spots in a butterfly distribution on the cheeks, nose and nasolabial folds.
- TSC may be associated with tumors of the central nervous system: Giant cell astrocytoma, cortical tubers, and sub-ependymal nodules that develop in the walls of ventricles. These lesions may lead to: Mental retardation, learning difficulties, hydrocephalus and epilepsy
- Bilateral multiple renal angiomyolipomas (AML): Although benign, an angiomyolipoma larger than 4 cm is at risk for a potentially catastrophic hemorrhage either spontaneously or with minimal trauma.
- Approximately 20-30% of patients with TSC have renal cysts.
- Hypertension, renal impairment, and kidney cancer or oncocytoma (<2% of TSC cases) can occur.

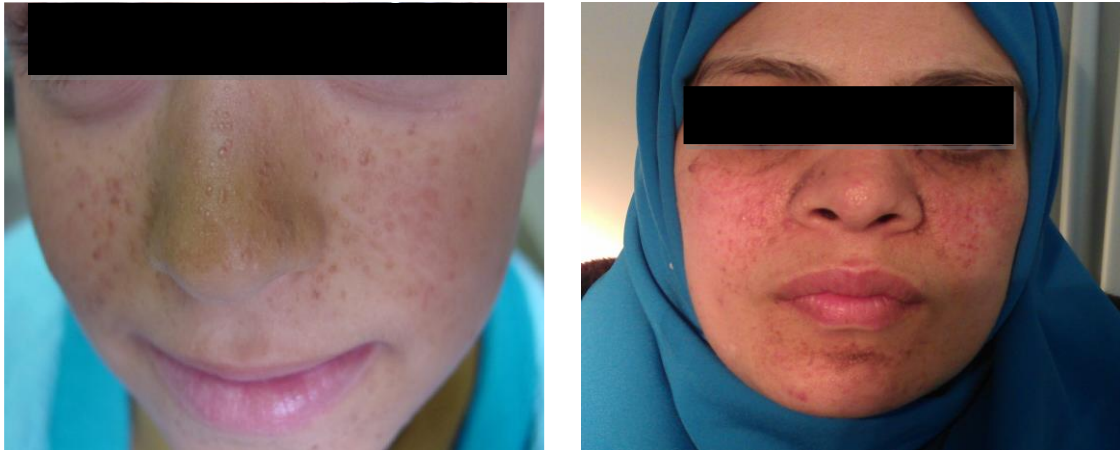4- Birt - Hogg - Dubé Syndrome (figure 12):

This is a rare disorder with autosomal dominant pattern of inheritance, which is characterized by:

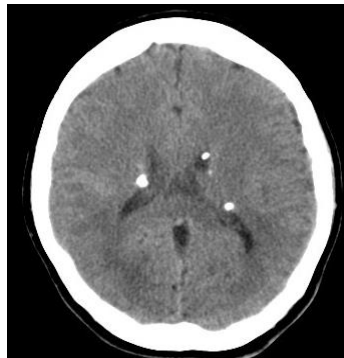- a) Cutaneous nodules: Hair follicle tumors (fibrofolliculomas) on the face and neck
- b) Bilateral multifocal renal tumors typically include chromophobe RCC and oncocytomas.
- c) Pulmonary cysts which may cause spontaneous pneumothorax.

Figure 11. Features of Tuberous Sclerosis Complex

A) Adenoma sebaceum



B) CT brain: sub-ependymal nodules (tubers)



C) Bilateral multiple renal angiomyolipomas

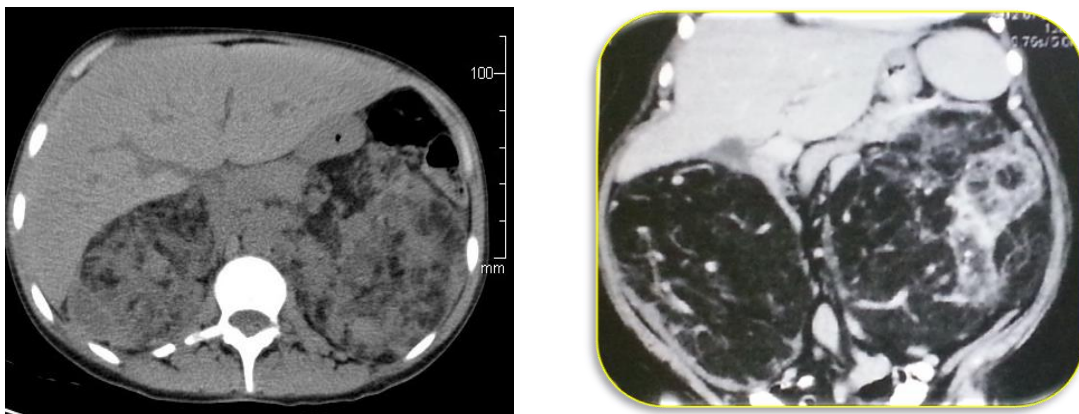
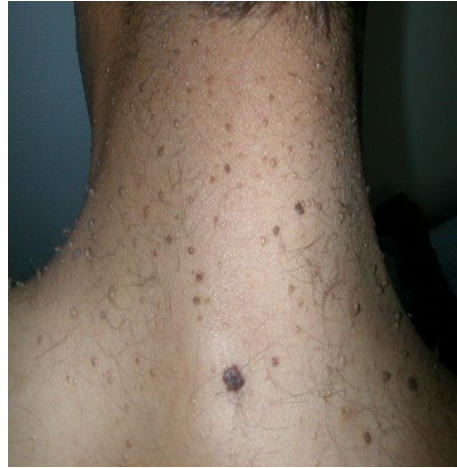
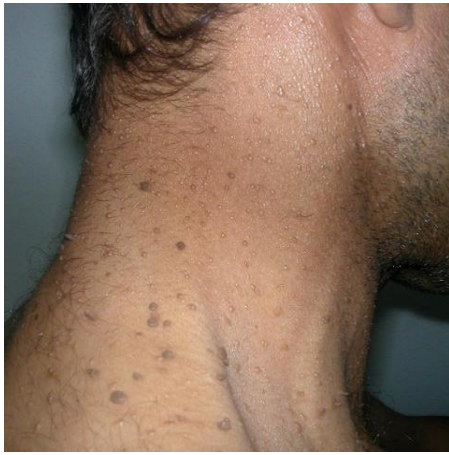
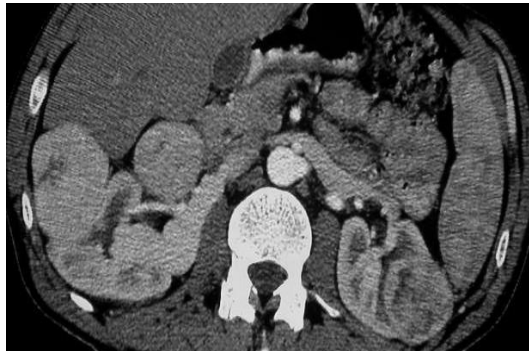Figure 12. Features of Birt - Hogg - Dubé Syndrome

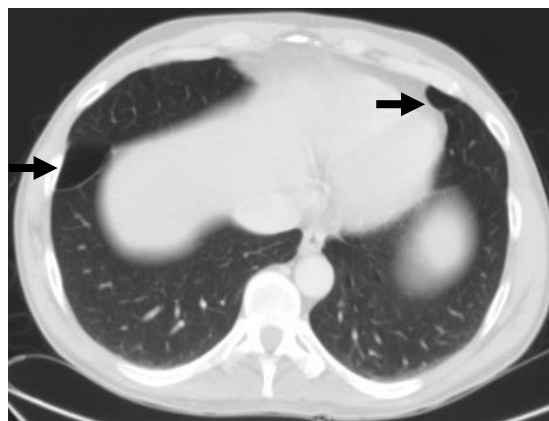
(A) Cutaneous nodules: Hair follicle tumors (fibrofolliculomas) on the neck



(B) Bilateral renal tumors



(C) Pulmonary cysts



B. Skull:

- Size, contour, and tenderness
- Examine the hair and scalp.

C. Eyes:

- Visual acuity and fields
- Observe the eyelids, sclera, and conjunctiva of each eye.
- Inspect cornea, iris and lens.
- Compare the pupils for size, equality, regularity, and reactions to light.
- Assess the extraocular movements.
- Ophthalmoscopic inspection of the ocular fundi

D. Ears:

- Inspect the auricles, canals, and drums. Check for the hearing acuity.

E. Nose:

- Inspect the nasal mucosa for obstruction, polyps, discharge. Palpate the frontal and maxillary sinuses for tenderness.

F. Mouth and Throat:

- Lips: Color and lesions
- Tongue: Size, position, tremor, papillae, color, and coating
- Teeth: Number, condition, and alignment
- Gums: Pigmentation, ulceration, bleeding, and infection
- Buccal mucosa: Eruptions or pigmentation
- Throat: Inspect the palate, tonsils, and pharynx.

INTEGUMENTS

A. The skin is examined for color (pallor, jaundice, cyanosis, pigmentation, and erythema), temperature, texture (softness or roughness), moisture or dryness, eruptions, petechia, nodules, and scars. Describe any lesions for their location, distribution, arrangement, type, and color. Study the patient's hands.

1- Pallor:

- The normal conjunctiva is red pink in the palpebral part and creamy in the sclera. This difference is absent in significant anemia.
- The palmar skin creases and nail beds are inspected.

2- Jaundice is yellowish pigmentation of the skin, sclera and mucous membranes due to increased bilirubin, which is best appreciated in natural daylight.

3- Cyanosis is bluish discoloration of the skin and mucous membranes due to increased deoxygenated hemoglobin in blood.

- Central cyanosis: blue tongue & periphery:
 - Chronic obstructive pulmonary disease.
 - Massive pulmonary embolism.
 - Cyanotic congenital heart disease.
 - Polycythemia.
 - Met- and sulph-hemoglobinemia.
- Peripheral cyanosis: blue fingers and toes:
 - All causes of central cyanosis.
 - Exposure to cold.
 - Reduced cardiac output (shock, left ventricular failure).
 - Peripheral vascular obstruction.

4- Pigmentation :

Diffuse hyper-pigmentation: Jaundice, chronic adrenocortical insufficiency

Focal hyper-pigmentation: In patients with chronic adrenocortical insufficiency pigmented spots appear in the buccal mucosa.

Erythema means redness that can be generalized or localized.

5- Skin tumors:

Malignant melanoma

Squamous cell and basal cell carcinoma

Kaposi's sarcoma (figure 13) consists of purple masses, which are sometimes scaly. The disease is the most common malignancy in renal transplant recipients in the Middle East, and is also seen in association with HIV.

6- Lesions due to bleeding problems:

Petechia is a pinpoint (less than 1mm) red hemorrhage which does not blanch with pressure. Petechiae signify a platelet or capillary disorder.

Ecchymosis is a bloody extravasation distinguished from a petechia by size greater than 1mm. Ecchymoses signify large vessel bleeding from trauma or clotting factor deficiency.

Purpura is a large hemorrhage which undergoes a change into purple color.

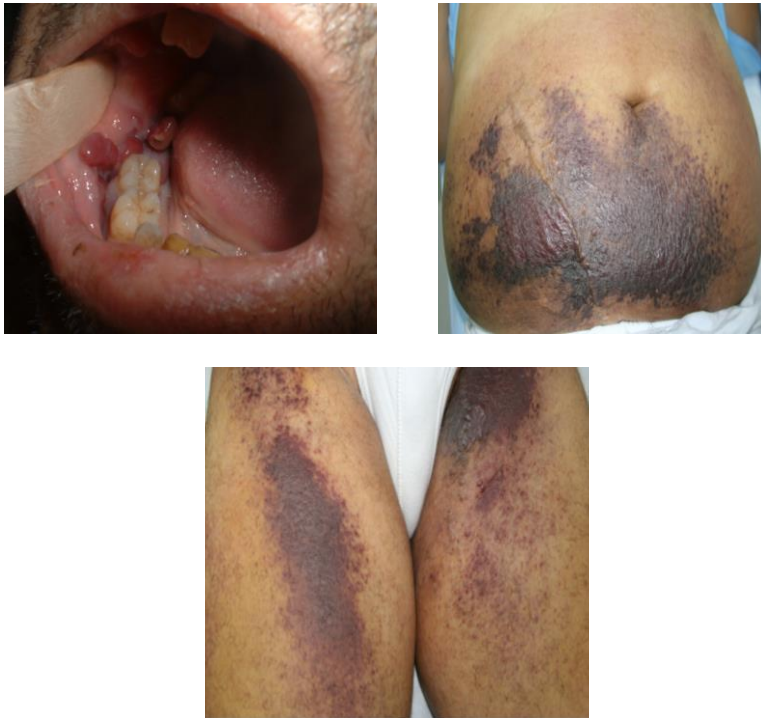B. Hair:

Distribution (patchy or total alopecia), texture (fine or coarse), quantity (thin or thick), and color

C. Nails:

Color (cyanosis, pallor), shape (clubbing), texture, lesions (paronychia, subungual hemorrhages).

Figure 13. Kaposi sarcoma: A 52 year old man who had received a right renal allograft in 2005. Two years later, he developed buccal nodules, multiple skin lesions in the abdomen and upper thighs, and melena (courtesy of Dr H. Sheashaa).



NECK EXAMINATION

Examination of the neck: Contour, mobility, tenderness, masses; thyroid size, consistency; unusual pulsations; tracheal position; salivary glands; cervical lymph nodes.

Inspection:

- Sit the patient with the head looking straight ahead.
- Look for overall symmetry and lumps.
A lump in or close to the midline suggests a thyroid lesion which moves with swallowing.
- Skin ulcers or sinuses suggest TB.
- Venous engorgement.

Palpation:

- Systematic palpation: Anterior triangle (\pm swallowing), submental and submandibular areas, posterior triangle and the supraclavicular fossae.
- Thyroid lumps: Move behind the sitting patient to feel the thyroid gland.
Is a lump unilateral or bilateral? Does it move with tongue protrusion?
- Carotid arteries: Are they normal, dilated or aneurysmal?

Cervical lymph nodes:

- Describe any palpable cervical lymph nodes for size, consistency, tenderness, mobility, and sinuses.
- The left supraclavicular nodes are the landing sites for metastases from abdominal and pelvic organs.

BODY HABITUS

BODY MASS INDEX (table12):

The ratio of weight in kilograms to height in meters squared is a common tool to assess the body habitus.

$$\text{BMI} = \text{Weight (kg)} / \text{Height}^2 \text{ (m)}$$

Table 12. Classification of Body Built According to BMI

Description	BMI (kg/m ²)
Underweight	<18.5
Normal	18.5-24.9
Overweight	25-29.9
Obesity	
○ mild (class I)	30-34.9
○ moderate (class II)	35-39.9
○ morbid (class III)	40 or more

Information on waist circumference refines associated disease risks. A circumference greater than 102 cm in men or 88 cm in women indicates increased metabolic risk.

OBESITY:

- Obesity increases risk for almost all types of cancer, reproductive disorders, hypertension, diabetes mellitus, cardiovascular disease, stroke, sleep apnea, lumbosacral disk disease, osteoarthritis, gastro-esophageal reflux and gallstones.
- Obesity has a causal relationship to urinary incontinence and infertility.
- Obesity obscures intra-abdominal physical signs, increases difficulties in surgical operations and post-operative complications.

- Causes of obesity:

- Simple: Overeating
- Endocrine:
 - Cushing's syndrome
 - Hypothyroidism
 - Hyper-insulinism
 - Hypogonadism
- Drug- induced: Corticosteroids, LHRH agonists
- Genetic

WEIGHT LOSS:

- There is muscle weakness and prominent bones (cheek, humoral head, major joints, rib cage, pelvis)
- Causes:
 - Malnutrition
 - Malignancy
 - Renal failure
 - Gastrointestinal disease
 - Sepsis
 - Trauma
 - Post-surgery
 - Psychological

Malignant cachexia:

- Marked loss of weight suggested by clothes.
- Features:
 - Emaciated facies
 - Loose, wrinkled dry skin
 - Mouth infection thrush
 - Loss of energy and appetite
 - Ascites

DEHYDRATION:

- Clinical features appear when there is loss of about 4 liters in an average adult (6% of 70 kg body weight). There is loss of sodium chloride and water.
- Assessment is essential in excessive vomiting, diarrhea, sweating, polyuria and fever.
- Features:
 - Thirst.
 - Sunken eyes.
 - Weight loss.
 - Muscle weakness.
 - Skin turgor is unreliable: Gentle skin pinching of neck or chest wall leads to slow subsidence (the sign of the ridge)
 - The skin is dry and wrinkled.
 - Dry mucous membranes.
The tongue may be dry due to mouth breathing.
 - Postural hypotension.
 - Tachycardia.
 - Assessment of JVP is the most sensitive way.
 - JVP is decreased, collapsed veins.
 - Dry axillae.
 - Axillary palpation shows sweating in well- hydrated patients.
 - Concentrated urine, oliguria.

EDEMA:

Lower limb edema is found as swelling of tissues due to an increase in the interstitial fluid that can be detected by pitting of the skin on pressure, pretibially. Myxedema due to hypothyroidism and chronic lymphedema do not pit. The differential diagnosis of pitting edema is shown in figure 14.

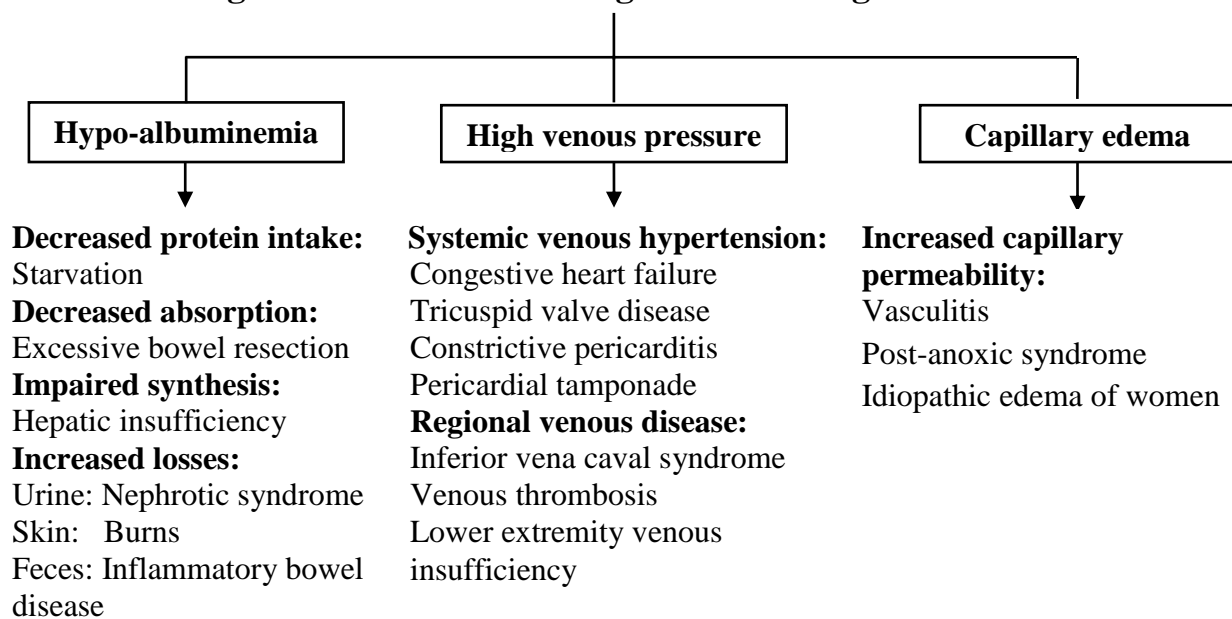
A. Unilateral leg edema:

This is caused by venous or lymphatic obstruction.

- Cellulitis: redness, hotness, tenderness

- Compression of large veins:
 - Tumors e.g. pelvic tumors.
 - Enlarged lymph nodes.
 - Scar tissue post surgery and irradiation.
- Phlebo-thrombosis
- Immobility e.g. hemiplegia
- Trauma
- Filariasis
- Hereditary edema of one or both lower limbs (Milroy's disease)
- Liver cirrhosis: marked ascites, moderate edema of lower limbs and signs of liver failure
- **Renal diseases:**
Nephrotic syndrome:
 - Massive peripheral edema
 - Hydrothorax and ascites
 - Proteinuria > 3.5 g/day, Hypoalbuminemia <3 g/dL
 - Hyperlipidemia, Lipiduria

Figure 14. Differential Diagnosis of Pitting Edema



B. Bilateral leg edema:

- Systemic causes (hypo-proteinemia, fluid overload)
- Congestive heart failure: Congested neck veins, enlarged tender liver and orthopnea

Acute glomerulonephritis:

History of streptococcal infection

Mild generalized edema with puffy eye-lids

Hematuria

Flank pain and oliguria

Moderate to marked hypertension

Elevated antistreptolysin O titer, hypocomplementemia

- Gastrointestinal:
 - Excessive bowel resection
 - Crohn's disease
 - Protein-losing enteropathy
- Drugs:
 - NSAIDs, corticosteroids
- Bilateral venous or lymphatic obstruction:
 - IVC obstruction in kidney cancer
 - Filariasis

LYMPHEDEMA is a term reserved for accumulation of interstitial fluid in cases of pure lymphatic disease. It may be classified by age onset and etiology into idiopathic, infectious, and malignant. After the age of 50 years, malignancy is the main cause, and in men, prostatic carcinoma infiltrating the lymphatic drainage is the most likely etiology. When it occurs in women, it is usually due to lymphoma.

LYMPH NODES

Anatomical background of the lymphatic system

Primary landing sites: Lymphatic drainage of the lower limbs, external genitalia, pelvic organs, intestines, testes, kidneys, and liver follows the vascular supply to the retroperitoneum.

The lymphatics of prostate and urinary bladder drain through the internal and external iliac lymph nodes as well as the obturator group. These groups proceed in ascending pattern to the common iliac, to the retroperitoneal (pre-, right, post, and left) para-aortic lymph nodes which are the primary landing sites for metastatic renal, adrenal, and testicular tumors.

Left-sided testicular tumors spread to the left side of the retroperitoneum and in the interaortocaval area. Right-sided tumors can cross over and involve the left side of the retroperitoneum. Therefore, the templates for retroperitoneal lymph node dissections are different, based on whether the tumor is from the left or right testis.

The inguinal lymph nodes are the landing sites for scrotal and penile cancer. The superficial lymphatics drain into the inguinal lymph nodes (horizontal and vertical groups). The deep lymphatics drain along the femoral vessels into the iliac lymph nodes.

The cisterna chyli is a dilated sac, on the right side of the abdominal aorta, overlapped by the right crus of the diaphragm. It receives afferents from right and left para-aortic (lumbar) and intestinal lymphatic trunks.

The thoracic duct is the continuation of the cisterna chyli and enters the thorax through the aortic opening. It ascends in the mediastinum to enter the neck to terminate finally in the angle between the left internal jugular and subclavian veins i.e. the beginning of innominate vein. It conveys most lymph of the body to the venous system from the lower limbs, pelvic and abdominal cavity, and left side of thorax, left side of head, neck, and left upper limb.

General principles of examination of the lymph nodes

Normal glands in adults are seldom greater than 0.5 cm in diameter. Enlarged lymph nodes are usually of clinical importance in malignancy and lympho-proliferative disorders.

Inspect, palpate and compare with the other side in a systematic pattern:

1. Site (cervical, axillary, abdominal, inguinal, popliteal)
2. Size: Precise measurement in cancer patients is an index of therapeutic response
3. Tenderness indicates inflammation
4. Mobility in relation to the surroundings, deep structures and skin
5. Consistency: Metastatic nodes are stony hard; they are firm or rubbery in lymphomas.
6. Matting: Nodes feel as if they are connected, in metastasis, lymphomas, chronic inflammation and sarcoidosis.
7. Pressure on the surrounding structures: Huge retroperitoneal lymphadenopathy may result in bilateral lower limb edema.
8. Compare with the glands on the contralateral side.

Causes of lymphadenopathy

Localized lymphadenopathy

1. Infective:
 - Acute or chronic
 - Bacterial or viral
2. Metastatic: The glands are hard and may be fixed.
3. Lymphoma: Look for enlargement of the liver and spleen and for hematological disorders e.g. purpura or petechiae. Lymphadenopathy is confined to one group in early cases. The glands are rubbery and discrete.

Generalized lymphadenopathy

1. Hematological malignancies: Lymphoma, leukemia
2. Infections:
 - Viral: HIV, infectious mononucleosis, CMV
 - Bacterial: TB, syphilis, brucellosis
3. Autoimmune disease:
 - Systemic lupus erythematosus
 - Amyloidosis
4. Infiltrative disease: sarcoidosis, amyloidosis.
5. Drugs e.g. phenytoin

Metastatic lymph node enlargement

- **Cervical:** Tumors of mouth, nasopharynx, thyroid and larynx
- **Supraclavicular nodes:** Lymphadenopathy suggests malignancy.
Cancer of the breast and bronchus may metastasize to the ipsilateral supraclavicular nodes. **The left supraclavicular nodes** (Trousseau's or Virchow's nodes) may be involved by metastases from abdominal and pelvic organs e.g. gastric, kidney or prostate cancers and testicular tumors (figure 15).
- **Axillary nodes** from breast cancer
- **Mediastinal** compression of vessels (e.g. superior vena caval syndrome), bronchi or trachea (figure 16.1) can occur by metastatic lymph nodes.
- **Retroperitoneal lymphadenopathy (figure 16.1-3)** is especially seen in testicular tumors. Physical examination should include palpation of the abdomen for evidence of bulky retroperitoneal nodal disease in the upper abdomen near the midline (figure 16.3).
- **Iliac lymphadenopathy** may lead to venous and lymphatic obstruction and leg swelling (figure 16.4).
- **Inguinal lymphadenopathy:**
 - Palpate over the horizontal group below and parallel to the inguinal ligament and the vertical chain along the saphenous vein.

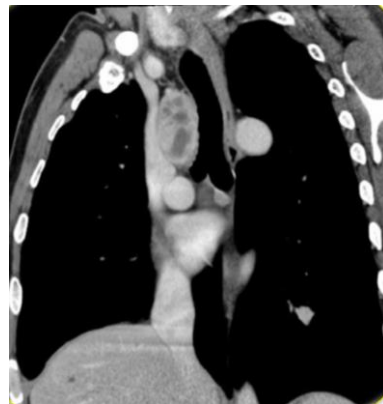
- In malignant tumors of penis and scrotum, and distal urethra in women, careful bilateral clinical evaluation of the inguinal lymph nodes is important.
 - Penile carcinoma is accompanied by considerable infection. Therefore, the inguinal lymph nodes are always enlarged, though not always with metastases.
 - 4-6 weeks course of broad spectrum antibiotics, re-evaluation after management of the primary tumor..
 - Testicular tumors do not spread to the inguinal lymph nodes unless they have invaded the scrotum or the patient had previous groin or scrotal surgery e.g. hernia or orchidopexy.
- **Popliteal** behind the knee joint

Figure 15. Grossly enlarged left supraclavicular lymph nodes in a patient with metastatic prostatic carcinoma

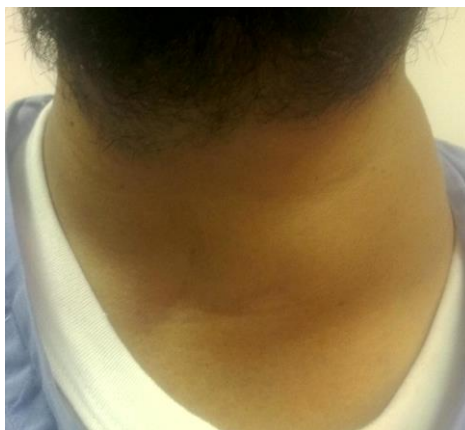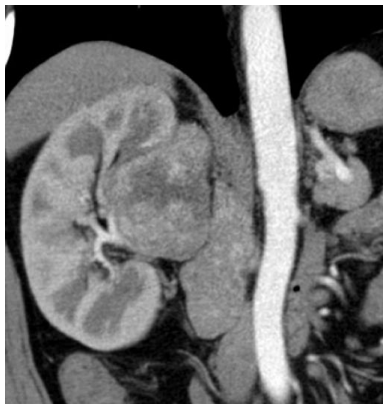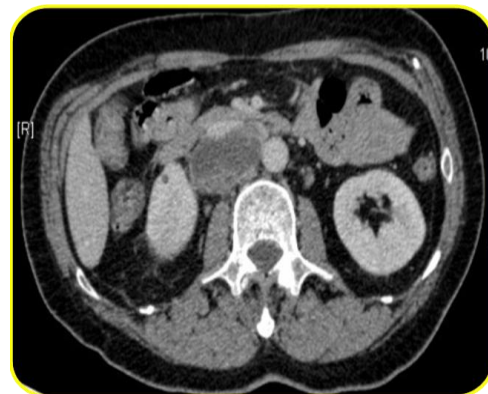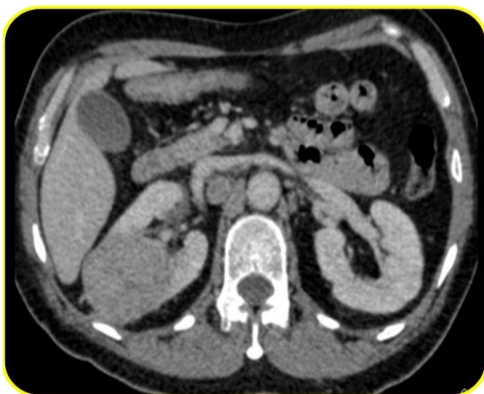


Figure 16. Clinical and radiological correlations of lymph node metastases in some urological tumors:

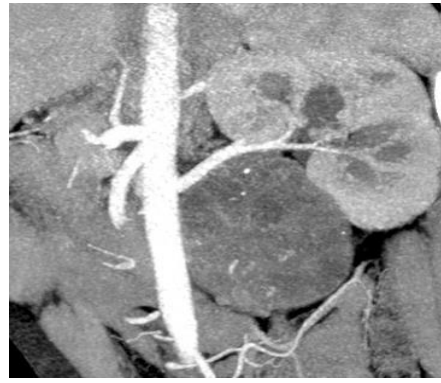
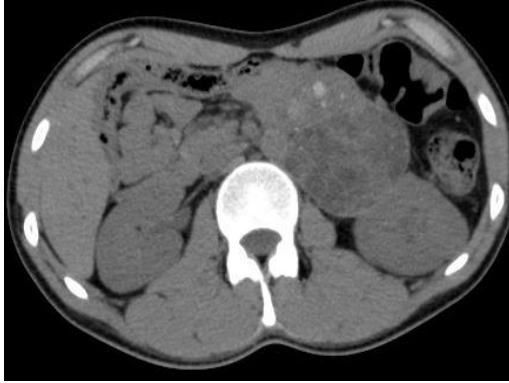- 1. Tracheal compression:** A 59-year-old man with history of left radical nephrectomy 11 years ago, presenting with right renal tumor, retroperitoneal and mediastinal lymphadenopathy.



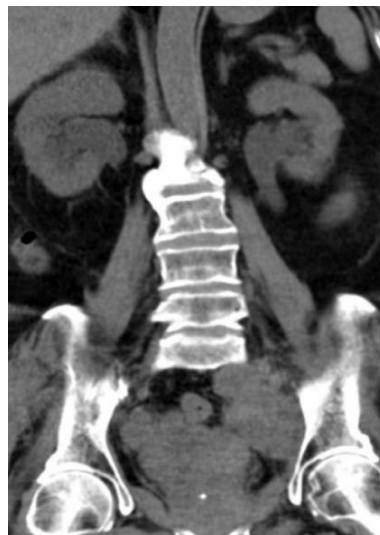- 2. Pulmonary embolism:** A 49-year-old man presented with right renal tumor and large lymph nodes compressing the inferior vena cava. Patient developed pulmonary embolism soon after right radical nephrectomy and lymphadenectomy because of the overlooked distal caval bland thrombus.



- 3. Abdominal mass:** A 29-year-old man presented with a tumor in the left testis and a large retroperitoneal lymph nodes.



- 4. Swelling of the leg:** A 76- year-old gentleman presents with a history of bilateral loin pain, back pain, and swelling of the left leg with concomitant prostatism. Clinical examination reveals scrotal and penile edema, and an irregular stony hard prostate. CT scan shows extensive iliac lymphadenopathy and bilateral hydronephrosis.



CHAPTER 14: CHEST AND HEART

Inspection:

- Scars, prominent veins, lesions, deformity
- Shape and contour of the chest
- Rate and depth of breathing:
- Respiratory movements are observed.
- Inspect apical impulse or other pulsations.
- **Breasts:** Size, contour, masses, discharge, scars, nipples
- **Gynecomastia:**

This is bilateral enlargement of the male breast due to an increase in the ductal and connective tissues. Causes of gynecomastia include:

- Obesity due to increased adipose tissue
- Chronic liver disease and alcoholism
- Endocrine disorders: Hypopituitarism and thyrotoxicosis
- Testicular tumors secreting estrogens: Leydig cell tumor causes excessive production of androgens or estrogens in adults. Gynecomastia may be present before a testicular mass is palpable. Non-seminomas that secrete HCG may give rise to gynecomastia.
- Hormonal treatment for prostate cancer e.g. anti-androgens and estrogens
- Drugs: Digoxin, cimetidine, spironolactone and marijuana

Palpation:

- Tenderness, rubs, wheezes
- Trachea lies in the midline deep to the sternal notch. It shifts if the mediastinum is pushed laterally.
- Heart apex beats normally at the 5th intercostal space in the midclavicular line. Palpate for thrills.

Percussion:

- Normal lungs are resonant.
- Hyper-resonance: Pneumothorax, emphysematous bullae.
- Dullness: Collapse, consolidation, peripheral abscess, neoplasm.
- Percuss for the heart size and contour.

- Stony dullness over the heart is diminished in chronic obstructive pulmonary disease.
- The liver dullness is noted below the level of the 6th rib in the midclavicular line. It is lost with hyperinflated lungs.

Auscultation:

- Normal breath sounds are vesicular or rustling heard during inspiration and early expiration.
- Reduced sounds:
 - Localized: Pneumothorax, pleural effusion, tumor, and lung collapse.
 - Generalized: COPD, asthma.
- Wheezes: Musical expiration sounds caused by narrow airways e.g. COPD and asthma.
- Crepitations: Air entering collapsed airways produces inspiratory crackles e.g. infection, fluid.
- Rub: Inflamed pleural surfaces rub against each other.
- Important chest problems in urologic practice are shown in table 13.
- Auscult the heart for rhythm, quality, and intensity of heart sounds, the presence of murmurs (location, timing, intensity, character, transmission and relation to respiratory movements).

Table 13. Important chest problems in urologic practice

	Pneumothorax	Pleural effusion	Lung collapse
Etiology	Air in pleura e.g. pleural injury during renal surgery	Fluid in pleura e.g. malignancy	Collapse of a lung segment occurs due to bronchial obstruction.
Tracheal shift	Away	Away	Towards the lesion
Percussion	Hyper-resonance	Stony dullness	Dullness
Breath sounds	Absent	Absent	Diminished

CHAPTER 15: ABDOMINAL EXAMINATION

The abdomen is divided into 4 quadrants based on two perpendicular planes drawn through the umbilicus: right upper, right lower, left upper and left lower (figure 17). The umbilical area is considered as the central fifth region.

Alternatively, according to the traditional classification, the abdomen is divided into classic 9 regions by 2 horizontal and 2 sagittal planes (figure 18). The upper horizontal one is between the lower borders of the ribs, at the level of the first lumbar vertebra, midway between the suprasternal notch and symphysis pubis (transpyloric plane). The lower one passes through the upper borders of iliac crests. The sagittal planes go vertically from the mid-clavicular to the mid-inguinal points.

It is important to appreciate the characteristics of other intra-abdominal organs when involved with disease, and differentiate from urological disorders.

Abdominal examination is based on the following steps:

- A. Inspection
- B. Auscultation
- C. Palpation, and
- D. Percussion

Figure 17. Division of the abdomen into 5 areas: RUQ (Right Upper Quadrant), LUQ (Left Upper), RLQ (Right lower), LLQ (Left lower) and U (umbilical or central)

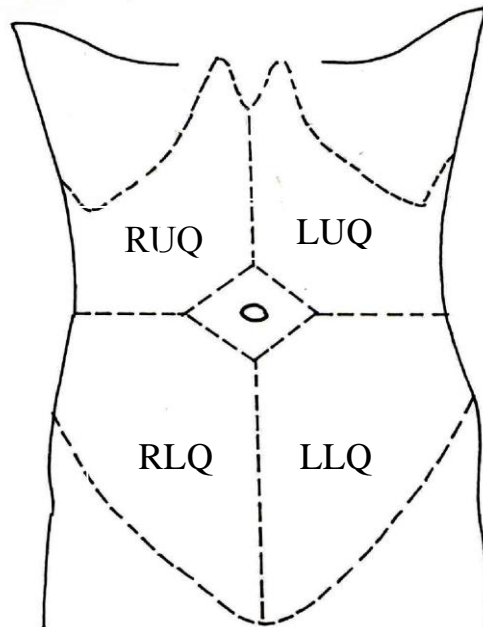
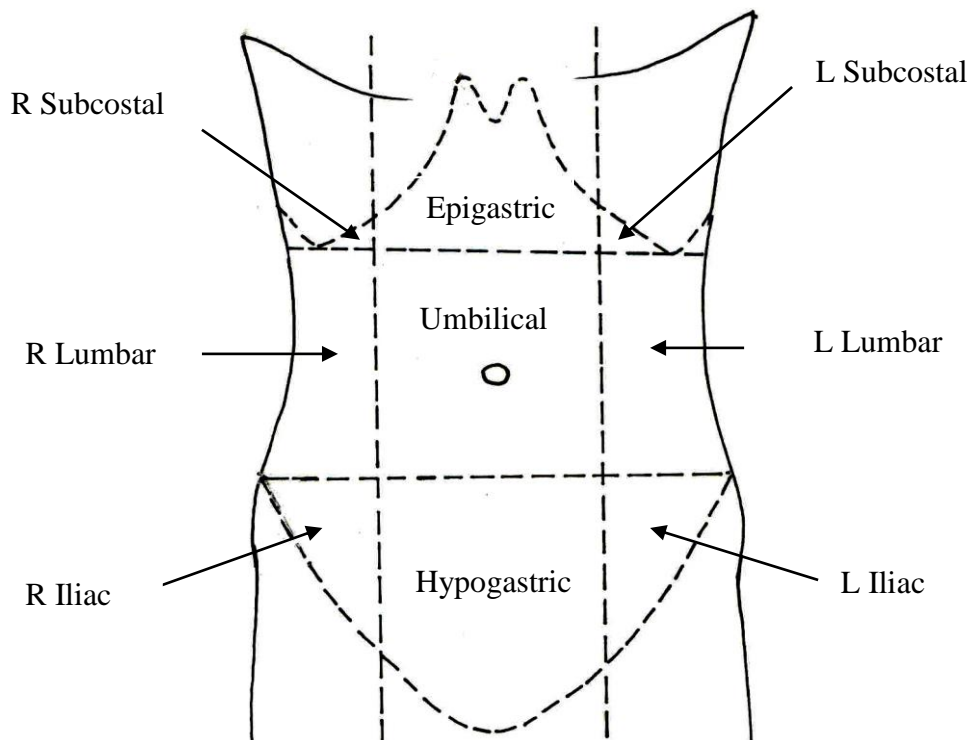


Figure 18. Division of the abdomen into 9 areas



A- INSPECTION

Visual examination with observation notes are made on the following:

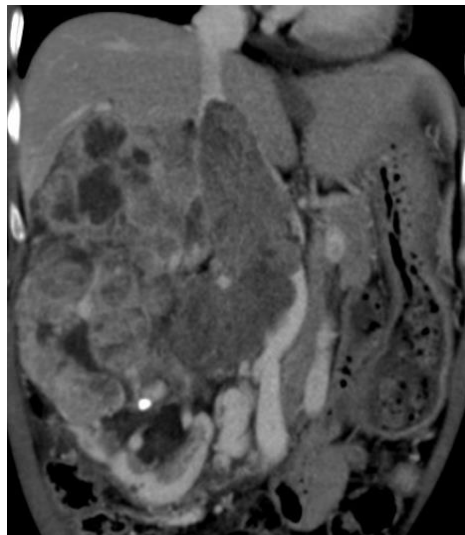
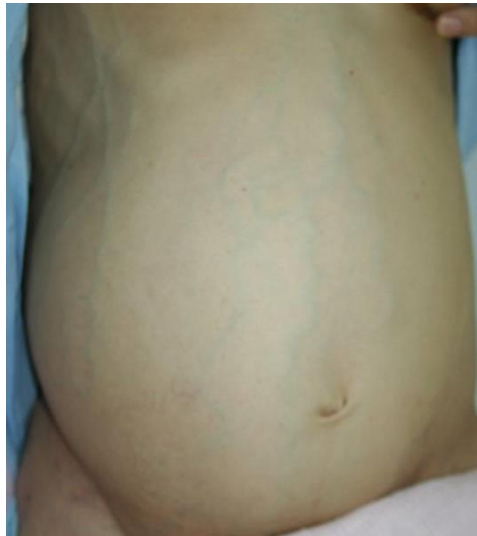
1. ABDOMINAL SHAPE OR CONTOUR:

- Scaphoid (markedly concave or hollowed) e.g. in malnutrition; flat; rounded or protuberant.
- Is there any abnormality? (figure 19)
- Is the abdomen symmetrical?
- Is there a visible organo-megaly (enlarged liver or spleen) or masses? A renal swelling may give fullness or bulge in the flank.
- Generalized bulging: Fat, flatus, fluid, fetus and feces.
- Localized bulging:
 - Upper half: Renal mass (figure 20)
 - Lower half: Distended bladder, pregnancy, ovarian tumor or uterine fibroids.
- Abdominal wall lumps persist while intra-abdominal swellings disappear by tensing the abdominal muscles by straight leg raising from the bed. Survey the inguinal and femoral areas.

Figure 19. Inspection of the abdomen is showing rounded contour with a bulging swelling on the right side.

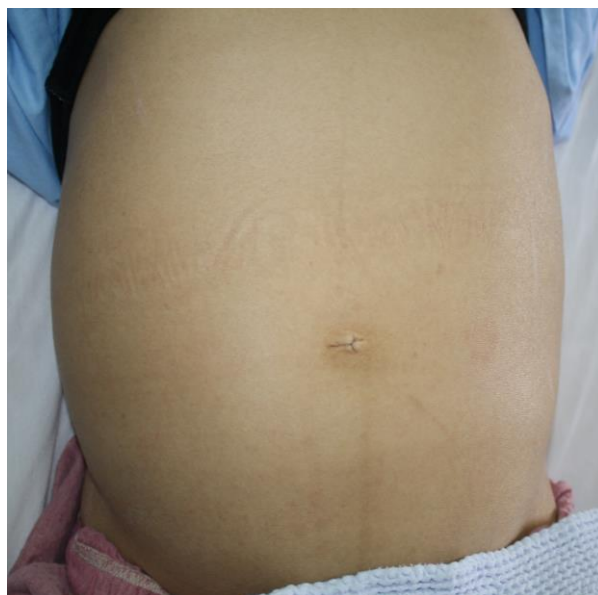

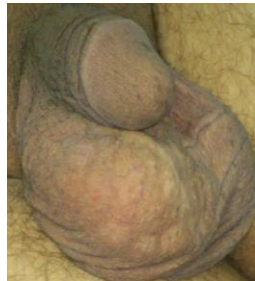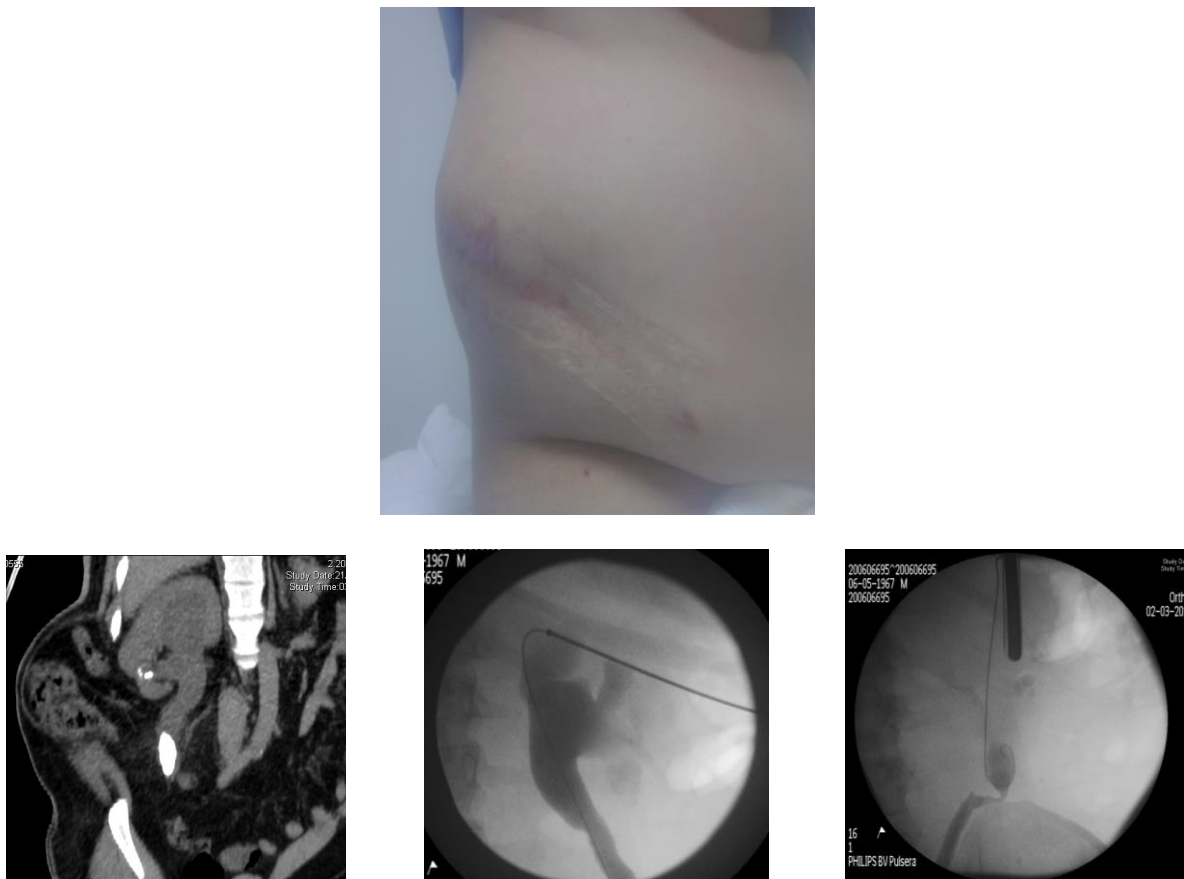
Figure 20. Clinical features of a case of advanced right renal tumor with a tumor thrombus in the inferior vena cava shown in CT scan: Asymmetrical abdomen with a bulge on the right side and the umbilicus is shifted downwards and to the left. Dilated veins are observed on the abdomen and chest walls. Non-reducing right varicocele is seen.



2. SKIN ABNORMALITIES:

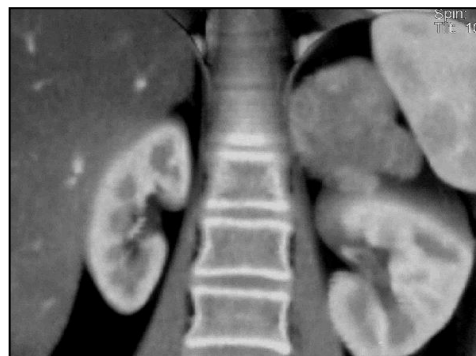
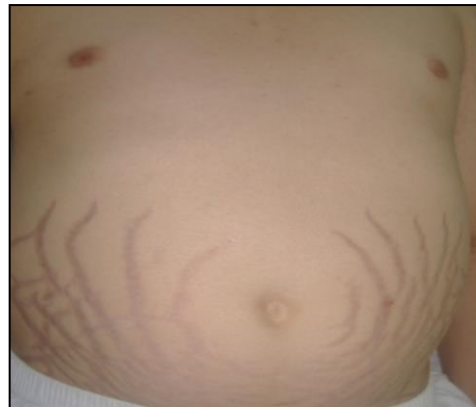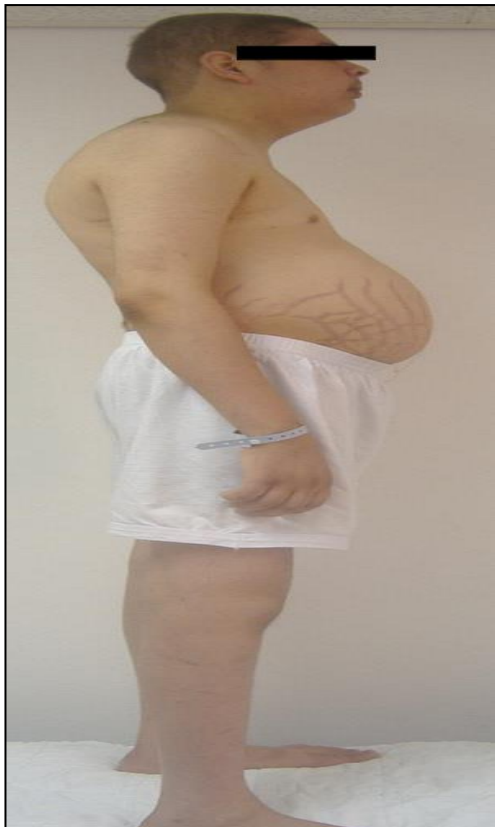- **Surgical scars:** Location, appearance and characteristics (figure 21):
 - Where are they? How old do they appear? Is there evidence of herniation on coughing?
 - New scars are raised and red gradually fading to pink.
 - By 6 months, they are flat and skin colored or gray.
 - Clean wounds, healed by first intention, are regular and thin.
 - Infected wounds heal by secondary intention and are irregular and wide.
 - Keloids develop as irregular scars with abundant hypertrophic fibrous tissue.
 - Surgical scars may show sinuses, fistulae and incisional hernias.

Figure 21. Recurrent stone disease in a patient with an incisional hernia: Patient with right lumbar incisional hernia and a stone in the right lumbar ureter, the steps of supracostal per-cutaneous ureteroscopy are shown (Courtesy of Dr I. Eraky).



- **Color:** Areas of skin rashes or discoloration.
- **Fistulae**
- **Striae:** Stretch marks may be red, white or purple, seen in Cushing's syndrome (figure 22), pregnancy, obesity and ascites.

Figure 22. Clinical and radiological features of Cushings' syndrome: Dorsocervical fat pads, abdominal striae and central obesity, are observed in a male aged 29. CT scan shows a heterogenous left adrenal mass.



- **Stomas (figures 23-26):**

What type?

Does it look healthy or abnormal?

What is the content of appliance?

Document the presence of complications e.g. parastomal hernia and stomal stenosis.

Figure 23. Ileal loop conduit stoma with two ureteral catheters after surgery to the left and parastomal hernia to the right

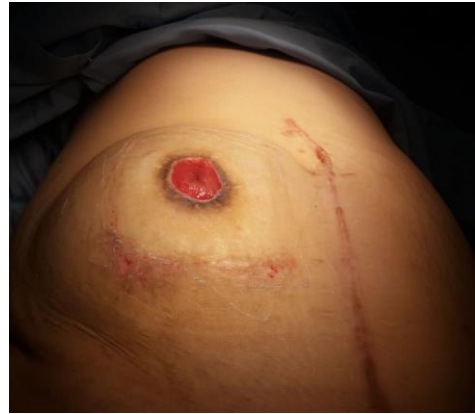
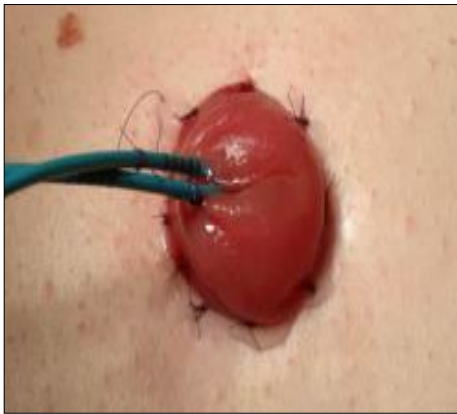
Figure 24. Ileal loop conduit stoma with an intestinal fistulous opening close to its medial edge to the left (arrow), and a prolapsed stoma to the right.

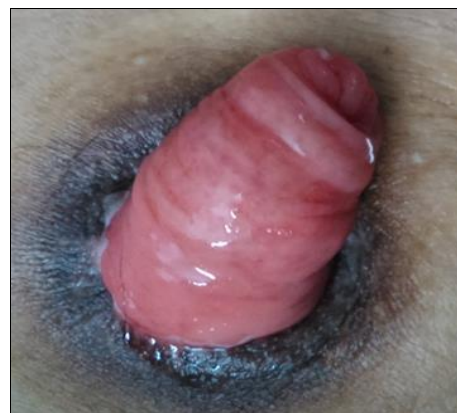
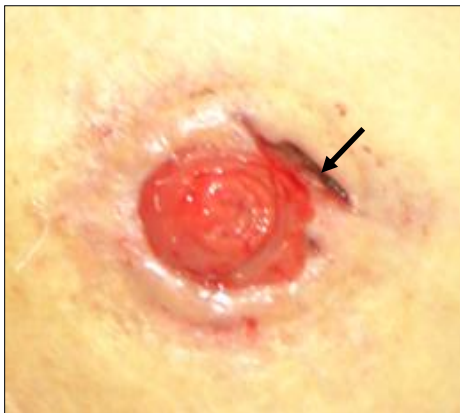

Figure 25. Continent cutaneous urinary diversion: Self catheterization

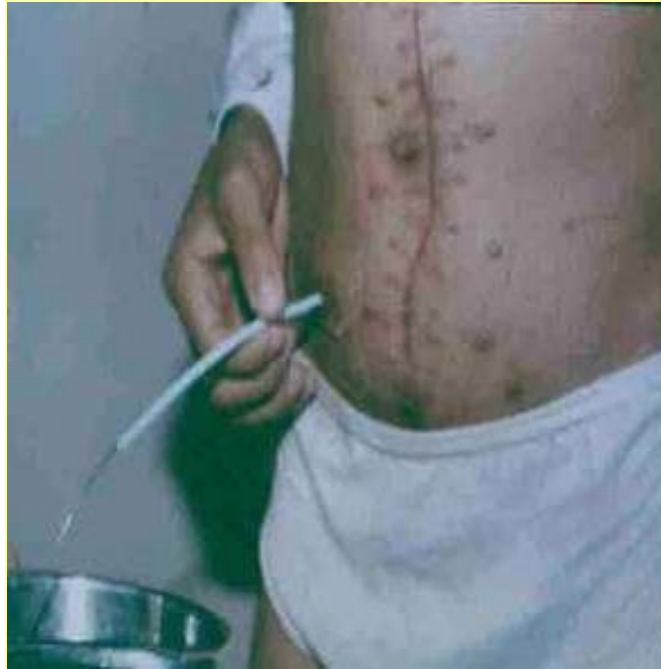
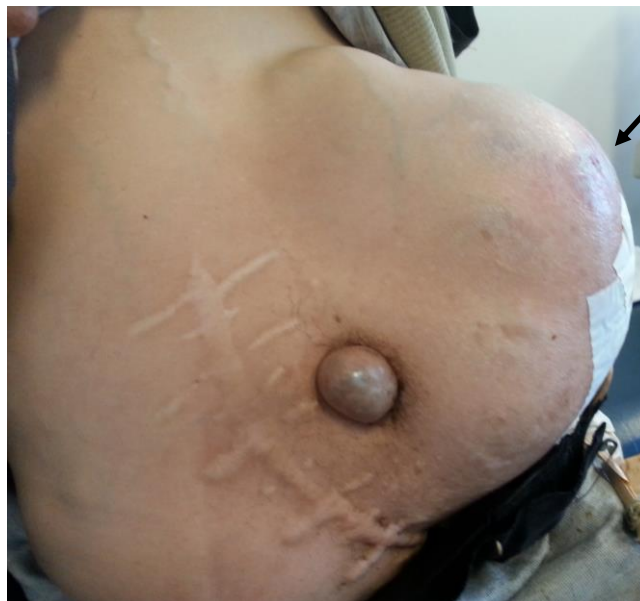
Figure 26. Left-sided terminal colostomy in a patient who underwent radical cystectomy and isolated rectosigmoid bladder. Colostomy stomal stenosis (arrow), parastomal hernia, paraumbilical hernia and paramedian scar are noticed.



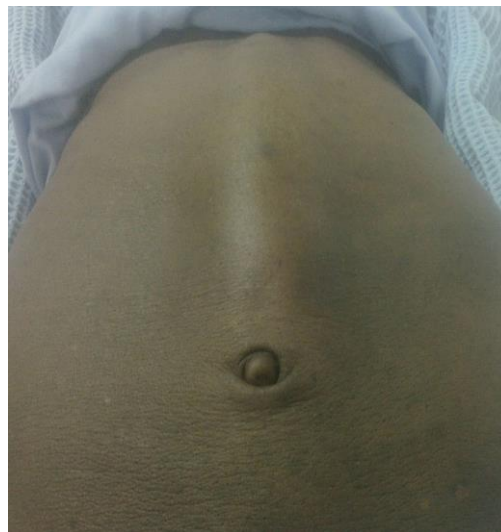3. SUBCOSTAL ANGLE:

The subcostal angle is acute in normal individuals with variations. It is obtuse when there are conditions associated with chronic increase in the intra-abdominal pressure.

4. RECTUS ABDOMINUS MUSCLES:

Divarication of recti is separation of the two muscles due to stretching of the linea alba by chronic increase in the intra-abdominal pressure e.g. large abdominal masses (figure 27), repeated pregnancies and ascites. Abdominal contents will form a midline ridge when the patient raises the head and shoulders or perform Valsalva's manoeuvre.

Figure 27. Divarication of recti appears as a midline bulge when the patient raises the head and shoulders with a localized bulging of an enlarged spleen in the left upper abdominal quadrant.



5. THE UMBILICUS:

- **It is the site of 4 fetal structures:**
 - Two umbilical arteries → 2 lateral umbilical ligaments
 - Umbilical vein → ligamentum teres
 - Urachus (a tube extending between the umbilicus and the bladder dome) → median umbilical ligament

- **Urachal anomalies:**

- a) Urachal sinus
- b) Umbilical fistula with ammoniacal discharge and dermatitis
- c) Diverticulum in the bladder dome
- d) Urachal cyst

- **Location:**

The umbilicus is equidistant between top of symphysis pubis and xiphisternum. It is displaced downwards by ascites and upwards by pelvi-abdominal swellings e.g. pregnancy and ovarian cysts.

- **Inflammation**

- **Unfolding and protrusion:** Intestinal obstruction, ascites

- **Secondary malignant infiltration**

- **Umbilical hernia**

6. DILATED VEINS:

- Few small veins may be visible normally.
- Engorged veins are seen in emaciation, portal hypertension and IVC obstruction.
- The normal venous flow is downward below the umbilicus and upward above it.
- In portal obstruction the direction is unchanged.
- Caput medusa → dilated veins radiating from the umbilicus in liver failure.
- In inferior vena caval obstruction, the flow below the umbilicus is reversed. This sign is noted in kidney cancer with a thrombus extending into the IVC (figure 20).

7. HAIR DISTRIBUTION:

- Secondary sexual hair appears at puberty in the face, axilla and pubic region.
- Facial hair is stimulated by androgens in women (virilism).
- Male hypogonadism and cirrhosis cause sparse hair.
- The normal female hair distribution in the pubic area is a triangle with the apex pointed to the perineum. In males the distribution is diamond with an upper tip pointing to the umbilicus.

8. MOVEMENTS:

Peristalsis:

Normal peristalsis may be visible in very thin individuals. Observe for several minutes, for the increased peristaltic waves, in cases of suspected dynamic intestinal obstruction.

Pulsations:

The normal aortic pulsations are frequently visible in the epigastrium.

Pulsations may be visible with each heart beat in cases of aortic aneurysm.

Movements with respiration:

Abdominal wall moves in a symmetrical fashion with respiration. In cases of peritonitis, there may be localized or generalized loss of this movement.

9. HERNIA:

Hernia is defined as protrusion of a viscus in part or in whole through an abnormal opening in the abdomen. Hernia is obvious as a swelling which is easily reduced into the peritoneal cavity by pressure and returns by standing and coughing.

- a) Inguinal hernia is the commonest type of abdominal hernia. A comparison between oblique (indirect) and direct inguinal hernias is shown in table 14.

- b) Femoral hernia protrudes through the femoral canal which is bounded superiorly by the inguinal ligament, laterally by the femoral vein, and medially by the pyriiformis muscle and pubic ramus. It is bulging below the inguinal ligament.
- c) Umbilical hernia comes through the center of the umbilical scar. Congenital hernias are common in infants and generally close by 2 years of age. In adults, acquired umbilical hernia is manifest by conditions that increase the intra-abdominal pressure.
- d) Para-umbilical hernia
- e) Incisional hernia: Defect in the abdominal wall after surgical operations. Inadequate wound healing may lead to development of a fascial defect and incisional hernia.
- f) Epigastric hernia is a midline protrusion through a defect in the linea alba between the xiphoid process and umbilicus.
- g) Spigelian hernia protrudes through the linea semilunaris (lateral to the rectus sheath).
- h) Sliding hernia, in which, the wall is made up of an intra-abdominal organ, commonly the sigmoid colon or the urinary bladder.

Evaluation of hernias:

- Determine the features: Site, size, shape, tenderness, tension, temperature, and contents; both in the supine and erect positions.
- Characteristics of the overlying skin.
- The presence of a cough impulse.
- Attempt reduction of the hernia.
- Percussion: Omentum is dull, bowel is resonant.
- Auscultation for bowel sounds.
- Examine the same site on the opposite side.

Table 14. Inguinal hernias

Indirect hernia	Direct hernia
An inguinal hernia that arises lateral to the inferior epigastric vessels and protrudes through the internal inguinal ring through the inguinal canal.	An inguinal hernia that protrudes through the Hesselbach triangle medial to the inferior epigastric vessels, through the posterior wall of the inguinal canal.
In males, it follows the spermatic cord and descends to appear as a scrotal swelling. In females, it appears as labial swelling.	Very rare to include the scrotum.
Reduces upwards, laterally and backwards	Reduces upwards and backwards
Remains reduced with pressure at internal ring	Not controlled with pressure at internal ring
Reappears at the internal ring and flows medially	Reappears as before reduction
Narrow-necked	Wide-necked

10. WOUND COMPLICATIONS:**a) Wound infection:**

- There will be fever, malaise, anorexia, pain and discharge.
- The wound is red, tender and swollen.
- It may be discharging pus or fluctuant due to the contained pus.
- Surgical site infections involve the skin and subcutaneous tissue. Superficial infectious process occurs above the fascia while deep surgical site infections involve the fascia. Deep surgical space infections are intra-abdominal infections after abdominal surgery and include intra-abdominal abscesses and peritonitis.

- Sepsis is defined as infection plus systemic manifestations e.g. fever, tachycardia and hyperglycemia. Severe sepsis may lead to tissue hypoperfusion and organ dysfunction.
- Septic shock is sepsis-induced hypotension that persists inspite of adequate fluid therapy.

b) Postoperative bleeding:

- **Arterial** hemorrhage from vascular anastomosis is rare. It is rapid, bright-red and pulsatile.
- **Venous** hemorrhage is more common and is due to opening of venous channels. It is non-pulsatile, low-pressure and dark.
- Bleeding may be contained within body cavities or evident through drains and catheters.

Causes:

1. **Primary** hemorrhage occurs immediately after surgery or as a continuation of intra-operative bleeding.
2. **Reactionary** hemorrhage occurs within the first 24 hours due to improved circulation.
3. **Secondary** hemorrhage occurs up to 10 days after surgery due to wound infection.

c) Wound hematoma: A localized collection of blood in the wound leading to swelling and discoloration.

d) Wound dehiscence (figure 28):

Risk factors include:

Clinical factors: Infections, malnutrition, diabetes mellitus, pulmonary disease and corticosteroids.

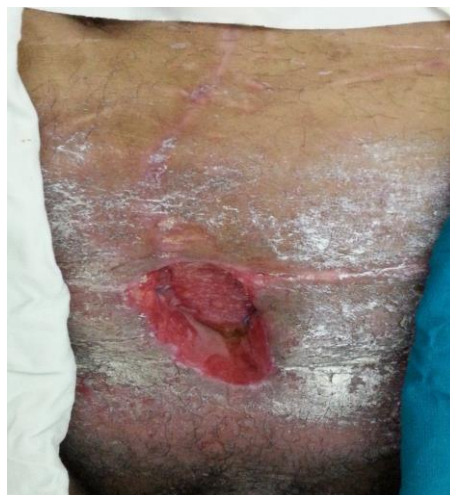Technical factors: Inadequate anesthetic relaxation, inappropriate suture material or placement, incomplete tissue incorporation and excessive tension.

Types of wound dehiscence:

1. **Superficial dehiscence** involves the skin and subcutaneous tissue. The subcutaneous fat and fascia are visible.
2. **Deep dehiscence** involves the full thickness making the viscera visible.
3. **Internal dehiscence** e.g. anastomotic leakage causing enteric fistulae.

The management of stable uncomplicated fascial dehiscence with no exposed bowel consists of local wound care and elective delayed repair of incisional hernia. Early repair is indicated in patients with uncontrolled intra-abdominal infections, impending or actual evisceration (protrusion of bowel or omentum through the fascial dehiscence) and the presence of enterocutaneous fistula.

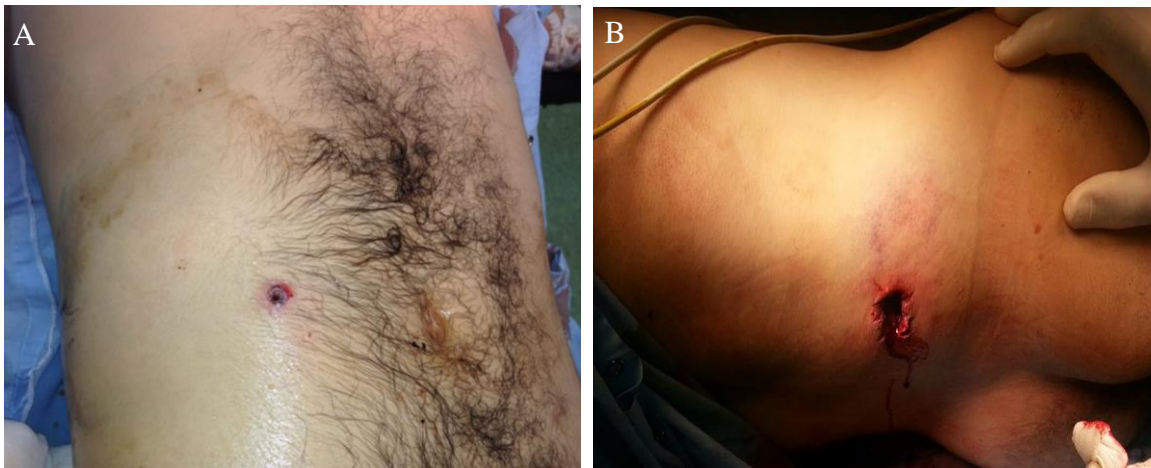
Figure 28. A 57-year-old man developed infection in the lower portion of his wound that required local wound care following radical cystectomy and ileal neobladder for muscle-invasive bladder cancer. The patient returned back 4 weeks after surgery, and had indicated the presence of urine drainage from his open portion of the wound.



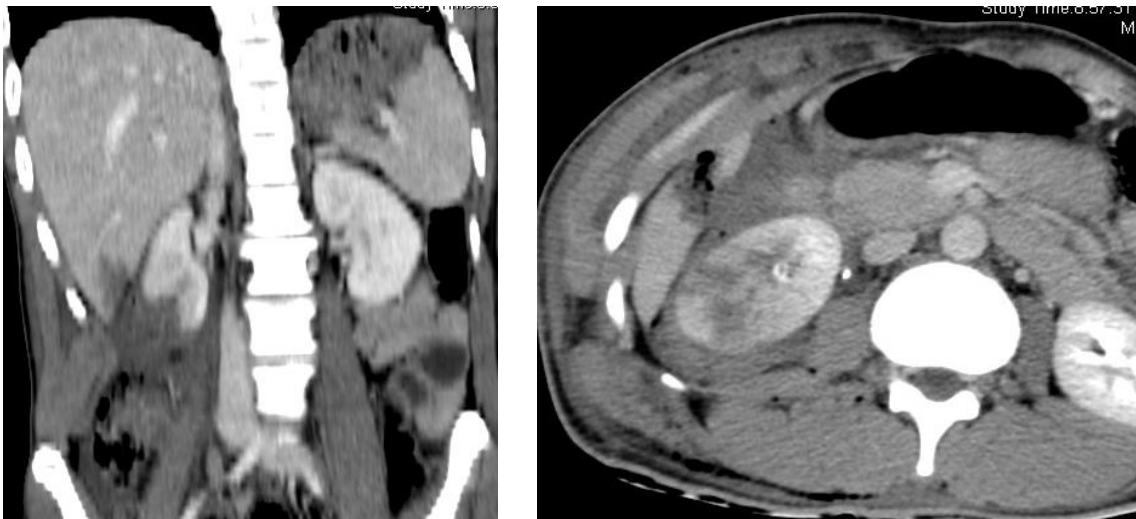
11. SIGNS OF TRAUMA:

- Gunshot (figure 29) and stab injuries
- Bruising
- Hematomas

Figure 29. A 27-year-old man presented with bullet injury in the right upper abdomen. The patient was found hypotensive, pale and in agony. Abdominal examination showed a bullet inlet (A) in the right upper quadrant and exit from the bulging right flank (B). (Courtesy of Dr A. Harraz).



Abdominal CT scan shows injury of the right kidney, liver and free intra-peritoneal air indicative of intestinal injury.



B. AUSCULTATION

- Auscultation is not helpful in otherwise normal examination.
- Clinical context is more important.

1- Bowel sounds:

Normal peristalsis produces bowel sounds as liquid and gas are passed through the intestine. Normal bowel sounds are intermittent, low-pitched and chuckling. There is a lot of variability in normal persons. Clicks and gurgles are noted every 5-10 seconds on average.

- Absent bowel sounds: Peritonitis and paralytic ileus
- Hyperactive sounds: Diarrhea
- Dynamic intestinal obstruction produces a classical tinkling like water being poured from one cup to another. In late cases, bowel sounds may be absent due to vascular compromise.
- The coexistence of intestinal colic and borborygmi (stomach growling due to prolonged hyper-peristalsis) may establish the diagnosis of obstruction of small intestine.

2- Arterial bruit:

- It is useful in evaluation of cases with possible reno-vascular hypertension.
- Renal artery stenosis: A high pitched sound analogous to murmur is checked a few cm above the umbilicus along the lateral edge of rectus muscle or in the costo-vertebral angle.
- Aortic aneurysm
- Mesenteric artery stenosis

3- Venous hum: Liver cirrhosis

4- Friction rubs: Grating sound with respiratory movement due to inflammation of peritoneal surface of an organ.

5- Succession splash indicates air and fluid in a cavity with shaking: normal in the stomach.

C. PALPATION:

LIGHT PALPATION:

- **Tenderness** is pain expression elicited by palpation.
 - Location: quadrant
 - Depth of palpation: Superficial or deep
 - Patient response: Mild or severe
- **Guarding** is voluntary contraction of the abdominal muscles to avoid pain which tends to be generalized over the abdomen.
 Causes: Tenderness, fear, anxiety, examiner's cold hands
 Guarding disappears when the patient purposely relaxes the muscles
- **Rigidity** or spasm (involuntary guarding) is involuntary contraction of the abdominal muscles in response to peritoneal inflammation. It is restricted only to the inflamed area.

DEEP PALPATION:

A. TENDER AREAS:

- Mc Burney's point: 1/3 of the way from the right anterior superior iliac spine to the umbilicus. Focal tenderness is seen in appendicitis.
- Murphy's sign: Inspiratory arrest on right upper quadrant palpation suggestive of gall bladder disease.
- Rovsing's sign: Patient experiences right lower quadrant pain as you press the left lower quadrant in appendicitis (cross palpation tenderness).
- Rebound tenderness: Press deeply into the abdominal wall then quickly release, pain results from peritoneal inflammation.

B. PALPATION OF SPECIFIC ORGANS:**THE LIVER:**

- Start in the right iliac fossa and move gently up to the right hypochondrium.
- Support the last right ribs with your left hand posteriorly.
- Ask the patient to take a deep breath and try to feel the liver margin.
- Advance your right hand upwards and parallel to the rectus muscle and repeat until the costal margin.
- An over-distended gall bladder may form an oval mass below the liver margin.
- If palpable describe:
 - Size in cm below the costal margin.
 - Surface: Smooth or irregular.
 - Edge: smooth or irregular.
 - Consistency, tenderness, pulsations.

Hepatomegaly

- A mass descends from underneath the right costal margin.
- You cannot get above it.
- It moves with respiration.
- It is dull on percussion.
- It has a sharp rounded edge.
- Surface may be smooth or irregular.

THE SPLEEN:

- Normal spleen is not palpable. When enlarged, it grows inferiorly and medially.
- The left hand supports the costal margin.
- Palpate upwards from the right iliac fossa or umbilical area to the left hypochondrium till the costal margin asking for deep breath on the way.
- Get the patient to lie on the right side, facing towards you, and palpate up till the left hypochondrium.
- If you can feel the tip of the spleen it is significantly enlarged perhaps twice its normal size.

Enlarged spleen:

- It enlarges underneath the left costal margin towards the right iliac fossa.
- Firm in consistency.
- Smooth surface.
- Palpable notch in a sharp anterior border.
- Not possible to get above it.
- Moves with respiration.
- Dull on percussion.

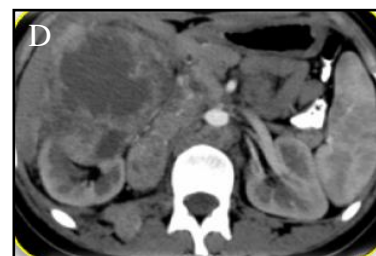
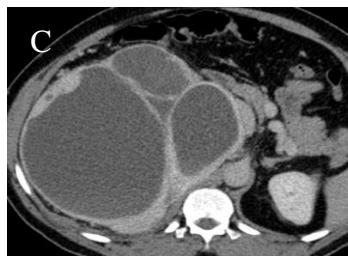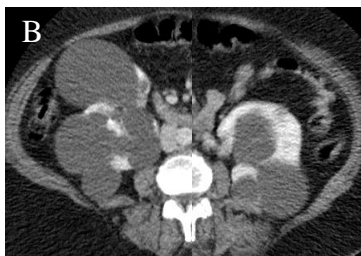
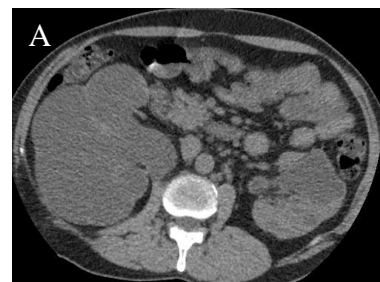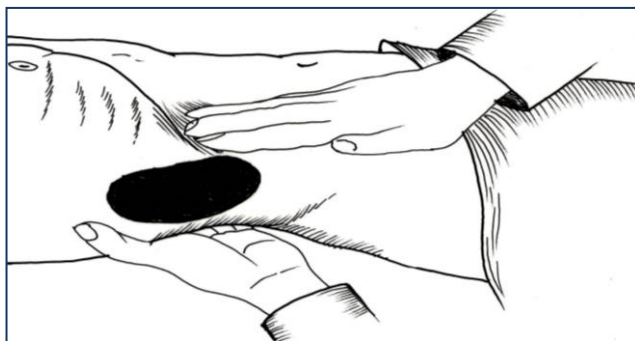PALPATION OF THE KIDNEYS:

- The left hand is placed posteriorly in the costo-vertebral angle (figure 30).
- The right hand is placed anteriorly just below the costal margin.
- Palpate deeply while the patient is taking a deep breath and the pulps of fingers of the 2 hands are approximated with expiration.
- Repeat for the left kidney.

Figure 30. Bimanual palpation of a right renal mass

Correlate clinical findings with radiologic diagnosis:

**A. Hydronephrosis B. Polycystic kidneys C. Complex renal cyst
D. Kidney cancer**



RENAL MASS:

- An enlarged kidney is classically a lump in the loin or can be moved back into the loin.
- Usually the mass maintains a rounded or a bean shape.
- Ballotement: It is bimanually palpable and can be balloted with two hands. Short, quick forward thrusts are made by the posterior hand lead to a bouncing sensation to the anterior hand.
- The lump moves with respiration, above which you can get the hand between the mass and the edge of the costal margin.
- There may be a band of resonance anteriorly from gas in the colon, while the lump is dull posteriorly. There is no resonance in front of the kidney if the colon is displaced by a large mass, or if it is loaded with feces.
- Differentiating splenomegaly and an enlarged left kidney is shown in table 15.

Features of some renal masses:**A. Hydronephrosis:**

- Unilateral, large, bean-shaped, mobile mass
- Well-defined border with rounded lower pole.
- Not tender unless infected.
- Boggy in consistency i.e. like a half-full cyst, and becomes tensely cystic if infected.

B. Polycystic kidneys:

- Bilateral disease, however, not all cases are palpable bilaterally.
- Large mobile renal masses
- The mass is irregular with beaded nodular surface
- Not tender except in cases of hemorrhage and infection
- Firm in consistency

C. Pyonephrosis:

- Unilateral renal mass of moderate size
Not a bean
Irregular, ill-defined border with nodulated surface
Tender and may be fixed due to peri-nephritis.
- Heterogeneous firm consistency.
- Patient looks toxic.

D. Kidney cancer: There are usually absent clinical findings, occasionally you will feel:

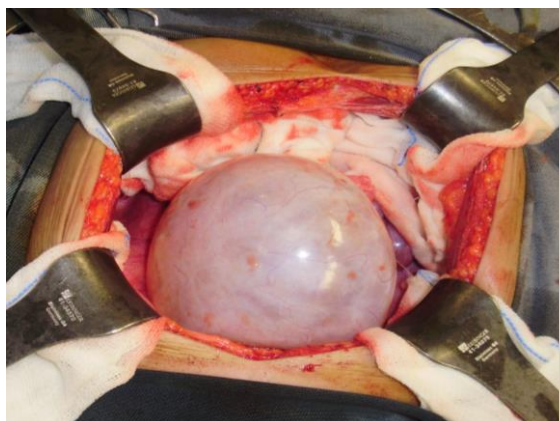
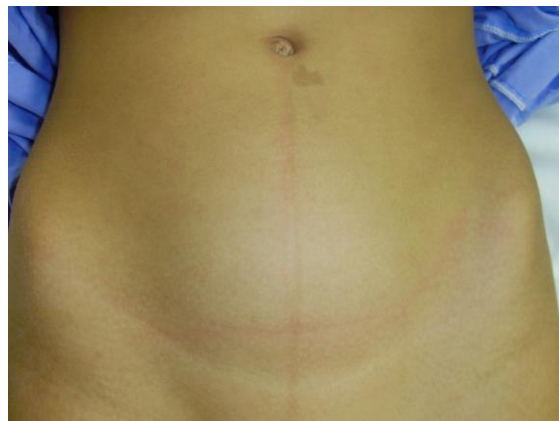- Palpable renal mass:
The mass may be irregular in shape.
It feels firm or hard and usually not tender.
Movement with respiration and ballottement are initially retained, but may be lost later.
- Palpable left supra-clavicular lymphadenopathy.
- New-onset, non-reducing varicocele, especially on the right side.
- Bilateral lower limb edema.

PELVI-ABDOMINAL ORGANS:

- The urinary bladder: The most common cause of hypogastric mass in males is acute urinary retention.
 - An overdistended bladder is classically a rounded or a globular swelling arising from the pelvis into the lower abdomen in the midline. Sometimes, it may lean over to one side.
 - Start percussion above the umbilicus and work down.
 - It is dull on percussion.
 - Pressure causes a desire to void.
 - The swelling disappears when urine is let out with a catheter.
- In cases of chronic urinary retention, the distended bladder may feel as a floppy, soft, midline lower abdominal swelling.
- In females: Uterine or ovarian swellings (figure 31) may cause visible, midline lower abdominal masses.

Table 15. Differentiating Splenomegally and an Enlarged Left Kidney

	Enlarged spleen	Left renal mass
Palpation	Impossible to feel above the mass. Hand cannot be insinuated anterior to the spleen	May feel above the mass
	A notch on the anterior border	Inner surface is concave, the outer border is convex (hydronephrosis)
Direction of enlargement	Towards the umbilicus	Inferiorly and lateral to midline
Movements	Moves early on inspiration	Late
Ballottement	Not ballotable	Ballotable
Percussion	Dull to percuss	Band of resonance anteriorly due to bowel gas.

Figure 31. Suprapubic swelling simulating a full urinary bladder, diagnosed as a huge ovarian cyst as shown during exploration.

D- PERCUSSION:

- Tapping over solid or liquid filled structure → dullness.
- Air filled → tympanitic e.g. stomach.
 - Middle finger of left hand firmly against abdomen.
 - Using flabby wrist action, hammer middle finger of the other hand down aiming for last joint.
 - Percuss lightly in the 4 quadrants.

Liver (6-12 cm):

- Start in chest below nipple in the right mid-clavicular line and move down to ascertain the upper margin. The liver is an area of dullness below the 6th rib in the mid-clavicular line.
- Percuss span of liver dullness in the right mid-clavicular line. The normal liver span is 6-12cm in the mid-clavicular line and 4-8cm in the mid-sternal line.
- The liver dullness is lower during inspiration and in emphysema. It is higher in obesity, hepatomegally, sub-phrenic fluid collection, ascites and pregnancy.
- Tone changes from resonant (lung) to dull (liver) to resonant (intestines).
- Percuss upward in the same line from below the umbilicus to determine the lower border.

Spleen is located in the hollow of ribs.

- Percussion over last intercostal space in anterior axillary line is normally resonant.
- Dullness suggests splenomegaly.

Stomach: Resonant epigastric area.

Kidneys: There may be a band of colonic resonance anterior to a renal mass.

The renal angle (costo-vertebral angle) is normally resonant due to presence of gas in the colon. Dullness may be due to a loaded colon, a renal mass, the presence of a collection.

Urinary bladder: In case of acute urinary retention, the distended bladder may be visible. Percussion will determine the extent of fullness and is done from above downwards i.e. from resonant to dull areas.

Shifting dullness indicates more than 500 ml of ascitic fluid (liver cirrhosis, carcinomatosis, congestive heart failure).

- Intestines will float to surface.
- Percussion detects air-fluid interface.
- Change in position shifts point of interface.
- Percuss from the umbilical area moving down towards one side, when the sound becomes dull, keep your finger and ask the patient to move on the opposite side. Allow fluid to sink and percuss again. If the region becomes resonant that is a positive sign.

CHAPTER 16: CLINICAL FEATURES OF A MASS

Table 16. Clinical characterization of features of a mass

S	Site	Level
		Location
		Landmarks
	Size	3 dimensions
	Shape	Borders
		Form
	Surface	
	Sensation	Temperature, tenderness, texture
	Skin surface changes	
C	Consistency	Firmness, fluctuation
A	Attachments	Mobility, fixation
L	Trans-illumination	
P	Pulsations	

ANATOMY

1- Site:

Location: Abdominal, pelvic, penile, and scrotal

Level: Intra-abdominal e.g. renal, adrenal

Parietal

Landmarks: Relations to bones and strategic points

2- Size:

- Volume \simeq Length x width x height/2.
- One dimension may be ill-defined.
- **Examples:**

Normal kidney: $12 \times 6 \times 3/2 \simeq 108$ mls.

Hydronephrosis: $24 \times 12 \times 6/2 = 884$ mls.

When each of the 3 dimensions is doubled, the resultant volume is increased by 8 folds.

- **Normal prostate** in an adult is the size of a chestnut, about 20 gm.
- **Enlarged prostate** (BPH) varies in size to simulate a lemon, a plum, an orange or a grapefruit, and according to the degree of posterior bulge into the rectal lumen:
 - (1+) Enlarged about size of **25 gm**, fills $< \frac{1}{4}$ rectal lumen
 - (2+) Enlarged about size of **50 gm**, fills $\frac{1}{2}$ rectal lumen
 - (3+) Enlarged about size of **75 gm**, fills $\frac{3}{4}$ rectal lumen
 - (4+) Huge prostate **> 100 gm** difficult to feel the whole gland.

3- Shape:

- Borders: Homogenous: round, beaded, heterogeneous.
- Margins may be well delineated (liver, spleen) or ill-defined (malignancy).
- Form:

A- Preserved organ form:

- Kidney: A bean has an outer convex and an inner concave border
- Testis: Oval
- Epididymis: Coma-shaped
- Prostate: Chestnut

B- Similar to a ball (globular) or an egg

C- Irregular

4- Surface:

- Homogenous or heterogeneous
- Smooth
- Bossy (lobulated, regular, large bosses)
- Nodular (regular, small bosses)
- Irregular
- Combinations

5- Sensation:

- Temperature
- Tenderness
- Texture mapping (smoothness or roughness)
- Crackling e.g. grating of multiple prostatic stones over each other

6- Skin surface changes:

- Inflammatory: redness, hotness, tenderness
- Infiltrative

CONSISTENCY

- The hand can be used as a model to assess consistency or degree of firmness:
 - **Hard**, stony, rocky or woody as any bony prominence
 - **Rubbery** as the tip of the nose
 - **Firm** as contracted thenar eminence of the thumb
 - **Indurated** as stretched extensor pollices
 - **Boggy** as non- contracted thenar eminence
- **Soft** as flesh or fatty areas and lobule of the ear:
 - Soft solid:** no fluctuation
 - Soft cystic:** fluid **fluctuation** (determined in two planes)

ATTACHMENTS

1. Mobility:

- Attachments will determine the mobility or fixity of the mass.
- Normally, the kidneys move up and down with respiration as well as forwards and backwards within the surrounding fat. The bladder moves freely with filling and voiding. The prostate has limited forwards and backwards mobility during DRE.
- **Fixity** of a mass may be due to advanced malignancy or inflammation and adhesions.

2. Reducibility:

- Primary varicocele is reducible on recumbency while secondary varicocele is non-reducing.
- Hernias can be reduced by relaxation and applying pressure.
- Undescended testis may be replaced downwards.

TRANS-ILLUMINATION

- It has been replaced by ultrasonography which defines the lesions much better.
- Trans-illumination is helpful in scrotal swellings.
- Translucency indicates clear fluid content of a hydrocele.
- It is lost if there is pus or blood.

PULSATIONS

Thrills, bruits and noises

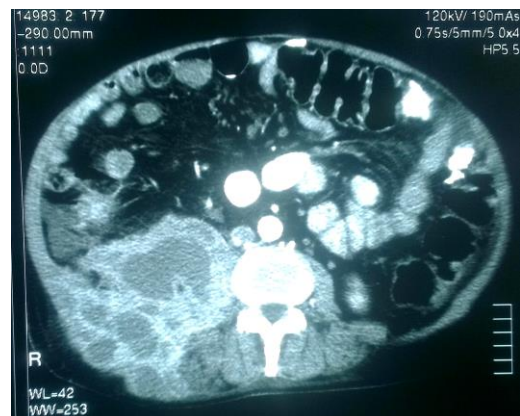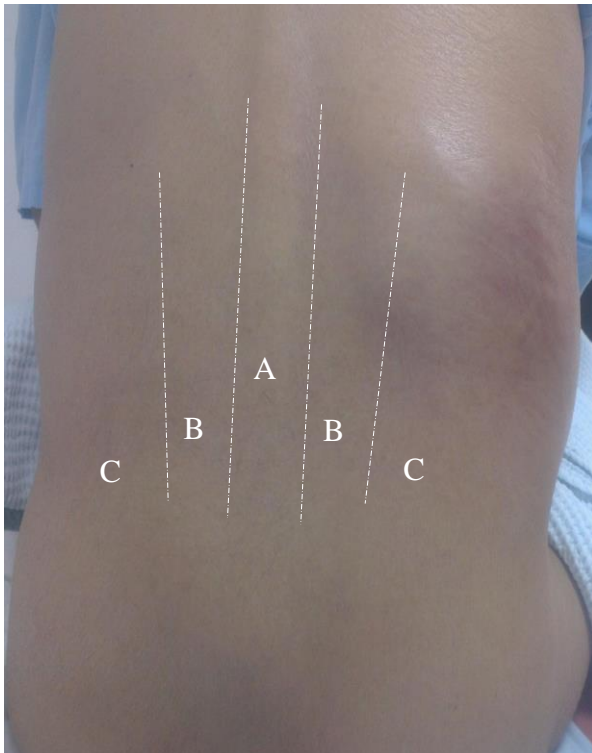
- a- Aneurysms.
- b- Hypervascular tumors.
- c- Transmitted pulsations by a close relation to a large artery.

CHAPTER 17: EXAMINATION OF THE BACK

The back of the patient is examined while sitting and the two sides are assessed for symmetry, tenderness, masses and abnormalities. Evaluation of the flank regions is important in renal disease.

- 1) **Chest:** Dorsal vertebrae and thoracic cage
- 2) **Abdomen:** There are 5 areas below the lowermost part of the ribcage above and the iliac crest of the boney pelvis below (figure 32): the vertebral column, 2 para-vertebral muscular regions, and 2 flanks (extension of lumbar areas).
- 3) **Pelvis:** Sacral area and gluteal regions

Figure 32. The back 5 areas: (A) vertebral column, (B) para-vertebral muscles, and (C) flanks, in a patient with signs of right perinephric abscess, and CT scan showing the renal and peri-renal infections.



Examination of the abdominal area of the back:

A. Spinal region:

- Inspect and palpate the spinal region.
- Deformities : Kyphoscoliosis (figure 33) , scoliosis, kyphosis, lordosis
- Meningocele is a protrusion of meninges through a defect in the spino-laminar segment. The sac may contain the spinal cord and cauda equina as in meningo-myelocele (figure 34).
- Spina bifida: defect of the spino-laminar component of the vertebral column, commonly in the lumbosacral region. There may be an overlying hair tuft (figure 35).
- Pott's disease: Tenderness
- Scars of previous surgery: Disc prolapse
- Swelling
- Fractured spine
- Bed sores

B. Muscles of the back: Perirenal collections e.g. inflammatory conditions may produce spasm of the muscles.

C. The costo-vertebral angle (CVA) and lumbar area:

Inspection:

- Swelling or fullness of CVA
- Signs of inflammation (figure 32)
- Scoliosis
- Search for a dimple over the lumbo-sacral area and palpate the sacrum in children with possible neuropathic damage (figure 36).

Palpation: Murphey's kidney punch determines deep-seated tenderness: The thumb is placed under the 12th rib and sharp jabbing movements are made.

Percussion:

- Resonant CVA (gas in the colon) is a good negative sign.
- Dull CVA:
 - Loaded colon
 - Renal mass
 - Peri-renal collection of fluids (urine, blood, pus, or combination)

Figure 33. Kypho-scoliosis in a patient with a stone in the left kidney

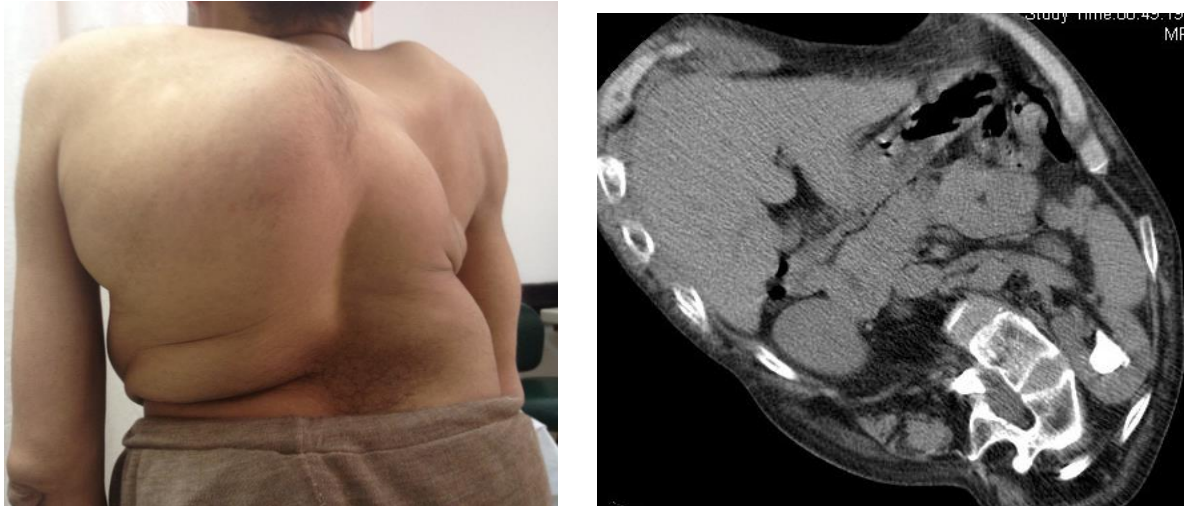


Figure 34. Myelomeningocele : There is a defect in the lumbar vertebrae through which the meninges and the spinal cord itself are pushed out in a fluid filled sac covered by a thin membrane in a newborn baby (courtesy of Dr A.T.Hafez).

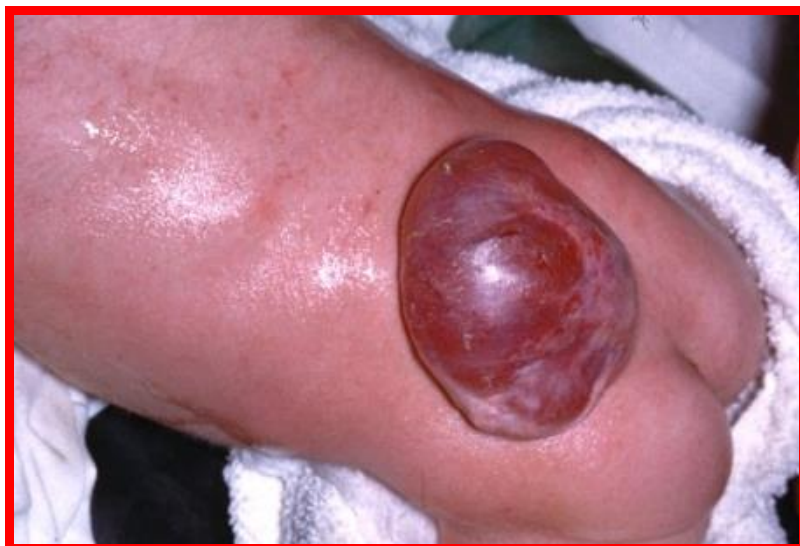

Figure 35. Lipoma in the lumbar area with a hair tuft overlying (A), and pre-sacral hemangioma and dimple (B) suggesting spinal pathology (courtesy of Dr A.T.Hafez).

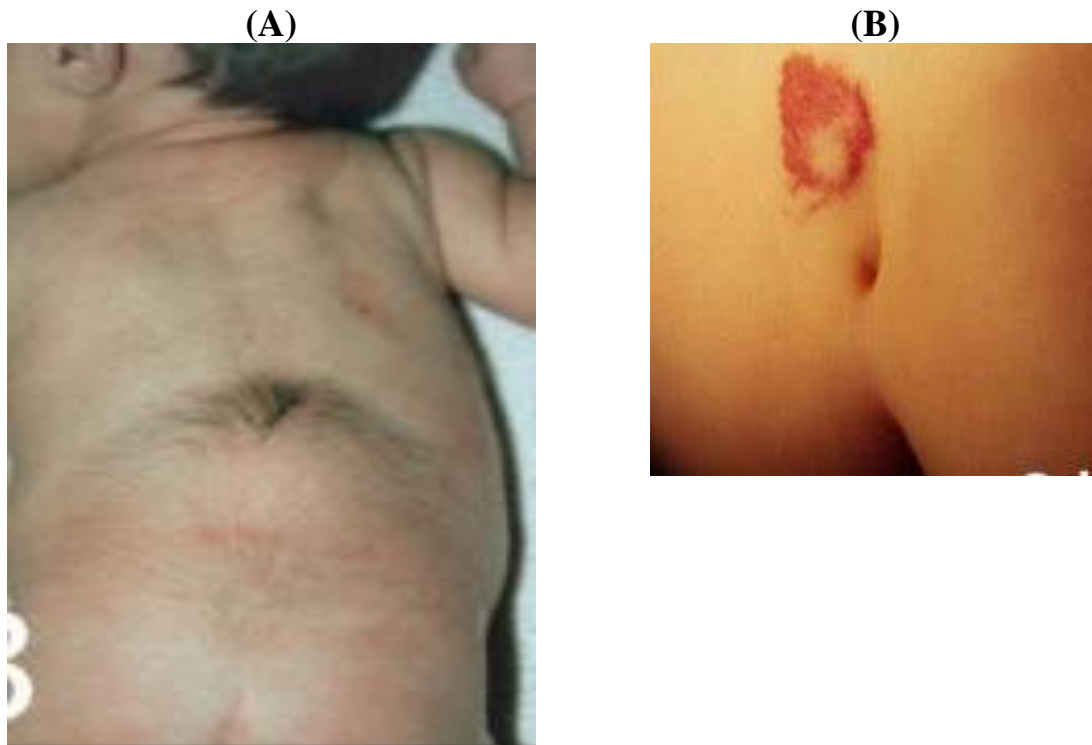
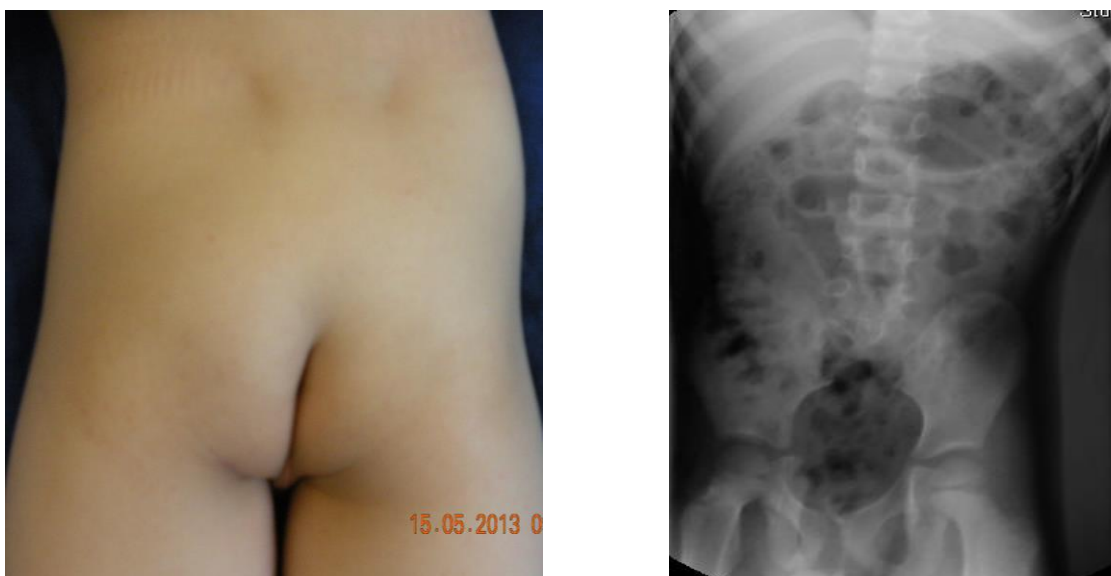

Figure 36. Flattened buttocks and deviated inter-gluteal cleft; a case of sacral agenesis seen in plain X-ray film (courtesy of Dr A.T.Hafez).



CHAPTER 18: EXAMINATION OF SCROTUM

The scrotum is a muscular out-pouching of the lower part of the anterior abdominal wall. Muscles of scrotum and spermatic cord contract and relax moving the testicle (both testis and epididymis) closer or farther away from the body to control the temperature of the testis. It is important, during scrotal examination, to make sure that the swelling is not a hernia (inguino-scrotal swelling). In cases of testicular masses, you can get above the lump (intra-scrotal swelling).

Cremasteric reflex:

- Stimulus: Light pinprick is applied to the medial thigh.
- It tests segments L₁, L₂. Sensory fibers of the femoral branch of the genitofemoral nerve and the ilioinguinal nerve are stimulated.
- Response: Contraction of cremasteric muscle with gradual elevation of the testis on the same side, through stimulation of the genital branch of the genitofemoral nerve.

Scrotal (dartos) reflex:

- Stimulus: Stroking of perineum or by applying ice cube to scrotum.
- To evaluate the thoracolumbar sympathetic and genitofemoral nerve pathways
- Response: Contraction of dartos muscle

Sebaceous cysts: Multiple, small cysts arising from the sebaceous glands that contain oily matter.

Carcinoma: Fungating mass or ulcer.

The scrotal skin may be anchored anteriorly by **syphilitic gumma** and posteriorly by **tuberculosis** of the testis.

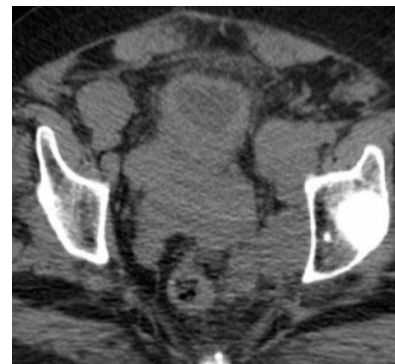
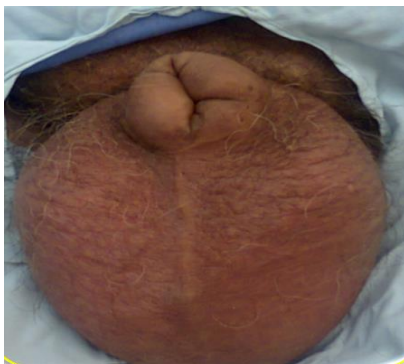Fournier's gangrene (necrotizing fasciitis):

Fournier's gangrene begins as acute scrotal and penile inflammation and can spread to involve the entire abdominal wall. The clinical features include a rapidly progressive scrotal edema and erythema with areas of dry gangrene. Subcutaneous crepitus may be felt, in the presence of gas-producing organisms.

- Although no usual causes of gangrene are evident, in some cases, Fournier's gangrene may be secondary to perirectal, ischiorectal, or periurethral abscess.
- Most of patients have diabetes mellitus.
- Fever, tachycardia and hypotension may be present.
- Management: Diagnosis, systemic broad spectrum antibiotics, drainage of causative abscess, and extensive debridement.

Scrotal edema may be localized or a part of generalized edema: acute (insect stings, angioneurotic, trauma), or chronic (heart failure, nephrotic syndrome, renal failure). It may result from lymphatic obstruction e.g. in malignancy (figure 37).

Figure 37. Scrotal edema secondary to lymphatic obstruction in a patient with prostatic cancer and extensive pelvic lymphadenopathy seen in CT scan.



THE TESTIS

Palpate parts in a definite order (figure 38). Start with the normal testis.

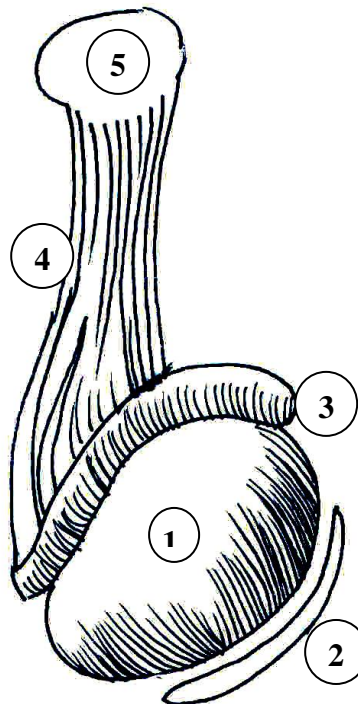
1. The body of testis, compare with the opposite.
2. The tunica vaginalis is blended with the anterior surface of the testis.
3. The epididymis is coma-shaped and composed of head (globus major), body, and tail (globus minor).
4. Palpate the spermatic cord up to the external inguinal ring. Pass the thumb above and the next 2 fingers under the neck of scrotum and pinch the index finger down upon them. Slip fingers from within outwards.

Vas deferens: Hard whipcord, the most posterior

Small cords: Cremasteric muscle, nerves, and vessels

5. The external inguinal ring.

Figure 38. Examination of the testis: (1) body of the testis (2) tunica vaginalis (3) epididymis (4) spermatic cord (5) external inguinal ring



- **THE NORMAL TESTIS:**

Site: Both testes are intra-scrotal with the long axis in a vertical direction. The left testis is a bit lower than the right.

Size: Both testes are normally equal in size.

Vertical length = 4.5 x antero-posterior = 2.5 x transverse = 2 cm.

Obstructive azoospermia: high normal size

Non-obstructive azoospermia: small, low normal volume

Shape: Ovoid organ

Surface: Smooth

Sensation: Normal special testicular sensation is felt on gentle pressure and this particular feeling may be lost in testicular cancer.

Skin over it: Freely movable

Consistency: Firm, homogenous

Testis is freely movable and separable from the epididymis.

- **INCOMPLETELY DESCENDED TESTIS:**

The testis is arrested in some part of its path from the retroperitoneum to scrotum (figure 39). An associated indirect inguinal hernia is often present.

- At the neck of scrotum
- In the external inguinal ring
- In the inguinal canal: It disappears if abdominal muscles contract.
- Intra-abdominal

The corresponding hemi-scrotum is underdeveloped. When both testes are impalpable, the condition is known as **cryptorchidism**.

Complications of undescended testis:

- a) Testicular cancer (figure 40)
- b) Fertility problems
- c) Testicular torsion
- d) Trauma

Figure 39. Potential sites of incompletely descended testis: Abdominal, inguinal and scrotal.

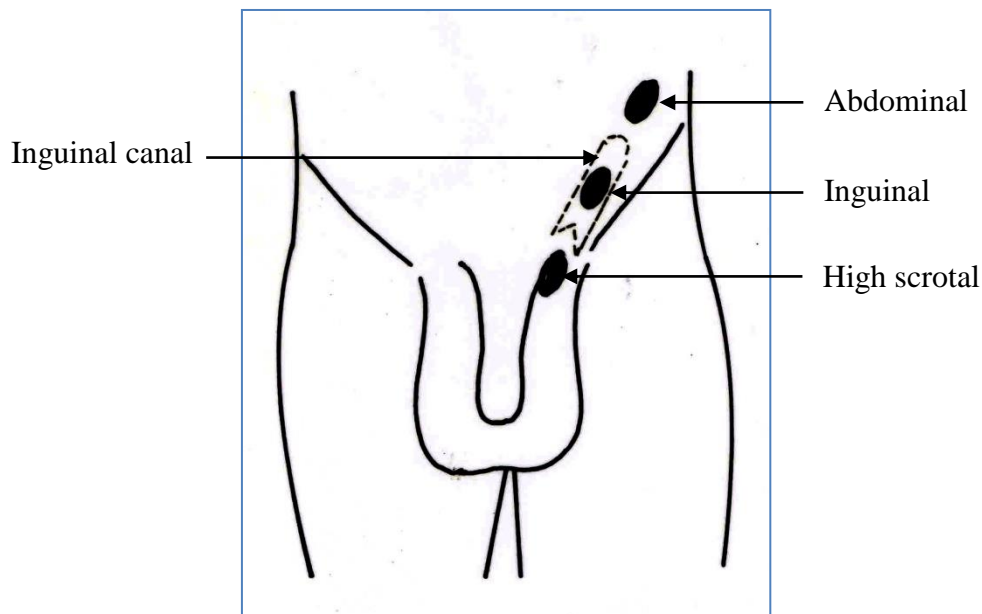
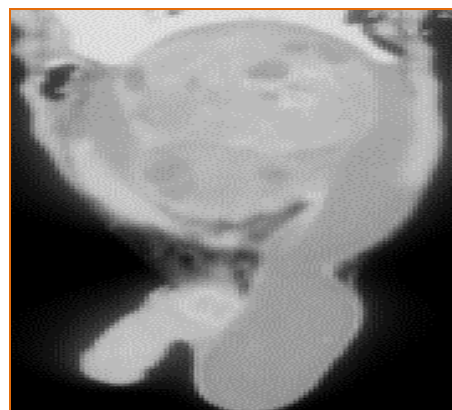
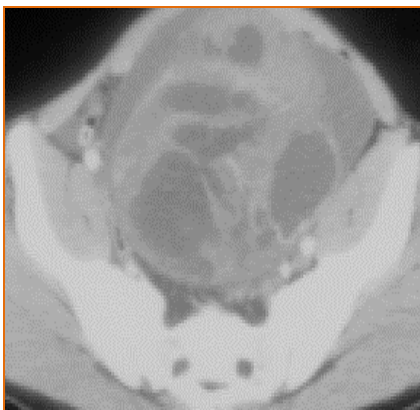
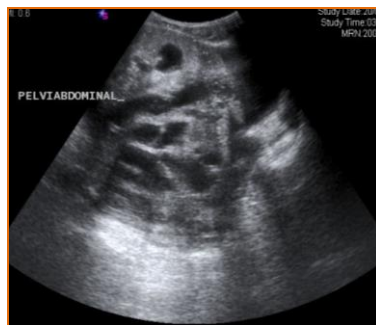
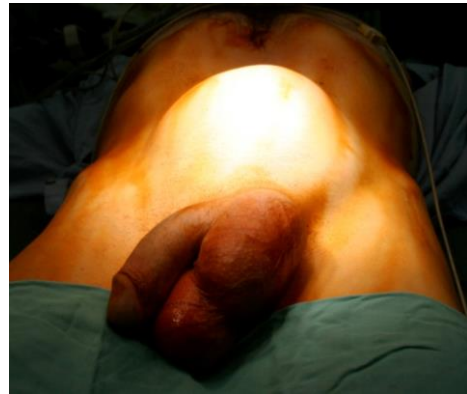
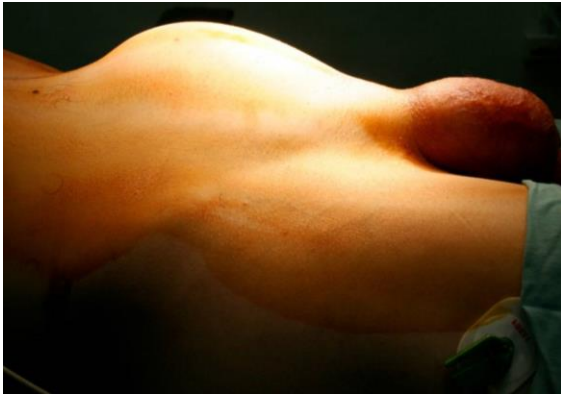Figure 40. A 36-year-old man presents complaining of a progressive lower abdominal swelling of 4 months duration. Clinical examination reveals a large solid mass in the suprapubic region. Scrotal examination reveals a normal right testis, and a congenital hydrocele with no evident testis on the left side. AFP is very high. Ultrasound shows a large solid mass. CT scan shows an encapsulated large pelvi-abdominal mass 12x13x15cm, with areas of cystic degeneration.



- **THE RETRACTILE TESTIS:**

- Occurs in childhood due to an overactive cremasteric reflex when the skin of scrotum or thigh is stimulated.
- Can always be brought to bottom of scrotum by squatting or flexion of the thigh to abdomen (chair test; figure 41) in a warm room.
- Scrotum is well-developed.
- Retractable testis is normal and requires no treatment.

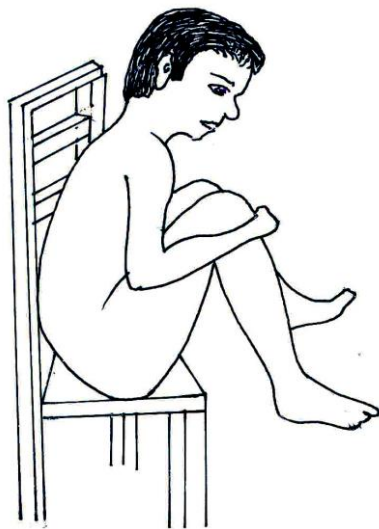

Figure 41. The chair test

- **ECTOPIC TESTIS:**

- The testis is abnormally placed outside its path (figures 42, 43):
 - At the superficial inguinal pouch: subcutaneous, easily felt, and bulges more if the abdominal muscles contract.
 - In the perineum,
 - At the root of the penis,
 - In the femoral triangle
- The testis is usually well-developed but liable to injury.

Figure 42. Potential sites of ectopic testis: (1) peno-pubic, (2) in the superficial inguinal pouch, (3) femoral and (4) perineal.

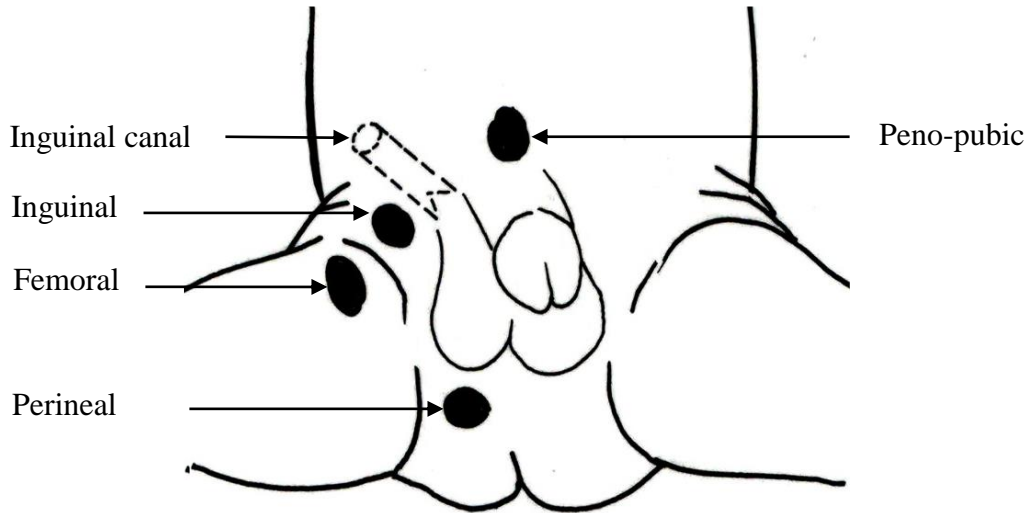
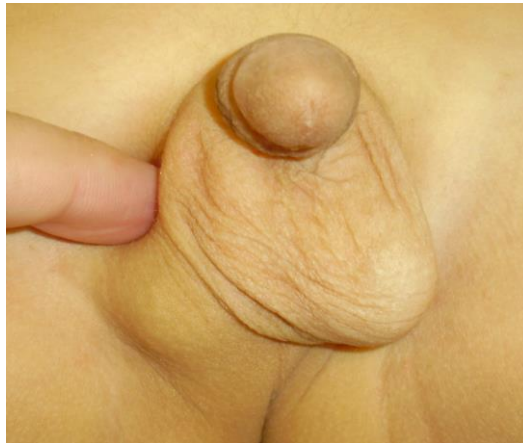

Figure 43. Ectopic right testis in the perineal region (courtesy of Dr T. Helmy).



- **TORSION OF THE TESTIS:**

Testicular torsion results in twisting of the testis and epididymis on the spermatic cord with occlusion of first the venous drainage, and later the arterial supply of the testis. Therefore, testicular torsion is a true vascular emergency. In newborn boys, the twist is extravaginal. Testicular torsion is

most common around puberty, when the tunica vaginalis is voluminous and permits rotation of the testis on a long meso-orchium (intravaginal torsion).

- **History:**

Teenager around puberty, the most common peak age is at 14.

It occurs less frequently during the first year of life.

Acute abrupt onset, awakening the patient from sleep (80%).

Well last night

Pain peaks immediately.

Nausea, vomiting

50% history of similar episodes (warning attacks)

No recent urethral instrumentation

No exposure or history of sexually transmitted diseases

- **Physical examination:**

No fever, no urethral discharge, normal external urethral meatus.

Swollen scrotal side, testis lies higher than its fellow.

Long standing ischemia may lead to gangrene (figures 44, 45).

Non-palpable epididymis.

Prehn's sign negative i.e. ipsilateral scrotal elevation does not relieve pain in torsion. In epididymo-orchitis pain is relieved.

Ipsilateral absent cremasteric reflex

Opposite side: transverse lie or upside down inversion instead of the normal vertical axis (figure 46).

Urinalysis is normal.

Differential Diagnosis of acute scrotal swelling is shown in table 17.

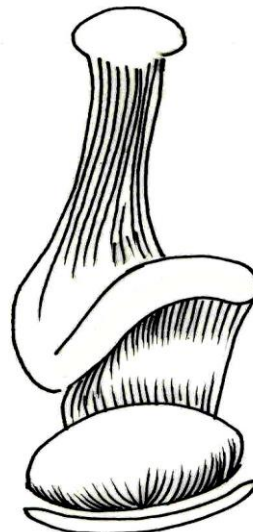
Figure 44. Torsion of the right testis of 18 hours duration in a patient aged 20. Upward retraction of the swollen testis is noticed. Exploration demonstrates twisting of the cord and gangrene of the testis.

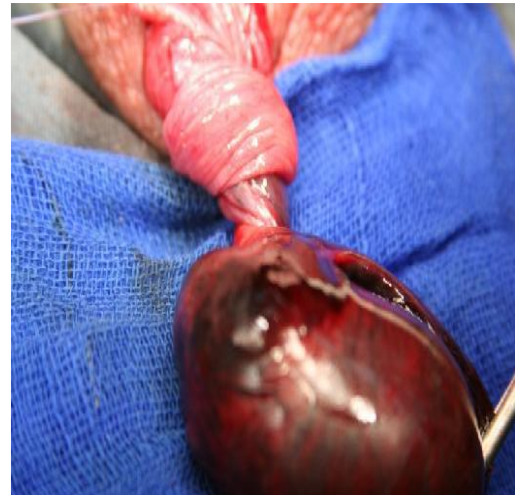
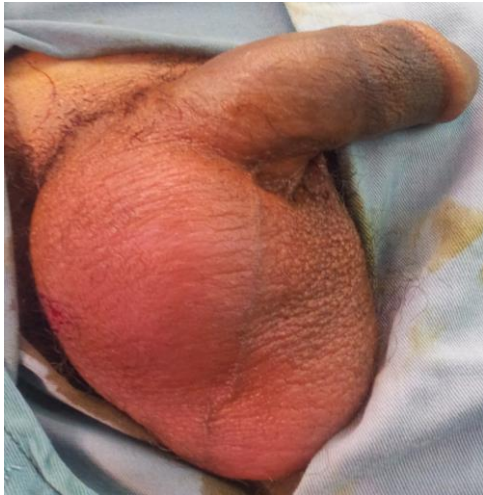
Figure 45. Left testicular torsion of 24 hour duration in a 10-year-old boy, causing gangrene.

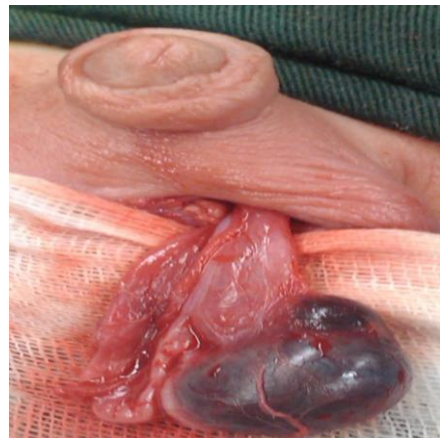

Figure 46. Examination of the opposite testis in testicular torsion showing a transverse lie and a long meso-orchium



- **TESTICULAR TRAUMA:**

Many accidents can cause testicular injuries.

- a. **Blunt trauma:**

- A kick to the scrotum
- Sport injury
- Motorcycle or bicycle accidents
- Falls
- Straddle injuries

- b. **Penetrating injury:** Stab wounds, gunshot wounds and explosive trauma (figure 47).

- c. **Degloving:** The scrotum is torn away, and the testis is exposed such as trauma with heavy machinery e.g. industrial accidents.

- d. **Animal bites:** Usually a dog

Types of testicular trauma:

Rupture: A kick or baseball to the groin causing a tear in the covering of the testis may lead to a testicular rupture.

Fracture: An injury that breaks the testicular tissue with or without tearing the protective covering.

Contusion: An injury to blood vessels of the testis causing bleeding and bruising.

Hematocele: Blood collects within the tunica vaginalis around the testis.

Dislocation: It may be seen in motorcycle accidents, when the testis collides with a hard object, and is pushed up to another area.

Figure 47. Explosion accident while a bully aged 29-year was manipulating his bomb that exploded and caused degloving injury of the penis and scrotum. Both testes ruptured and necessitated surgical removal. A burn was observed in the left groin. Splinters and bomb fragments retrieved are shown (courtesy of Dr A. el-Shal).

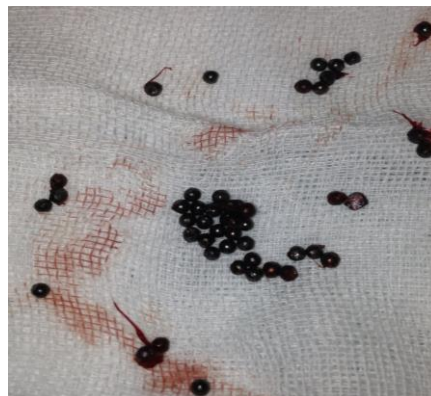
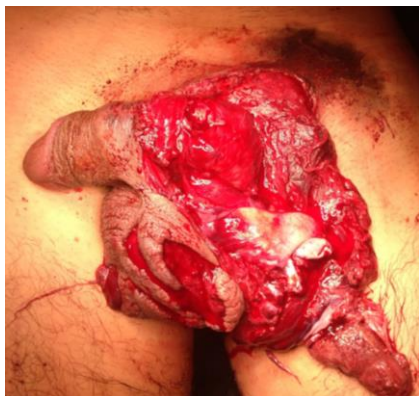
Table 17. Differential Diagnosis of Acute Scrotal Swelling

Features	Tumor	Epididymo-orchitis	Torsion
Etiology	Seminoma or non-seminomatous germ cell tumors (NSGCT)	Acute inflammation retrograde or blood-borne	Twisting of testis on the cord
Age	20-40	Any, usually >20	12-18
Predisposing factors	Unknown Undescended testis Trivial trauma causes hematocele and acute scrotal swelling.	Operations on prostate, urethra Post catheterization Gonorrhea, mumps Idiopathic	Long mesorchium and horizontal lie
Symptoms	Painless swelling Sense of heaviness	Acute onset of pain, fever, rigors, dysuria.	Sudden severe painful swelling of testis
Signs	Hard painless swelling with absent testicular sensation	Swollen, red, tender testis, hydrocele, pain decreases with scrotal elevation Urine: pus & organisms	The testis is extremely tender and elevated. Opposite testis: Bell-clapper deformity.
Ultrasound	Testis solid mass	Normal or increased blood flow	Absent blood flow if gangrenous
Treatment	Radical orchiectomy. Further treatment according to pathology, tumor stage, and serum markers.	Bed rest, Antibiotics, Scrotal elevation.	Detortion and fixation if viable or within 8 hrs. Orchiectomy: after 12 hrs if not viable. Fixation of the other testis.

- **ATROPHY OF THE TESTIS:**

- Torsion

- Mumps orchitis

- Epididymo-orchitis

- Operations causing possible vascular injury: Inguinal hernia, varicocele, orchidopexy

- Varicocele

- Klinefelter's syndrome: bilaterally small testes

- Liver cirrhosis

- Estrogen therapy for prostate cancer

- **ABSENT TESTIS:**

- Incompletely descended testis: It may be intra-abdominal or inguinal, therefore carefully examine the inguinal canal for a discrete swelling. An abdominal mass with empty hemi-scrotum indicates a possible tumor of an incompletely descended testis (figure 48).
- Surgical removal.
- Atrophied and missed.
- Congenitally absent testis.

- **IMPALPABLE TESTIS:**

- Fluid prevents palpation: Hydrocele, hematocele, lymphocele, pus, and scrotal edema.
- Bowel prevents palpation: Incarcerated hernia.

- **ORCHITIS:**

- In cases of acute inflammation testis and epididymis are usually involved.
- The testis is high, swollen and tender.
- Overlying skin is red and hot.
- The patient is unwell and febrile.
- Chronic infections may eventually give rise to atrophied testis.

- **TESTICULAR TUMOR:**

The majority of patients with a testicular tumor notice a swelling in the testis. **Any solid, firm mass in the testis must be considered to be malignant until proven otherwise, whereas all masses arising from the spermatic cord are benign.**

History:

Testis cancer is the most common solid tumor in men ages 20-35 years. Germ cell tumors account for about 96% of cases.

Cryptorchidism

Atrophy

Trauma: 10-15% of patients will give history of a recent trauma to the testicle, and may attribute their swelling to the injury. Therefore, it may be a rule to explore every hematocele.

Pain is not usual in testicular tumors; 30% of patients have some pain. About 10% of cases record a wrong diagnosis of inflammation, which accounts for a delayed treatment.

Physical examination:

Supraclavicular mass usually on the left side.

Gynecomastia: The testicles should be always examined.

Abdominal mass in the upper abdomen

Abdominal, inguinal, pubic and scrotal scars

Opposite testis

Extensive lymphadenopathy may result in lower limb edema.

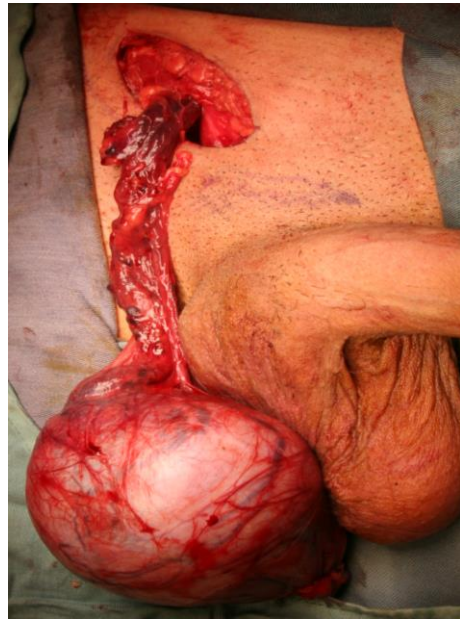
Scrotal examination:

- A firm intra-testicular progressively enlarging solid lesion.
- The testis is enlarged, smooth, firm (figure 49).
- Later it is irregular and hard.
- Testicular sensation may be lost.
- Reactive or secondary hydrocele 10%

Figure 48. A 32-year-old man presents with a lower abdominal swelling of 6 months duration. He had received chemotherapy for biopsy-diagnosis of gastro-intestinal stromal tumor, with poor response. Clinical examination reveals a solid mass in the suprapubic region. Scrotal examination reveals a solitary intra-scrotal left testis with no past history of surgery. Surgical removal of the mass revealed seminoma of the right undescended testis (courtesy of Dr K. Atallah).

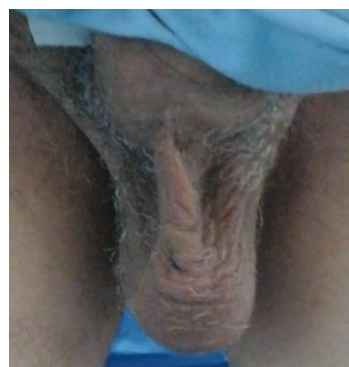

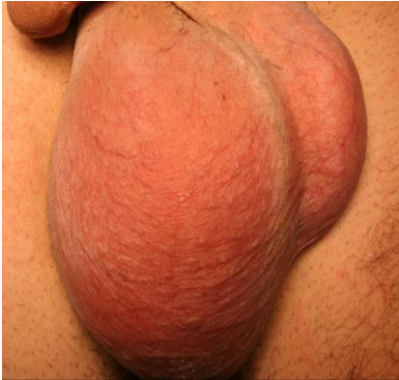Figure 49. Radical orchidectomy for right testicular tumor.



Clinical staging of testicular tumors:

Stage I or A: Locally confined disease

T1	Tumor confined to testis
T2	Tumor beyond tunica albuginea
T3	Tumor is rete testis or epididymis
T4a	Tumor extends into spermatic cord.
T4b	Tumor invasion of the scrotum

Stage II or B: Spread to regional lymph nodes (infra-diaphragmatic)

Stage III or C: Spread beyond retroperitoneal lymph nodes (supra-diaphragmatic) or visceral disease.

Leydig cell tumors

- 90% are benign with frequent hormonal disorders.
- Prepubertal boys:
 - Precocious puberty
 - Prominent external genitalia
 - Masculine voice
 - Hair growth
 - Testicular mass
- Adults:
 - Erectile dysfunction
 - Gynecomastia

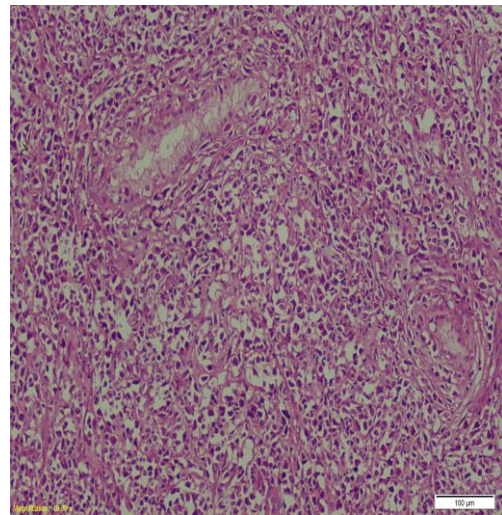
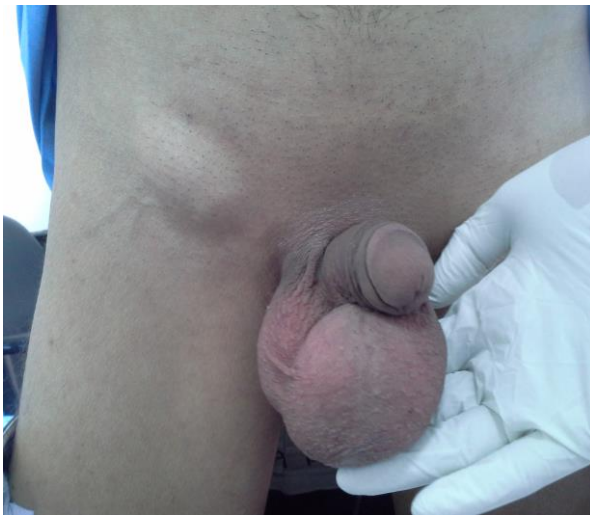Sertoli cell Tumor

- 80-90% of cases are benign with infrequent hormonal disorders.
- Age is around 45 years.
- It is suspected in cases of testicular mass with gynecomastia.

Secondary Tumors of the testis

- **Lymphoma (figure 50):**
 - Rare NHL, age above 50
 - Lymph-adenopathy may be present
 - Most common secondary tumor of testis
 - Most common bilateral tumor (50%)
 - Usually a systemic disease

Figure 50. Non-Hodgkin Lymphoma was diagnosed in a 57-year-old man with left testicular mass and right inguinal lymphadenopathy. Histopathology: Large B cell lymphoma of (courtesy of Dr M El-Baz).

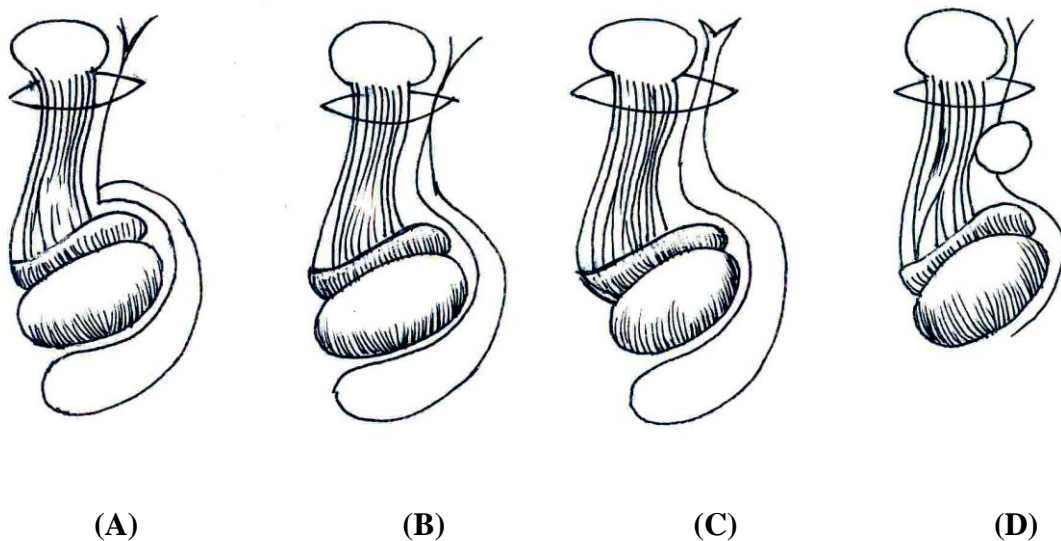


- **Leukemia:**
 - 8% of children with ALL
 - Diffuse testicular swelling
 - Scrotal discoloration
 - Bilateral in 50% of cases
- **Metastatic:**
 - Multiple testicular masses
 - Primary lesion may be prostate, lung, intestinal, kidney cancers.

HYDROCELE

Hydrocele is an abnormal collection of serous fluid in some part of the processus vaginalis, usually the tunica (figure 51). The testis may be difficult to feel, but when the testis can be distinguished, it lies posteriorly. Hydrocele is fluctuant and transilluminates.

Figure 51. Types of hydrocele: (A) Vaginal, (B) Infantile, (C) Congenital and (D) Hydrocele of the cord.



CONGENITAL HYDROCELE:

- a) Vaginal hydrocele: A non-tender fluid-filled swelling within the tunica vaginalis. It is very common, and the examining fingers can get above it.
- b) Infantile hydrocele: The processus vaginalis is obliterated at the external inguinal ring.
- c) Congenital hydrocele: The processus vaginalis is patent and communicating with the peritoneum. The swelling is reducing in recumbent position.
- d) Encysted hydrocele of the cord.

ACQUIRED HYDROCELE:

Primary or idiopathic

Secondary to testicular disease:

- Torsion
- Inflammation

- Obstruction of lymphatics: Fibrosis, cancer, surgery
- Trauma to the testicle
- **Tumor:** 10% of testicular cancers manifest with a reactive hydrocele. Ultrasonography is useful to confirm.
- Others e.g. heart failure

HEMATOCLE is a large painful hydrocele containing blood, caused by trauma, tapping of a hydrocele, and occasionally on top of a testicular tumor. Injury will give rise to a split in the visceral layer of the tunica vaginalis with spillage of blood and testicular tissue.

CHYLOCELE (Filariasis): In some tropical countries, the adult *Wuchereria bancrofti* worms live in the pampiniform plexus, and cause fibrosis and inflammation. This will give rise to tremendous hydrocele, and elephantiasis of the scrotum.

THE EPIDIDYMIS

It is a specialized collecting apparatus where spermatozoa are matured before travelling up the vas deferens. Normal epididymis is comma-shaped and 6 cm length.

Globus major (head) is up near the superior pole of the testis; body is posterior and globus minor (tail) is low.

EPIDIDYMITIS:

- Acute epididymo-orchitis occurs as a sequel of urethral catheterization or endoscopic procedures, or secondary to hematogenous or ascending infection.
- Age is the most important criterion to distinguish from torsion.
- It usually occurs in sexually active men after age 20.
- Fever is present.
- Urethral discharge may be present.
- Epididymis is enlarged and tender.
- Testis is indistinguishable from the epididymis.
- No change in position of the testis.
- Vas may be thickened.

- Cremasteric reflex is usually present.
- Pain is relieved in response to scrotal elevation (Prehn's sign).
- Tuberculosis should be ruled out in chronic epididymitis. The epididymis is nodular, hard with caseating abscesses. The vas is beaded and shortened. The testis is involved late.

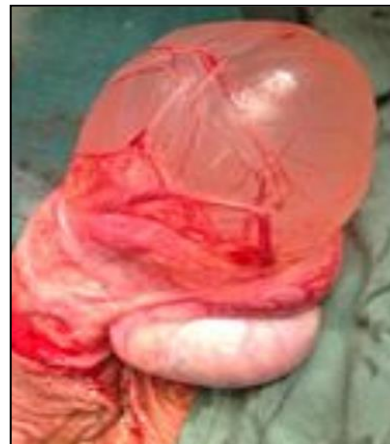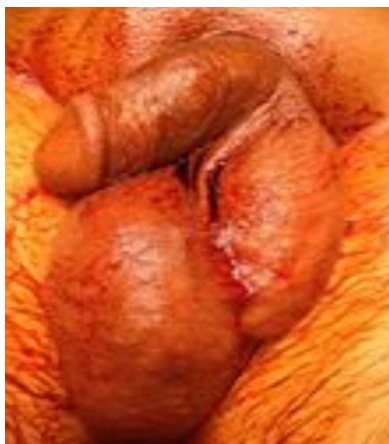SPERMATOCELE:

- Mass in upper pole on top of the testis.
- Variable in size
- Firm in consistency
- Transilluminates but not so brilliantly.
- Contains dead sperms.

EPIDIDYMAL CYSTS (figure 52):

- May be bilateral
- Any part of epididymis
- Lobulated
- Small
- Harmless
- Painless
- Transilluminate
- Posterior and separable from the testis which is normal.

Figure 52. Right epididymal cyst



ADENOMATOID TUMOR OF TESTIS:

- Most common paratesticular tumor.
- Mass in lower pole.
- Painless solid mass.
- Older male.
- Not growing.
- Incidental.
- No history of epididymitis, cryptorchidism or trauma.
- Benign variant of mesothelioma.

RHABDOMYOSARCOMA

The testis and epididymis may not be distinguishable from the tumor.

ABSENT EPIDIDYMIS: Testis is present and normal.

DIFFUSE ENLARGEMENT: after vasectomy.

TUBERCULOUS EPIDIDYMO-ORCHITIS:

Epididymis is thickened and craggy.

Vas is considerably thickened with beading and irregular nodulation.

The scrotum may be anchored posteriorly.

Draining scrotal sinus

Nodular, tender prostate

THE SPERMATIC CORD

The spermatic cord suspends the testis in scrotum and runs into the inguinal canal. It contains vas deferens, arteries, veins, and nerves.

The spermatic cord is surrounded by internal spermatic fascia from the transversalis fascia, cremasteric muscle and fascia from the internal oblique and external spermatic fascia from the external oblique aponeurosis.

VAS DEFERENS:

The normal vas lies along the posterior aspect of the cord and feels firm and wire-like. It runs from the epididymis to the external inguinal ring.

Multiple, knotty swellings along the vas are characteristic of tuberculosis.

Inflammatory cord swellings are seen in cases of schistosomiasis and filariasis.

Mass in vas is seen bilaterally after vasectomy.

Congenital bilateral absence of vas deferens (CBAVD):

No palpable vasa

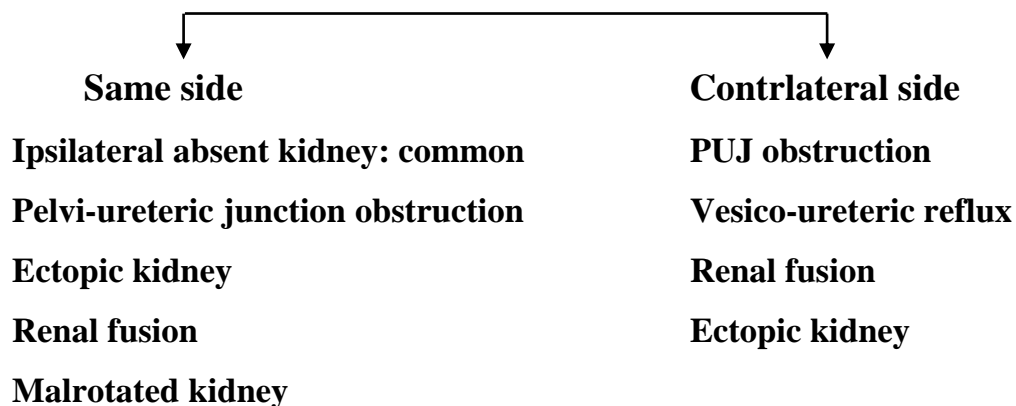
Epididymal remnant is firm

Testes: normal size & consistency

Low-volume, acidic semen

Unilateral absence of vas deferens: The possible associated urological abnormalities are enlisted in figure 53.

Fig 53. Unilateral absence of the vas deferens: Associated anomalies



Zinner syndrome refers to the triad of ipsilateral renal agenesis, seminal vesicle cysts and ejaculatory duct obstruction.

VARICOCELE

PRIMARY VARICOCELE:

- Varicose dilatation and tortuosity of the veins draining the testicle.
- Warm room, standing position and Valsalva's maneuver allow detection.
- Apparent when patient is standing and disappear or decrease in size when the patient lies down.
- Classification:
 - Subclinical: not palpable or visible. Reflux found upon Doppler examination.
 - Grade 1: Palpable during Valsalva maneuver only.
 - Grade 2: Palpable at rest, but not visible.
 - Grade 3: Visible and palpable at rest.
- 25% of adult males.
- Because of the greater hydrostatic pressure in the left testicular vein compared with the right, 95% of varicoceles occur on the left side.
- The ipsilateral testis is smaller in size in 25%.
- The pampiniform plexus feels like **a bag of worms**.



SECONDARY VARICOCELE:

It is important in RCC with venous tumor thrombus.

Patients with sudden onset of a varicocele, a right-sided varicocele or a varicocele that does not reduce in supine position should be suspected to have RCC with IVC thrombus on the right or a retroperitoneal tumor with obstruction of the spermatic vein on the left.

A comparison between primary and secondary varicoceles is enlisted in table 18. The possible signs in cases of kidney cancer are: cervical left supraclavicular lymphadenopathy, palpable renal mass, new-onset varicocele and bilateral lower limb edema. Dilated veins may be noted in abdominal examination.

Table 18. Comparison of Primary and Secondary Varicoceles

	Primary varicocele	Secondary varicocele
Age	Since puberty, early adults	Above the age of 40 years
Onset	Chronic	Acute, new-onset
Symptoms	Asymptomatic Scrotal discomfort Infertility	Hematuria Abdominal Pain Mass in the loin
Side	Left in 95% of cases 	Mostly on the right side 
Drain with gravity	Varicocele goes away when patient lies down.	It does not collapse with recumbency.
Associated signs	Ipsilateral testis is smaller in 25% of cases	- Normal ipsilateral testis. - Palpable renal mass. - Bilateral lower limb edema. - Left supraclavicular nodes
Etiology	Left testicular vein enters the left renal vein. Incompetent valves Nutcracker compression of left renal vein between aorta and superior mesenteric artery.	Involvement of the IVC by kidney cancer thrombus, or compression of renal vein by: Testis cancer metastasis Lymphoma Retroperitoneal tumor

VALUE OF EXAMINATION OF TESTIS AND SCROTUM IN UROLOGY CASES:

- **Congenital :**

- Absent vas - absent ipsilateral kidney
- Undescended testis - hypospadias

- **Inflammatory :**

- UTIs: Complicated by epididymo-orchitis
- TB: Beaded vas

- **Traumatic :**

- Hematoma & urinary extravasations

- **Vascular :**

- Secondary varicocele in kidney cancer with IVC thrombus

- **Neoplastic :**

- Retroperitoneal lymph node metastases of testicular cancer may cause hydronephrosis.

Scrotum: Hematoma, urinary extravasations, and edema

Testis & Epididymis: Carcinoma, infection, hematocele, and hydrocele

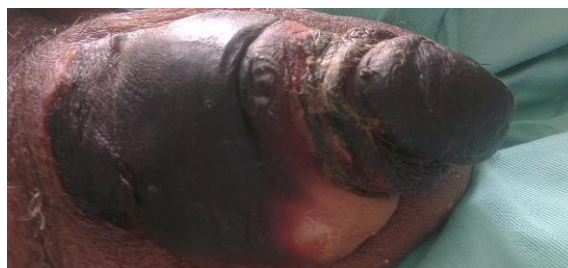Spermatic Cord: Varicocele, hydrocele, absent vas, and beaded vas (TB).

CHAPTER 19: EXAMINATION OF THE PENIS AND PERINEUM

INSPECTION:

- Size of the penis: Development, maturation and hair distribution
- Glans: Ulcers, scars ,nodules or signs of infection
- Prepuce (foreskin): Circumcised or not; a circumcised man is not likely to have penis cancer and his wife is less likely to develop carcinoma of the cervix.
- Color of skin (figure 54)
- Site and caliber of the urethral meatus: The normal meatus is a vertical slit at the tip of the glans.
- Compress the glans gently between your index finger above and your thumb below to open the urethral meatus and inspect it for any discharge.
- Discharge of urethritis or any staining of the underwear. If penile discharge is present, assess the amount, color and consistency, and any fever, chills, rash. Have a glass slide and culture materials ready.
- Any abnormal curvature
- Any visible lesion: Cancer, chancre, ulceration, warts, cysts.

Figure 54. Gangrene of the glanspenis and skin of the penile shaft in a 73-year-old man following radical cystectomy and urethrectomy.



PALPATION:

- Put on a pair of gloves.
- Palpate any visible lesion and the whole length of the shaft for any abnormality of the penis, noting any tenderness or induration.
- Retract the foreskin to examine the glans and meatus, then replace it.
- Palpation of the male urethra.
- Palpation of the inguinal lymph nodes

PEYRONIE'S DISEASE (figure 55): Curvature of the penis secondary to formation of fibrous nodule in the tunica albuginea. Penile trauma appears to be the most likely factor. The patient complains of pain and curvature during erection, erectile dysfunction, hard plaques on the penis, shortening of the penis. Physical examination reveals palpable, non tender, hard plaques along the tunica albuginea.

Associated conditions include Dupuytren's contracture, plantar fascial contractures, previous penile trauma, diabetes mellitus, and arterial diseases.

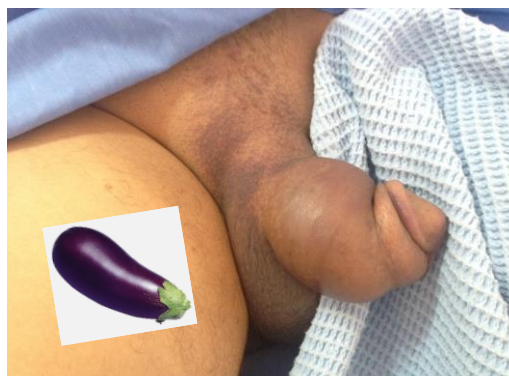Figure 55. Peyronie's disease with different penile curvatures (courtesy of Dr Adel Al-Dayel)



PENILE FRACTURE (figure 56):

- Trauma to the erect penis.
- Tear of the tunica albuginea, surrounding the corpora cavernosa, followed by penile detumescence and ecchymosis.
- Urethrography in suspected urethral injury.

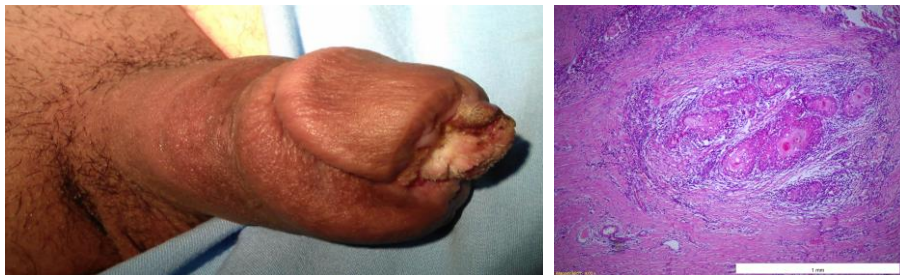
Figure 56. Fracture penis "eggplant deformity": Swelling, hematoma and deviation are noticed.



CARCINOMA OF THE PENIS (figure 57):

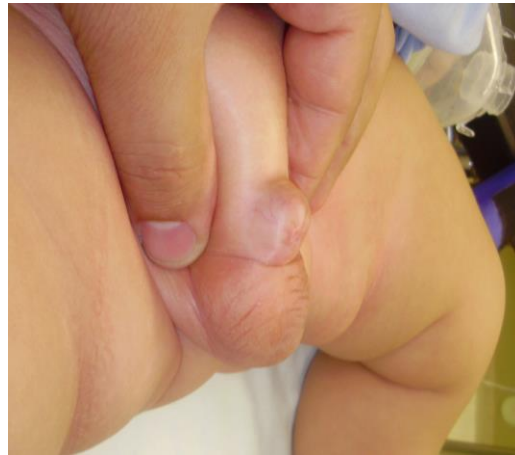- Unknown in Muslims and Jews
- Seen in people who don't practice circumcision.
- Delayed presentation >1year (embarrassment, fear, ignorance)
- Two forms: Hard painless papilliferous mass and a non tender ulceration with indurated base.
- It may be masked by the prepuce. Persistent penile sore is suspicious.
- Local infection is common causing evil-smelling discharge which later becomes blood-stained.
- Concomitant balano-posthitis.
- Enlarged inguinal lymph nodes: inflammatory or infiltrative.

Figure 57. Carcinoma of the penis: A solid mass with necrotic surface is seen in the glans penis infiltrating the left corpus cavernosum. Histopathology shows sheets of malignant squamous cell carcinoma infiltrating the subepithelial tissue of the penis (courtesy of Dr M El-Baz).

**PHIMOSIS:**

- Stenosis of the preputial opening preventing retraction of the foreskin and exposure of the glans.
- Insignificant in children and will resolve.
- Secondary to scarring such as balanitis xerotica obliterans and balano-posthitis.
- Phimosis might be iatrogenic (figure 58)
- Chronic retention of urine may occur with ballooning of the prepuce resulting in a second bladder.
- May lead to chronic infection and carcinoma of the penis.
- Treatment: Circumcision.

Figure 58. Post-circumcision phimosis (courtesy of Dr T. Helmy)



PARAPHIMOSIS:

- The preputial skin is retracted and acts as a constriction ring.
- Iatrogenic: a complication of urethral catheterization if the foreskin is not replaced to its normal position..
- Lymphatic and venous drainage of tissue distal to the ring is impaired leading to edema and more constriction and necrosis of the glans.
- Treatment: Dorsal releasing incision and later circumcision.

BALANITIS: Inflammation of the glans penis.

Balano-posthitis: Inflammation of the glans and foreskin.

Causes:

- Candida albicans (diabetic patients).
- Herpes.
- Drug eruptions.
- Poor hygiene.
- Cancer.

PENILE ULCERS (table 19):

- Herpes simplex (vesicles followed by ulceration).
- Syphilis: non-tender ulceration.
- Malignancy: Squamous cell carcinoma is non-tender.
- Behcet's syndrome.

Table 19. Ulcers of the Penis

	Etiology	Features	Pain	Lymphadenopathy
Genital herpes	<i>Herpes simplex virus</i>	Vesicles on glans and shaft → papules → pustules → break to erosions. Primary: Systemic symptoms Recurrent: Localized ulcers	Yes	No
Syphilis	<i>Treponema pallidum</i>	Single ulcer (chancre)	No pain unless infected	Bilateral
Chancroid	<i>Hemophilus ducreyi</i>	Multiple ulcers	Tender	Bilateral
Lymphogranuloma venereum	<i>Chlamydia trachomatis</i>	Single small vesicle ulcerates.	Not usual	Unilateral, painful (masses, abscesses, fistulae) → Bubos
Granuloma inguinale (Donovanosis)	<i>Calymmatobacterium granulomatis</i>	Single, progressive, beefy-red, highly vascular ulcer Likely to be inguinal	No	No
Penile cancer	<i>Squamous cell carcinoma</i>	Single	Not initially painful	Infected and/or metastatic

HYPOSPADIAS:

It is an abnormality in which the opening of the urethra is on the inferior surface of the penis, instead of at the tip of the glans of the penis. The urethral meatus opens anywhere along a line running from the tip along the inferior aspect of the shaft to the junction of the penis and scrotum or perineum. Parents will notice an abnormal spraying during urination. In cases of severe hypospadias, such as the absence of testicles in the scrotum, and in case of pseudovaginal perineo-scrotal hypospadias, a sex determination is essential.

1. Location and caliber of the external urinary meatus on the under-surface of the penis (figure 59): Glandular type is the most common, penile, peno-scrotal and perineo-scrotal.
2. Downward penile curvature: Chordee (figure 60)
3. Distal foreskin: Circumcised or not. A distal hypospadias may be suspected in an uncircumcised boy from an abnormally formed foreskin producing a hooded appearance of the penis because only the top half of the glans is covered by foreskin with a downward tilt.
4. Penile size
5. Undescended testis, cleft scrotum in proximal hypospadias
6. Inguinal hernia

Figure 59. Different types of hypospadias: Glandular, anterior penile, and penoscrotal (courtesy of Dr M Dawaba)

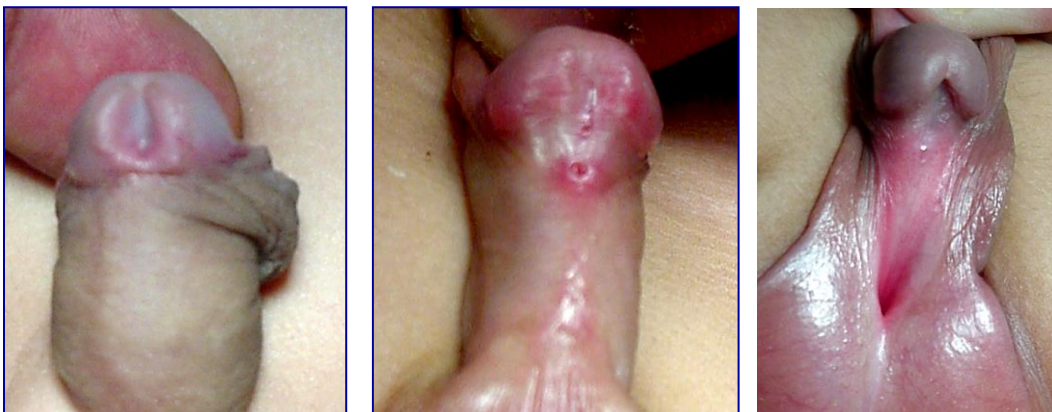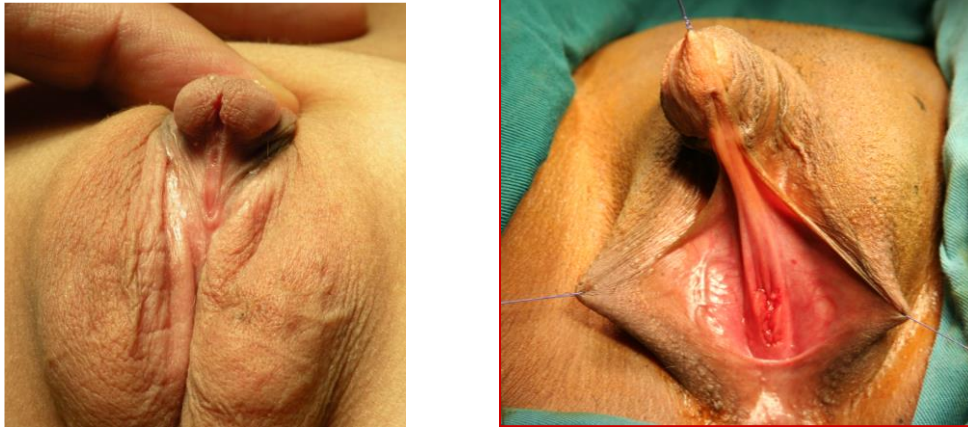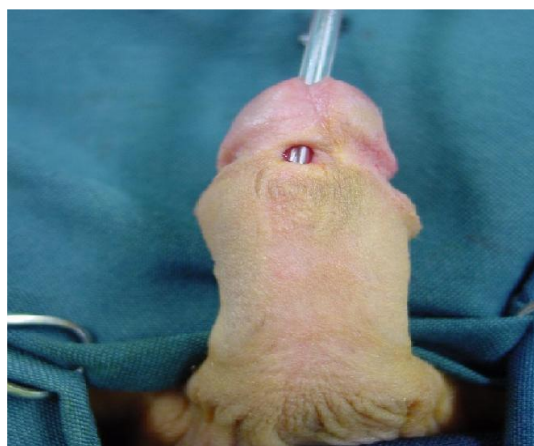


Figure 60. Hypospadias with chordee: Proximal penile and perineal (courtesy of Dr M Dawaba)



URETHRO-CUTANEOUS FISTULA may develop as a complication of surgery e.g. repairs of hypospadias. An example of post-circumcision urethro-cutaneous fistula is seen in figure 61.

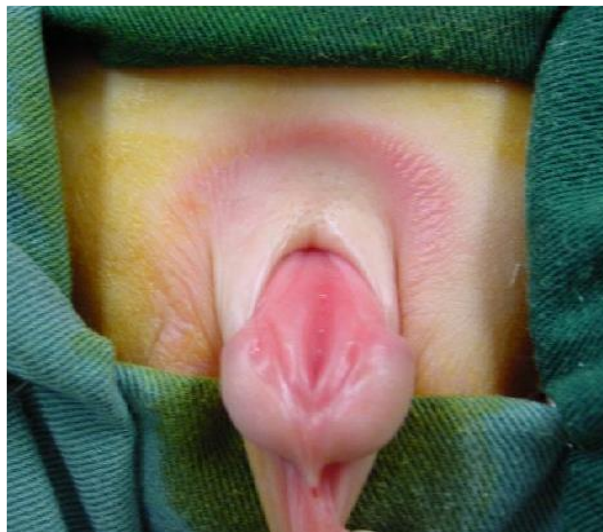Figure 61. Post-circumcision urethrocutaneous fistula (courtesy of Dr A.T.Hafez)



EPISPADIAS (figure 62):

The urethral opening is above the corpora cavernosa on the dorsal surface of the penis. When penopubic or associated with ectopia vesicae, urinary incontinence occurs.

Figure 62. Male penopubic epispadias (courtesy of Dr A.T.Hafez)

**EXSTROPHY (figures 63 and 64):**

Bladder exstrophy is a defect of the bladder and urethra, in which the structures are turned inside out. The anterior abdominal wall that normally covers the bladder also does not form properly and is separated, thus exposing the inside of the bladder to outside. The abnormalities associated with bladder exstrophy include: Epispadias, dorsal penile chordee, absence of the sphincters, small bladder capacity, separation (diastasis) of the pubic bones, and a low positioned umbilicus.

Figure 63. Classic bladder exstrophy in newly-borne girl and boy (courtesy of Dr A.T. Hafez)

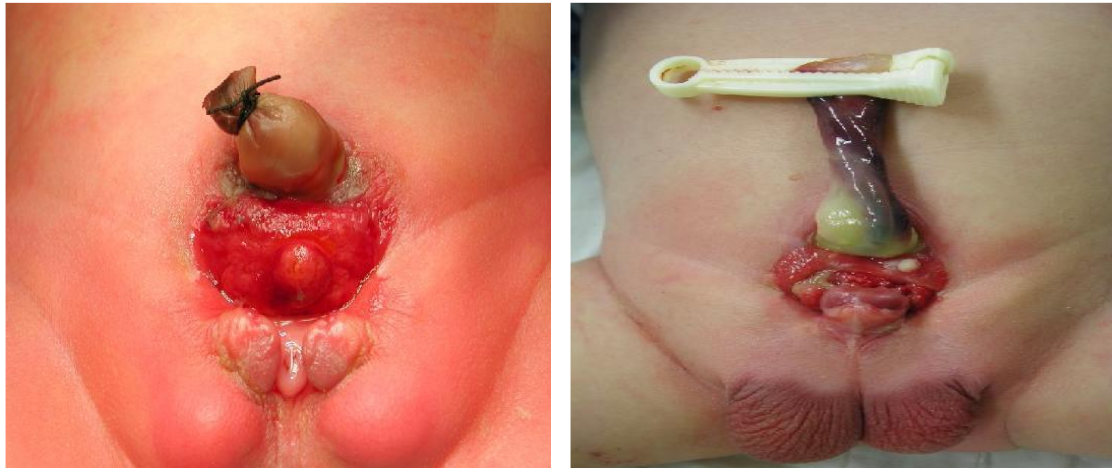
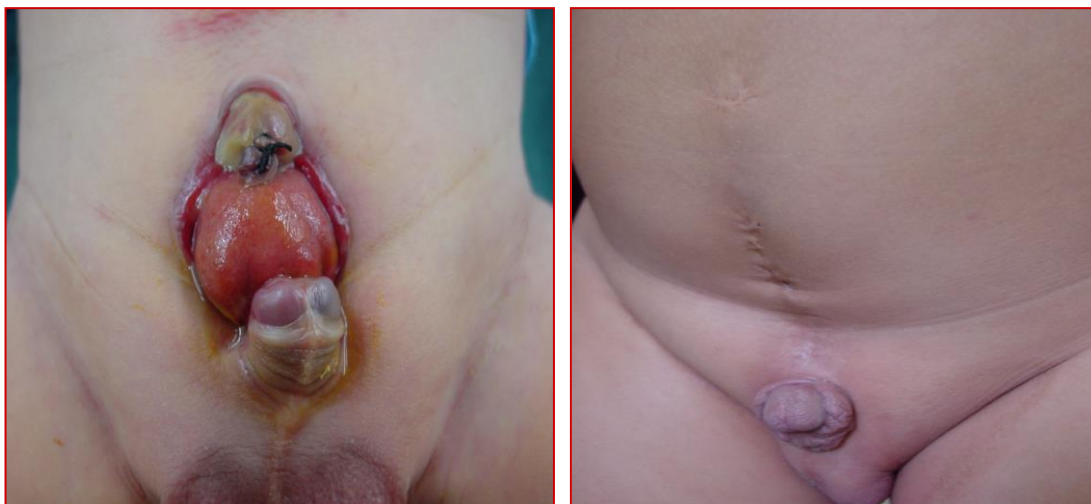
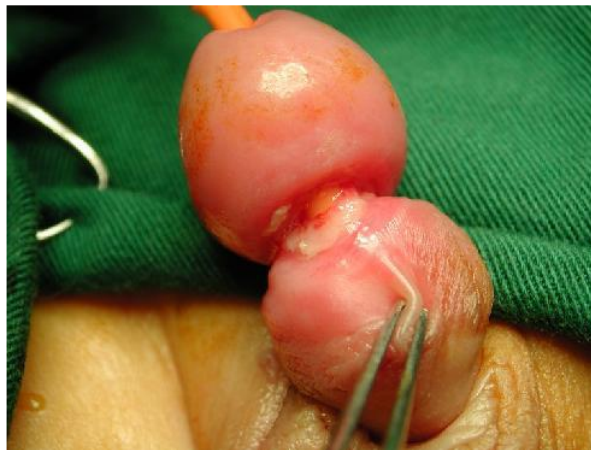
Figure 64. Classic bladder exstrophy in a newly-borne boy and at followup after repair (courtesy of Dr M Dawaba)



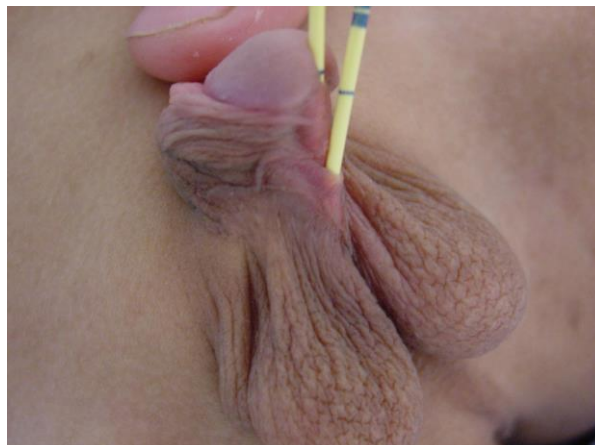Hair-thread tourniquet syndrome (figure 65) is a rare condition that occurs when a strand of hair or a piece of thread encircles the penis, causing partial or total obstruction to circulation. Early diagnosis of this condition is important to avoid progressive penile strangulation. Several complications are reported including urethra-cutaneous fistula, complete urethral transection, penile gangrene, and penile amputation.

Figure 65. Penile strangulation caused by a hair tie with urethral transaction and partial amputation of the glans penis (courtesy of Dr A.T.Hafez)



Urethral duplication (figure 66) is a rare congenital anomaly with variable clinical presentations because of the different urethral anatomical patterns of this abnormality. Usually the ventral urethra is the most functional. Associated anomalies include epispadias and hypospadias.

Figure 66. Duplicated urethra (courtesy of Dr T. Helmy)



FIXED DRUG ERUPTION:

- Cutaneous eruption that can be reproduced at the same site by the same drugs.
- Causes: Sulphonamides, Allopurinol, Salicylates, Tetracyclines, Phenacetin, Hypnotics, Phenolphthalin.
- Genital lesions are usually solitary, well-defined in the glans penis and shaft. They may be bullous and subsequently ulcerate. Repeat exposure may lead to hyperpigmentation of the same site.

PRIAPISM (table 20):

Low-flow or ischemic priapism: The commonest form

- **Persistent or prolonged (>4hours), painful, purposeless** (in the absence of sexual stimulation) **penile erection**.
- The commonest cause is iatrogenic.
- Cavernosal blood gas analysis shows hypoxia and acidosis due to ischemia of corpus cavernosa and veno-occlusive mechanism ($pO_2 < 30$, $pCO_2 > 60$, $pH < 7.25$).
- There is a rigid mildly tender penis while the glans and corpus spongiosum are flaccid.

High-flow (non-ischemic) priapism:

- Prolonged, painless penile erection due to upregulated arterial blood flow secondary to post-traumatic AVF.
- Cavernosal blood gas analysis is similar to arterial blood.
- The penis is semi-rigid.

Table 20. Types of Priapism

	Low-flow priapism	High-flow priapism
Etiology	Primary: idiopathic Secondary - Intracavernosal injections. - Drugs - Thrombo-embolic: Sick cell disease, leukemia, thalassemia. - Neurogenic - Infection - Malignancy: bladder, prostate	-Non ischemic -Penile or perineal trauma → AVF → ↑ arterial flow.
Features	Painful fully rigid erection Cavernosal rigidity	Painless Semi-rigid penis.
Cavernosal blood gases	Hypoxia, acidosis	Arterial pattern
Doppler US	Reduced or no blood flow	Ruptured artery and pooling of blood around.
Treatment	- Cavernosal aspiration (dark blood) and irrigation. - Intracavernosal injection of α -adrenergic agonist (Phenylephrine). - Sicklers: alkalinization, hydration, oxygenation, analgesia and hematologist referral. - Corporal shunts: distal (Al-Ghorab) or proximal	- Early: cool bath. - Selective embolization of the internal pudendal artery.

URETHRAL DISEASES: Urethral palpation for tenderness, indurations, stone, stricture, foreign body:

Gonorrhea:

Urethral discharge: Profuse, purulent

Reiter's syndrome: Classic triad:

Urethral discharge: Purulent

Arthritis: Peripheral joints

Conjunctivitis: Red eye

Urethral trauma (table 21):**Table 21. Features of urethral injuries**

Features	Rupture Posterior Urethra	Anterior Urethra
Mechanism	Pelvic fracture	Falling astride
Blood at external urethral meatus	Minimal but evident on underclothes	Profuse
Bleeding	-Perineum shows no signs of bleeding hematoma and bruising -Excessive pelvic hematoma above the pelvic diaphragm may lead to shock	Excessive perineal hematoma
DRE	-High- riding prostate or a boggy mass -Blood if there is rectal injury	Free
Associated injuries	Head, thorax, abdomen, long bones	
Management	- Diagnosis: Retrograde urethrogram - Discourage urethral catheterization - Diversion of urine by suprapubic catheter	

Stricture: Usually not felt.

Urethral carcinoma:

- Blood discharge.
- Localized indurations or masses.
- Retained urethra after cystectomy.
- Palpable inguinal lymph nodes (20%).

Urethral Diverticulum:

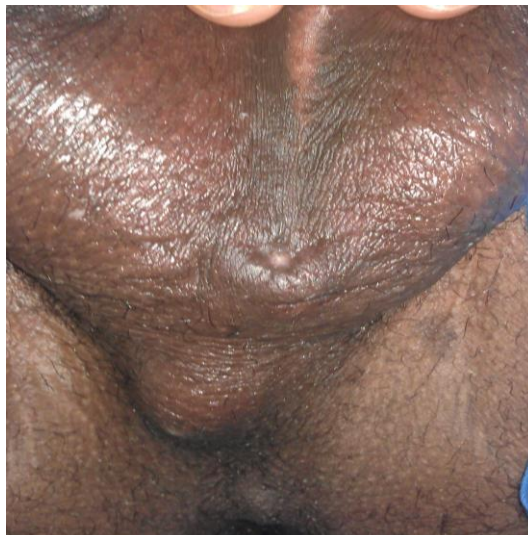
- May follow hypospadias repair.
- Pouch on the under-surface of penis.
- Apparent more during urination.
- Soft swelling.
- Pressure: Urine or turbid fluid expressed through the meatus.

EXAMINATION OF THE PERINEUM:

The perineum is the area between the anus and the scrotum and the base of the thighs. The scrotum should be elevated for proper evaluation:

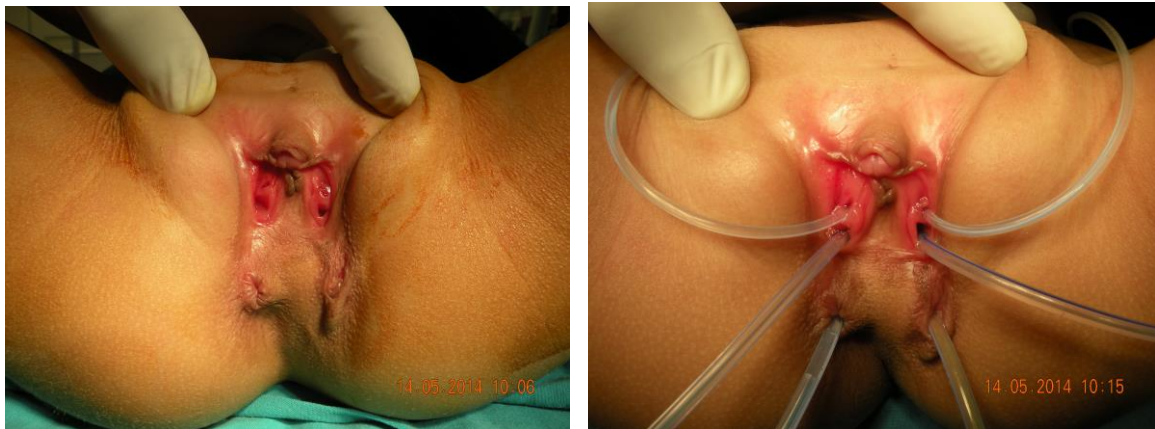- a. Hematoma in ruptured urethra.
- b. Periarethral abscess (figure 67) mostly results from spontaneous rupture of the urethra as a complication of a neglected urethral stricture. A purulent collection in the perineum will be detected as a red, warm, tender, and fluctuant mass.
- c. Abscess of the bulbo-urethral (Cowper's) gland is better evaluated by DRE with bi-digital examination.
- d. Watering-can perineum and scrotum in neglected urethral stricture and schistosomiasis.
- e. **Peri-anal sensation:** Peri-anal sensory loss is seen in cases of neurogenic bladder, cauda equina syndrome (decreased perianal sensation, decreased anal tone, inability to actively contract the anus, urinary retention and overflow incontinence), and spinal tumors. Acute central disc herniation causes anesthesia of the saddle area.

Figure 67. Urethro-cutaneous fistula and perineal peri-urethral abscess complicating a recurrent urethral stricture



COMPLETE CLOACAL DUPLICATION (figure 68) in females is a very rare anomaly characterized by duplication of genitourinary and hindgut structures.

Figure 68. Complete cloacal duplication of urethra, vagina and anus
(courtesy of Dr T. Helmy)



Chapter 20: DIGITAL RECTAL EXAMINATION

- Digital rectal examination (DRE) is an essential part of physical assessment of a male patient.
- It can be an extremely painful or painless according to the skill and patience of the examiner.
- Ensure privacy of the examination.
- Explanation and permission are essential.
- Remember: If you don't put your finger in it, you may put your foot in it!
- Emptying the bladder before DRE is helpful.
- The possible limit of DRE is 10 cm.
- Equipment: Chaperone, non-sterile gloves, tissues and lubricating jelly.
- The patient is handed some tissue paper for later use at the end.
- In women, it helps to assess the recto-vaginal wall, and for rectal cancer.
- The steps of DRE in men are shown in figure 69.

1- POSITIONING THE PATIENT:

a. Dorsal position:

Patient is semi-recumbent with flexed knees, and legs apart. This position is comfortable to patient and urologist. Bimanual examination is done easily.

b. Lithotomy position:

This position is helpful to perform bimanual examination under anesthesia when cystoscopic assessment and biopsy are performed.

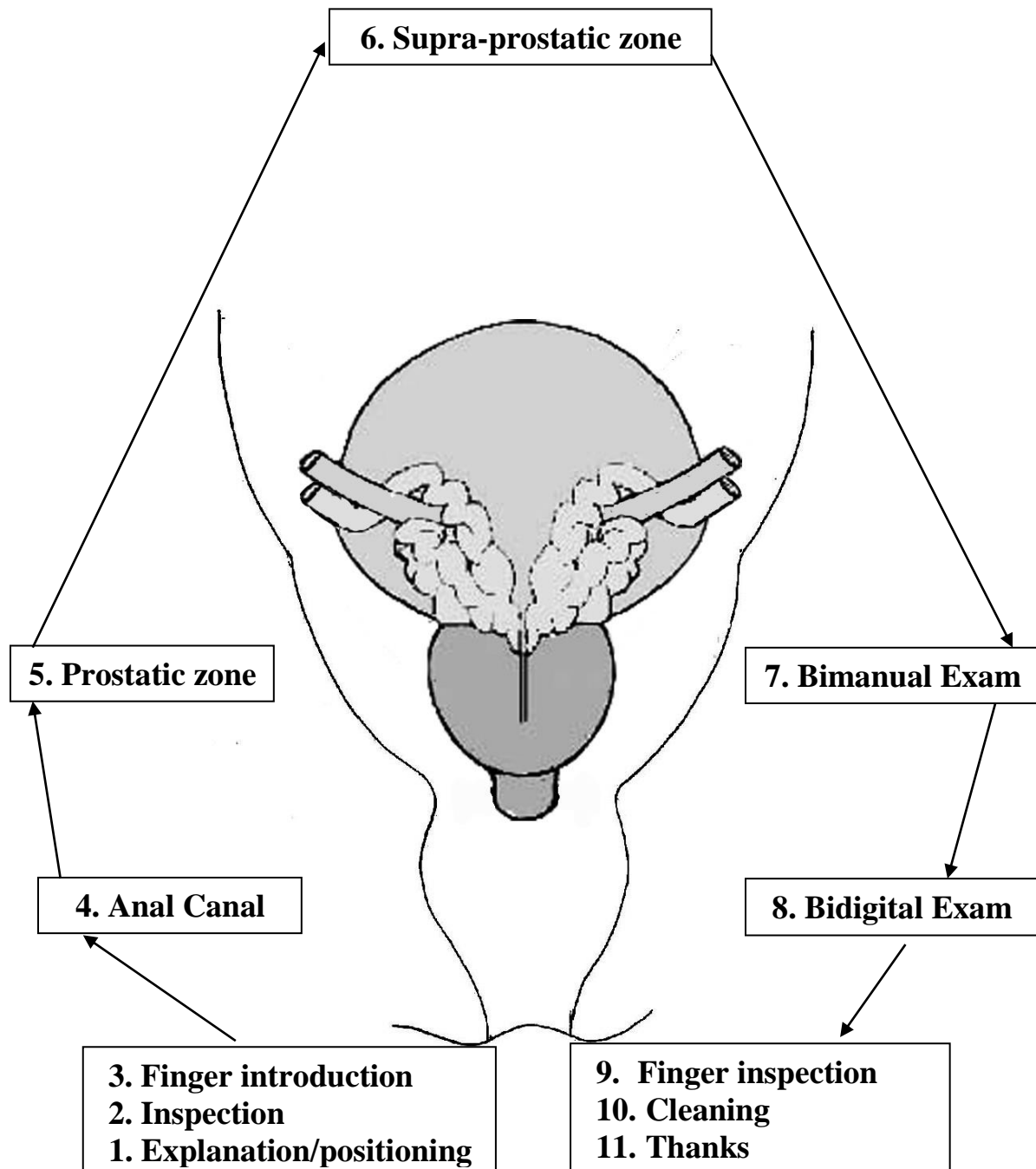
c. Knee- elbow position:

Prostate is decongested and consistency changes are easier to palpate.

d. Left lateral (Sims's) position:

The left leg is lower and semi-extended while the right one is upper and flexed. The buttocks project over the edge of the table and the trunk should be across the couch.

Figure 69. Steps of Digital Rectal Examination in Men



2- INSPECTION OF THE ANAL VERGE:

Adult perianal skin is normally more pigmented and coarser than the skin over the buttocks. Inspect the area for the following:

- **Closure of the anal verge**
- **Corrugations**
- **Anal reflex:** Contraction of the external anal sphincter in response to painful stimuli nearby e.g. pin scratch. It checks S2-4.
- **Local pathology:**

Piles:

- Hemorrhoids appear as a prolapsed blue or purple mass at anus.
- Straining with relaxation of the external sphincter may show internal piles.
- External piles are covered with skin.

Rectal prolapse

Anal fissure: Superficial tear in the anoderm with a sentinel tag

Anal fistula: An opening is seen and felt as a small elevation, purulent discharge, erythema, ulcer, fluctuant mass.

Abscesses, fecal soiling, blood, mucus.

Imperforate anus in neonates is associated with recto-urethral fistula in boys.

3- FINGER INTRODUCTION:

- Explain what you are about to do and ask permission: I will examine the back passage without hurting you. Ask the patient to open his mouth and breathe quietly in and out during the procedure.
- Generous lubrication of the gloved index finger. It might feel cold.
- Use the little finger in children.
- Put the pulp of the finger on the anal verge and rotate with gentle pressure until the sphincter is felt to relax. Most sphincters reflexly tighten when

touched but quickly relax with continued pressure. If the patient experiences severe pain on pressure consider: anal fissure, abscess, ulcer, thrombosed piles or prostatitis. You may need a local anesthetic cream to proceed.

- Introduce the finger slowly, gently and stepwise: the first phalanx examines the anal canal, the second to palpate the prostate and the third to assess the supra-prostatic zone. This might feel a little uncomfortable.

4- THE ANAL CANAL:

a) The canal walls:

- The anal canal, in adults is 2-3 cm, in length.
- Felt as a groove between the external and internal sphincter.
- Anal fissure: Tear; spasm of the sphincter and severe pain; DRE may be extremely difficult to the patient.
- Internal piles can be felt as a soft mass when thrombosed or engorged.

b) Sphincter integrity:

- Absence of normal resistance to finger introduction and laxity or diminished anal tone indicate:
 - Neuropathic damage
 - Local iatrogenic injury of the sphincter
 - Senility.
- Assess the anal tone by asking the patient to clench your finger.
- Ability of the patient to squeeze your finger with the anal sphincter indicates spinal cord integrity.
- Spasm of the sphincter is seen in neuropathic damage.

- c) Bulbocavernsious reflex (BCR)** is an autonomic reflex that involves monitoring anal sphincter contraction in response to squeezing the glans penis in men or clitoris in women or by gentle tugging or pulling on an indwelling Foley catheter. The normal response includes contraction of the anal sphincter, bulbocavernosus and ischiocavernosus muscles. Positive BCR is called also the penile reflex and monitors the integrity of afferent, the sacral spinal cord (S2-4), and efferent nerves.

d) The anal summit:

The anal canal commences where the rectum passes through the pelvic diaphragm and ends at the anal verge.

The junction between the rectum and anus is felt as a thickened ridge or ring. The posterior and lateral parts of the ring are felt easily because of the puborectalis.

Following examination of the anal canal the finger is introduced to palpate the rectum observing the following anatomical areas:

- a) Anterior wall (prostate, seminal vesicles, and urinary bladder).
- b) Right lateral wall.
- c) Left lateral wall.
- d) Posterior wall (hollow of sacrum, coccyx).

Examine all 360° by moving the finger in sweeping motions. Note irregularities in rectal wall, presence of palpable feces and any points of tenderness. Possible rectal conditions to palpate include polyps, stricture, malignancy and anorectal abscess.

5- THE PROSTATIC ZONE:

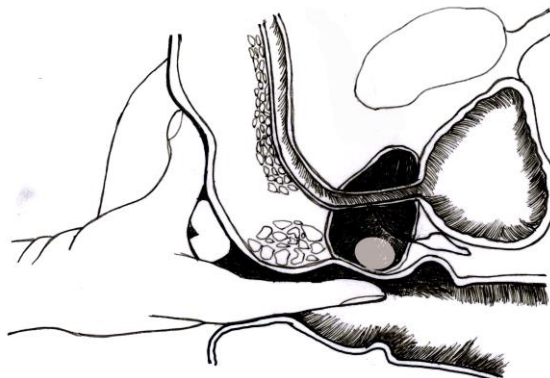
DRE is the cornerstone in physical assessment of prostatic problems.

Next, in the male identify the prostate gland (figure 70).

- As a whole for shape, size, outline, consistency, symmetry and sulci.
- Each lobe for shape, surface and sensation.
- The para-prostatic gutters.

There is no evidence that DRE will cause a rise of serum PSA.

Figure 70. Digital rectal examination of the prostatic zone



The Normal Prostate:

- The posterior aspect of the prostate is felt as a chestnut in size (20g) and shape (figure 71). DRE provides a rough indication of the prostate size.

Figure 71. The chestnut (أبو فروة)



- Size is assessed by estimating transverse and longitudinal dimensions, as well as the degree of posterior protrusion into the rectum.
- Like an inverted pyramid, the widest base is superior at bladder neck (transverse diameter 4 cm) while blunt apex is the lowest part. The vertical length is 3 cm and the posterior bulge is about 2 cm. The upper border is felt as a transverse groove.
- The gland is divided between posterior urethra (median furrow or sulcus) and two lateral sulci into two equal triangles.
- The two lateral sulci (the antero-lateral angles of the rectum with the prostate) are normally obtuse.
- The rectal mucosa is sliding over the prostate.
- Consistency is symmetrical and **rubbery** (like the thenar eminence when the thumb is opposed to fifth finger).
- Prostate is **soft solid or mushy** if congested due to lack of intercourse or in chronic infection with impaired drainage.

BPH:

- A disease of old age characterized by regular ballooning of the two lateral lobes of the prostate.
- Edges are rounded.
- Sulci are obviously acute deep or exaggerated.
- The rectal mucosa is moving over the enlarged prostate.
- As the prostate enlarges, the anterior rectal wall is pushed backwards. The degree of rectal bulging of the prostate is proportional to the increase in size: mild BPH 1-2 cm, moderate 2-3, huge >3 cm.
- The prostate retains its normal limited mobility.
- Consistency is **firm elastic** and homogenous.
- The findings are consistent with a regular generalized enlargement with preservation of shape and exaggeration of sulci.

Prostate Cancer:


Most of prostate cancers begin in the posterior lobe (peripheral zone) and are very accessible during DRE (figure 70). It may occur primarily or on top of a pre-existing BPH.

DRE findings depend on tumor stage as shown in figure 72. Prostate cancer often starts as a nodule and progresses to asymmetry of one lobe and eventually involvement of adjacent structures. Prostate cancer arises as a peripheral **hard** nodule, and the gland feels irregular and asymmetrical (T₂). Differential diagnosis of a hard prostatic nodule is shown in figure 73.


Sulci may be obliterated and tumor extends through the capsule into seminal vesicles (T₃). T₄ tumors are fixed to pelvic wall or invading adjacent structures.

Histopathologic evaluation of surgical specimens after radical prostatectomy for clinically organ-confined prostate cancer demonstrates a significant degree of understaging by DRE.


Figure 72. DRE in patients with prostate cancer




← **T1 tumor is not palpable. The prostate is normal or shows BPH.**



T2a invades $\frac{1}{2}$ or less of one lobe.


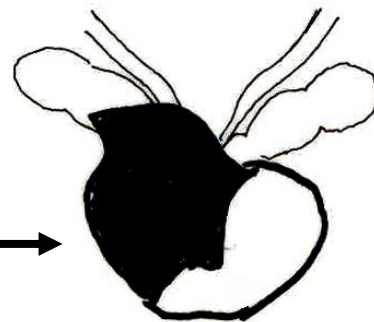


T2b invades more than $\frac{1}{2}$ of one lobe.



T2c involves both lobes.

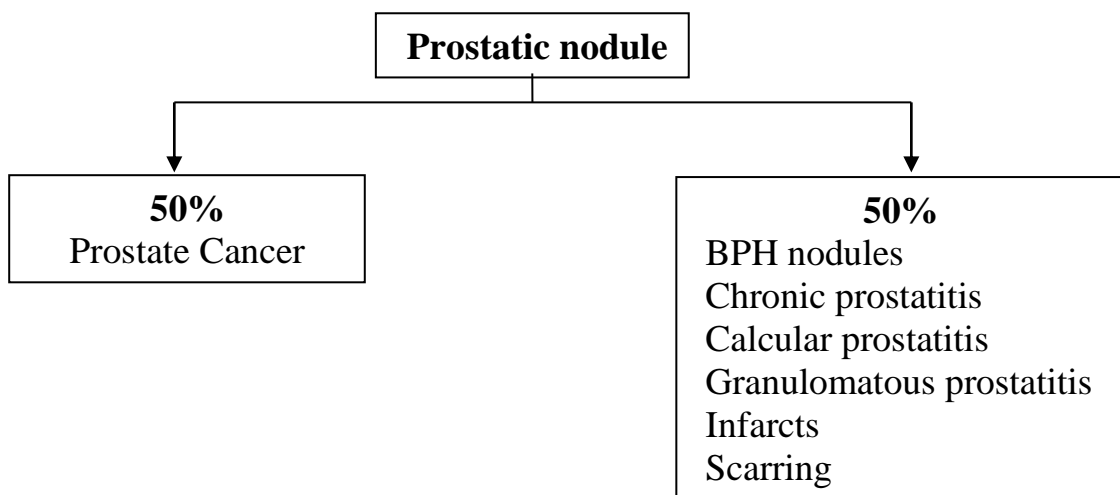
T3 tumor extends through prostatic capsule and seminal vesicle.



← **T4 prostate cancer is fixed to the pelvic wall.**

Table 22. Features of prostate by DRE in health and disease

Feature	Normal prostate	BPH	Prostate cancer
Site	The prostate is palpable pelvic organ in front of the lower rectum		
Shape	Inverted pyramid	Generalized enlargement with preservation of the shape	It depends on tumor stage, Enlargement is irregular.
Size	Chestnut	Mild, moderate or marked	Variable
Sulci	One median / and two lateral	Exaggerated / or deep	Obliterated
Rectal mucosa	Sliding	Sliding	Moving except late
Consistency	Rubbery, and homogenous	Firm elastic, homogenous	Rocky hard, heterogeneous
Mobility	Little, variable	Little	T ₄ is fixed

Figure 73. Differential diagnosis of prostatic nodule**Acute Prostatitis:**

- Dysuria, perineal pain, urine retention, urethral discharge, fever/chills, tenesmus.
- DRE must be very gentle.
- The prostate is enlarged, tense, tender and hot.
- Abscess is felt as an area of softening, boggiess or fluctuation.

Chronic Prostatitis:

- Size: normal or slightly enlarged.
- Tenderness: Absent or slight.
- May be indurated, show some nodules, or boggy spots.

Tuberculous Prostatitis:

- The prostate is hard, irregular and nodular.
- Seminal vesicles are involved similarly.
- Vas deferens is thickened and beaded.

Prostatic Calculi

- Irregular hard prostate when the stones are peripheral.
- Free stones are felt as "beads in a bag" giving the crackling sensation.

Rupture Posterior Urethra

- In cases of fracture pelvis and rupture posterior urethra, the prostate is high-riding with a soft boggy mass in its place.
- Blood in the rectum indicates concomitant rectal injury.

6. THE SUPRA-PROSTATIC ZONE:

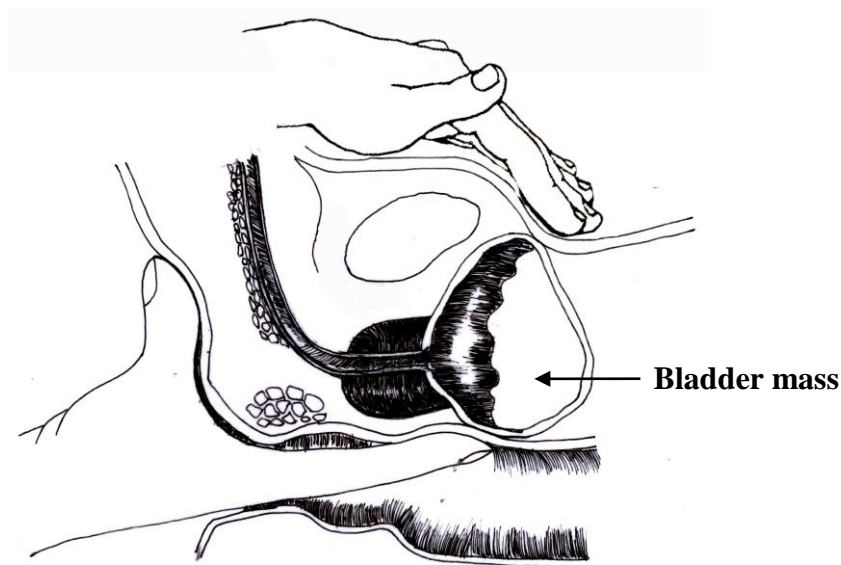
- This area is evaluated by full finger introduction during DRE and completed by bimanual examination (figure 74).
- When the patient is obese or the prostate is markedly enlarged, palpation will be difficult.
- Palpation will assess:
 - The urinary bladder
 - The seminal vesicles
 - Recto-vesical pouch

The urinary bladder:

- The normal bladder and seminal vesicles are not palpable.
- The supra-prostatic zone is felt as an empty area unless the bladder is full.

Carcinoma of the bladder is the most common cause of a palpable mass felt from the posterior wall by DRE and from the anterior wall and dome during bimanual examination.

Figure 74. Bimanual palpation of a bladder mass in the male



The seminal vesicles:

- They are enlarged and palpable as a result of chronic inflammation and obstruction.
- They show a characteristic craggy sensation in tuberculosis.

7. BIMANUAL EXAMINATION (figures 74 and 75):

- Bimanual examination is performed with a finger in the rectum and the other hand on the lower abdomen, and is best carried out under anesthesia.
- It is important to evaluate whether a bladder mass is present or not. Mobility/fixation of the mass is the most important information gained.
- Ta tumors are not felt. T1 is generally not palpable, but T1 is occasionally felt as a mouse mobile within the bladder. T2 and T3 are felt as a

3-dimensional mass mobile with the bladder. T4 tumor indicates involvement of the adjacent organs or a fixed mass.

- Ask the patient to bear down (Valsalva's maneuver) to check the farthestmost rectal mucosa for masses.

The internationally agreed system for staging of urologic tumors is the TNM classification. Staging may be either radiological OR pathological.

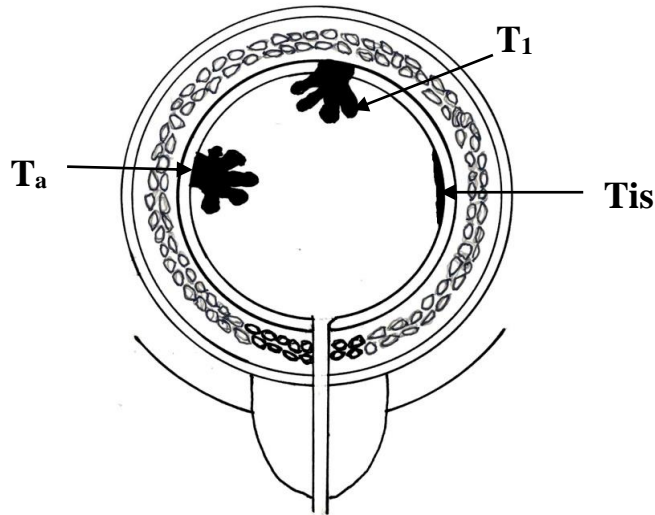
Radiological staging is a preoperative tool for planning for surgery and neoadjuvant treatment.

Pathological staging is performed on surgical specimens and used to plan adjuvant treatment and is important to inform about prognosis.

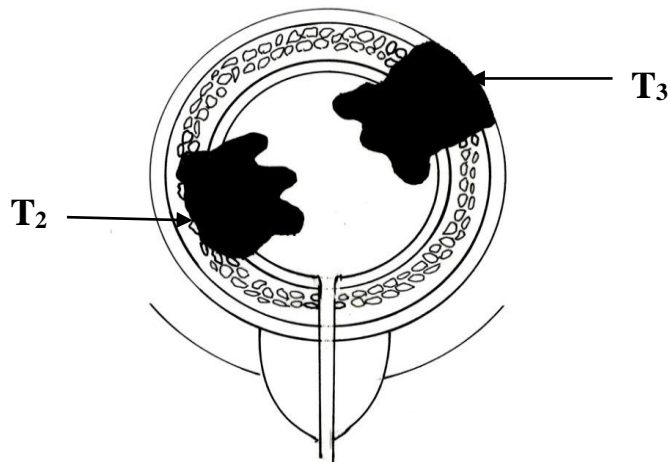
Clinical staging is generally **not accurate** because of the possible under- or over-estimation of the extent of the disease. Under-estimation of a bladder mass is seen when the tumor is small or found in an inaccessible area such as the bladder dome. In contrast, over-estimation of the mass is encountered when there is peri-vesical fibrosis or inflammatory reaction.

Figure 75. Bimanual examination in patients with bladder cancer

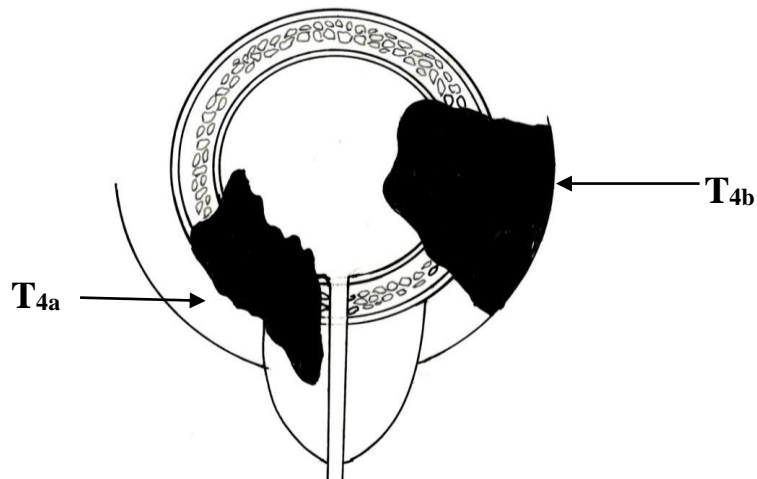
A- Non-muscle invasive bladder tumors (T_a , T_1 , T_{is}) are not palpable.



B- Bladder tumor invading the muscle (T_2) or perivesical fat (T_3) may be felt as a 3-dimensional mass, induration or thickening.



C- Bladder tumor invading the prostate (T_{4a}) or a mass fixed to the pelvic wall (T_{4b}).



8. BIDIGITAL EXAMINATION (figure 76):

Cowperitis: inflammation of the Cowper's gland.

The index finger is in the rectum and the thumb of the same hand on the perineum.

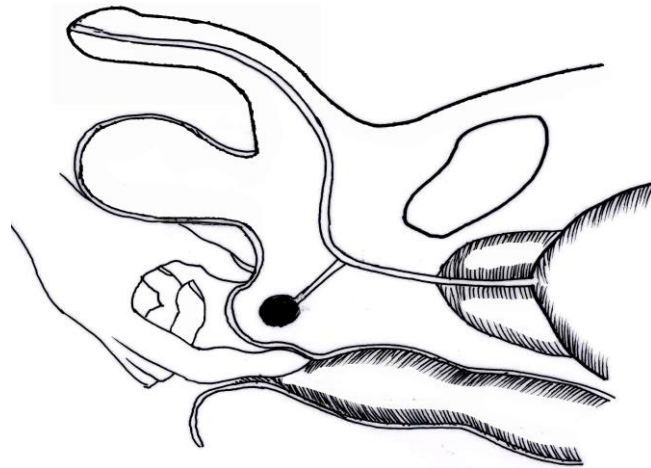
The tissues in between can be palpated.

Acute infection: Severe pain.

Chronic infection: The gland is enlarged and hard.

Bidigital anorectal palpation detects indurations around an anal fistula which feel like a whip-cord.

Figure 76. Bidigital examination to assess Cowper's gland

**9. WITHDRAWN FINGER INSPECTION:**

When DRE is completed, look at your finger for blood, mucus, or pus according to the local anorectal pathology. Appearance and consistency of feces are noticed. Fecal occult blood test may be performed. In fracture pelvis, with posterior urethral rupture, rectal injury may coexist.

10. CLEANING:

At the end of anorectal examination, wipe the lubricant or any feces with tissues or ask the patient to do so. Adequate tissues, soap, and towels should be available for the patient to cleanse himself after the examination. Otherwise, he will be extremely uncomfortable when dressed.

11. THANK THE PATIENT AND ASK HIM TO RE-DRESS.

You may need to help.

CHAPTER 21: VAGINAL EXAMINATION

Male urologists should perform vaginal examination in the presence of a female nurse or chaperone while the patient is in the supine position, with head and shoulders elevated arms at sides or across the chest to have eye contact with the patient and reduce tightening of abdominal muscles.

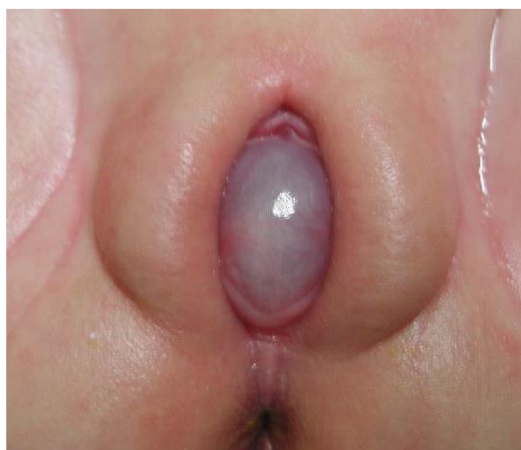Each step of the examination should be explained to the patient. Drape the patient abdomen to the knees. Emptying the bladder before examination is helpful.

Perineum, labia, cervix, uterus, and adnexa are examined for masses, tenderness, ulceration, and discharge.

INSPECTION: Visual examination includes:

- **Mons pubis:** Observe the pubic hair to assess sexual development.
- **Labia majora and minora** are inspected for:
 - Herpes simplex ulcers (shallow, small, painful ulcers on red bases),
 - Syphilitic chancre (firm, painless ulcer), and
 - Inflammation of Bartholin cyst.
- **The clitoris** is hypertrophied in cases of masculinization.
- **Vaginal introitus** may show imperforate hymen in girls presenting with difficult urination or acute urinary retention (figure 77).

Figure 77. Imperforate hymen



- **The vagina:**

Does the vagina look normal?

Is there a vaginal prolapse?

Are there scars of previous surgery, sinuses or other lesions?

Possible causes of dysuria:

- Atrophic changes: The well estrogenized vagina has thick, pink epithelium with transverse rugae. The poorly estrogenized vagina has a pale, thin epithelium with loss of rugae.
- Erosions
- Ulcers
- Discharge
- Warts

- **The urethral meatus**

Size and location

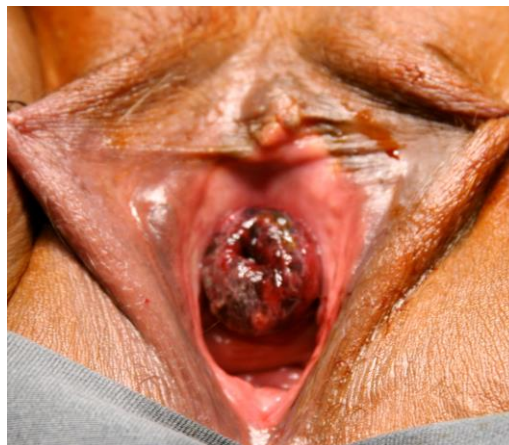
Caruncle is a benign, erythematous, tender lesion arising from it.

Urethral prolapse (figure 78)

Cysts

Urethral tumor develops bloody spots.

Figure 78. Prolapsed thrombosed female urethra
(courtesy of Dr A El-Hefnawy)



- **The Perineum**

- **The Pelvic Muscles:** When the pelvic floor is weak, various pelvic structures may become displaced and are seen better when the patient strains down (Valsalva maneuver).

Cystocele is prolapse of the bladder wall which is seen or felt as a bulge of the anterior wall of the upper vagina.

Cysto-urethrocele involves both the bladder and the urethra as they bulge into the anterior vaginal wall throughout its extent.

Rectocele is a bulge of the posterior vaginal wall, together with a portion of the rectum.

Prolapsed uterus is descended down the vaginal canal and classified into three degrees of severity:

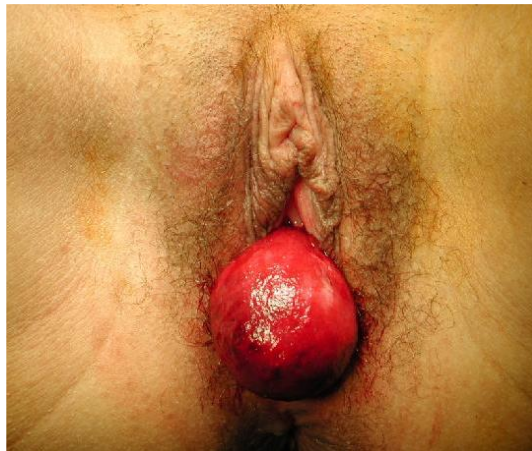First-degree: still within the vagina

Second -degree: with the cervix at the introitus

Third-degree: with the cervix outside the introitus

- **Ureterocele** may occasionally prolapse through the female urethra into the vagina (figure 79).

Figure 79. Prolapsed ureterocele in an adult lady



Bladder stress test: Vaginal examination is performed with the urinary bladder comfortably full, in the lithotomy position, to check for incontinence and prolapse. The patient relaxes, and then coughs vigorously in an attempt to reproduce stress urinary incontinence.

PALPATION IN WOMEN:

Internal examination includes:

- **Cervix and fornices:** Pain (pelvic inflammatory disease), masses
- **Uterus:** Myomas
- **Right and left adnexa:** Ovarian cysts, masses. salpingitis
- **Vaginal walls and pelvic muscles:** Ask patient to tighten muscles around your fingers and ask her to strain down to assess for cystocele, cystourethrocele and rectocele.
- **The urinary bladder** is better evaluated during bimanual examination.
- **The urethra** is examined for indurations (a sign of chronic inflammation or malignancy) or the presence of a urethral diverticulum. Milking of the urethra is performed when urethritis is suspected to express discharge.

Urethral diverticulum:

It is a localized outpouching of the urethra, into the anterior vaginal wall, that gets filled with urine as it is connected to the urethra. Symptoms are variable and include irritative LUTS, dyspareunia, recurrent UTIs and post-void dribbling. It may be asymptomatic and discovered incidentally. Complications may develop e.g. stone formation and urethral carcinoma. On examination, the patients have a tender, soft, spherical anterior vaginal wall mass, which upon gentle compression may express retained urine or purulent discharge through the urethra. Firmness or hardness may reflect the presence of a stone or tumor within the diverticulum.

The differential diagnosis of an anterior vaginal wall mass includes urethral diverticulum, Skene gland abscess, ectopic ureterocele, Gartner duct cyst, müllerian remnant cyst, and vaginal inclusion cyst.

BIMANUAL EXAMINATION:

- With 2 fingers in the vagina and the other hand on the lower abdomen, the bladder, cervix, uterus and adnexae are palpated.
- Is the cervix present and normal?
- Is the vagina of normal caliber and sensation?
- Is there tenderness in the vaginal fornices?
- Any abnormality anterior to the cervix denotes an affection of the bladder or pelvic connective tissue, while posterior abnormalities are in the Douglas pouch.
- Important findings in the genital tract may be palpated:
 - Fibroids (myomas of the uterus) are very common benign tumors that feel firm and often irregular, and may be multiple.
 - Carcinoma of the cervix is felt as an irregular hard mass.
 - Ovarian cyst
 - Carcinoma of the uterus

Bladder tumors:

The normal bladder is not palpable unless it is full. Carcinoma of the bladder is the most common cause of a palpable mass. Mobility/fixation of the mass and possible vaginal infiltration are the most important information gained.

Vesicovaginal fistula:

The most common type of fistula is vesicovaginal and approximately 10% are uretrovaginal following gynecologic surgery. Vesico-uterine fistula is rare. The size and location of fistula as well as the quality of tissue around are evaluated better by speculum examination in the Sims's position.

BIDIGITAL EXAMINATION (Bartholin's glands):

While your index finger in the vaginal introitus near the posterior end, put your thumb outside the posterior part of the labium majus.

The Bartholin's gland may become swollen due to infection.

CHAPTER 22: UROLOGICAL DIAGNOSIS AND MANAGEMENT

The workup for diagnosis of urological disorders is based on several complementary steps. The interpretation of clinical data provides the plan for further evaluation.

- 1) History taking
- 2) Physical examination
- 3) Correlation of both history taking and physical examination to have a preliminary or a possible provisional conclusion.
- 4) A differential diagnosis is entertained through the implementation of significant positive and negative findings.
- 5) Further management is based on the necessary investigations (laboratory, microbiological, hematological, biochemical, radiological, pathological, endoscopic, and urodynamic studies).
- 6) The potentially reversible risk factors for the disease should be excluded. Also, evaluation and control of risk factors for future complications is mandatory.
- 7) Symptomatic measures
- 8) Definitive treatment
- 9) Follow-up

UROLOGY CASE INVESTIGATIONS

Urine studies: Urinalysis, microscopy, osmolality, 24-hour sample for creatinine, calcium, phosphorus, oxalate, uric acid and citrate.

Microbiology: Urine culture / sensitivity, wound culture, acid fast bacilli (AFB), blood culture, sputum culture, viral screens.

Hematology: CBC, PT, APTT, fibrinogen, blood group.

Biochemistry: Serum creatinine, BUN, sodium, potassium, bicarbonate, calcium, phosphates, magnesium, uric acid, diabetes profile, liver function tests.

Markers: PSA, AFP, beta HCG, catecholamines.

Radiology: Ultrasonography, KUB, chest XR, ascending and voiding cystourethrography, CT scan, MRI, nuclear scan, angiography.

Pathology: Review sections, biopsy, cytology.

Endoscopy

Urodynamic studies

ALLAH's wisdom transcends all human calculation.

الاسلام دين العلم

١- اقرأ هي المادة الاولى من دستور الاسلام امرت بالقراءة مرتين وذكرت مادة العلم ثلاث مرات:

اقْرَأْ بِاسْمِ رَبِّكَ الَّذِي خَلَقَ ﴿١﴾ خَلَقَ الْإِنْسَانَ مِنْ عَلَقٍ ﴿٢﴾ اقْرَأْ وَرَبُّكَ الْأَكْرَمُ ﴿٣﴾
الَّذِي عَلَّمَ بِالْقَلَمِ ﴿٤﴾ عَلَّمَ الْإِنْسَانَ مَا لَمْ يَعْلَمْ ﴿٥﴾
العلق الايات من ١-٥

٢- أول قسم أقسم به الله سبحانه وتعالى في القرآن كان بالقلم:
ن وَالْقَلَمِ وَمَا يَسْطُرُونَ ﴿١﴾
القلم الايه ١

٣- أمر الله سبحانه الرسول محمد عليه الصلاة والسلام أن يلجأ اليه متضرعاً راجياً أن يزيده الله علماً:
فَتَعَالَى اللَّهُ الْمَلِكُ الْحَقُّ وَلَا تَعْجَلْ بِالْقُرْآنِ مِنْ قَبْلِ أَنْ يُقْضَى إِلَيْكَ وَحْيُهُ وَقُلْ رَبِّ زِدْنِي
عِلْمًا ﴿١١٤﴾
طه الايه ١١٤

٤- يأتي العلم تالياً للايمان مباشرة ويقول الله عن الذين تعلموا مشجعاً ومكافئاً:
يَا أَيُّهَا الَّذِينَ آمَنُوا إِذَا قِيلَ لَكُمْ تَفَسَّحُوا فِي الْمَجَالِسِ فَافْسَحُوا يَفْسَحِ اللَّهُ لَكُمْ وَإِذَا
قِيلَ انشُزُوا فَانْشُزُوا يَرَفَعِ اللَّهُ الَّذِينَ آمَنُوا مِنْكُمْ وَالَّذِينَ أُوتُوا الْعِلْمَ دَرَجَاتٍ وَاللَّهُ بِمَا
تَعْمَلُونَ خَبِيرٌ ﴿١١﴾
المجادلة الايه ١١

٥- لا يصل لذروة الايمان المطلقة من بني آدم الا العلماء:
شَهِدَ اللَّهُ أَنَّهُ لَا إِلَهَ إِلَّا هُوَ وَالْمَلَائِكَةُ وَأُولُو الْعِلْمِ قَائِمًا بِالْقِسْطِ لَا إِلَهَ إِلَّا هُوَ الْعَزِيزُ
الْحَكِيمُ ﴿١٨﴾
آل عمران ١٨

٦- العلماء في الاسلام هم أشد الناس خشيةً لله سبحانه:
أَلَمْ تَرَ أَنَّ اللَّهَ أَنْزَلَ مِنَ السَّمَاءِ مَاءً فَأَخْرَجْنَا بِهِ ثَمَرَاتٍ مُخْتَلِفًا أَلْوَانُهَا وَمِنَ الْجِبَالِ جُدَدٌ
بَيضٌ وَحُمْرٌ مُخْتَلِفٌ أَلْوَانُهَا وَغَرَابِيبُ سُودٍ ﴿٢٧﴾ وَمِنَ النَّاسِ وَالدَّوَابِّ وَأَلْأَنْعَامِ
مُخْتَلِفٌ أَلْوَانُهُ كَذَلِكَ إِنَّمَا يَخْشَى اللَّهَ مِنْ عِبَادِهِ الْعُلَمَاءُ إِنَّ اللَّهَ عَزِيزٌ غَفُورٌ ﴿٢٨﴾
فاطر الايات ٢٧ - ٢٨

اللَّهُمَّ أَخْرِجْنَا مِنْ ظِلْمَاتِ الْجَهْلِ وَالْوَهْمِ إِلَى أَنْوَارِ الْمَعْرِفَةِ وَالْعِلْمِ

قال رسول الله صلى الله عليه وسلم

١- "مَنْ سَلَكَ طَرِيقًا يَلْتَمِسُ فِيهِ عِلْمًا ، سَهَّلَ اللَّهُ لَهُ طَرِيقًا إِلَى الْجَنَّةِ ، وَإِنَّ الْمَلَائِكَةَ لَتَضَعُ أَجْنِحَتَهَا لِطَالِبِ الْعِلْمِ رِضًا بِمَا يَصْنَعُ ، وَإِنَّ الْعَالِمَ لَيَسْتَغْفِرُ لَهُ مَنْ فِي السَّمَاوَاتِ وَ مَنْ فِي الْأَرْضِ ، حَتَّى الْحِيتَانِ فِي الْمَاءِ ، وَإِنَّ فَضْلَ الْعَالِمِ عَلَى الْعَابِدِ كَفَضْلِ الْقَمَرِ عَلَى سَائِرِ الْكَوَاكِبِ ، وَإِنَّ الْعُلَمَاءَ هُمْ وَرَثَةُ الْأَنْبِيَاءِ ، وَإِنَّ الْأَنْبِيَاءَ لَمْ يُورَثُوا دِينَارًا وَلَا دِرْهَمًا ، إِنَّمَا وَرَثُوا الْعِلْمَ ، فَمَنْ أَخَذَهُ أَخَذَ بِحِطِّ وَافِرٍ."

٢- " مَنْ خَرَجَ فِي طَلَبِ الْعِلْمِ فَهُوَ فِي سَبِيلِ اللَّهِ حَتَّى يَرْجِعَ "

٣- " إِذَا مَاتَ الْإِنْسَانُ انْقَطَعَ عَنْهُ عَمَلُهُ إِلَّا مِنْ ثَلَاثَةٍ : صَدَقَةٍ جَارِيَةٍ ، أَوْ عِلْمٍ يُنْتَفَعُ بِهِ ، أَوْ وَلَدٍ صَالِحٍ يَدْعُو لَهُ "

٤- " لَا حَسَدَ إِلَّا فِي اثْنَتَيْنِ: رَجُلٍ آتَاهُ اللَّهُ مَالًا فَاسْلَطَهُ عَلَى هَلَكْتِهِ فِي الْحَقِّ، وَرَجُلٍ آتَاهُ اللَّهُ حِكْمَةً فَهُوَ يَقْضِي بِهَا وَيُعَلِّمُهَا "

٥- "إِنَّ اللَّهَ وَمَلَائِكَتَهُ وَأَهْلَ السَّمَوَاتِ وَالْأَرْضِ حَتَّى النَّمْلَةُ فِي جُحْرِهَا وَحَتَّى الْحُوتَ لَيُصَلُّونَ عَلَى مُعَلِّمِ النَّاسِ الْخَيْرِ "

Basic Clinical Urology

Egypt 2015
